



Baština Akademije nauka i umjetnosti Bosne i Hercegovine

Perspectives in Paediatric Cardiology: Perspektive u pedjatrijskoj kardiologiji

Mesihović Dinarević, Senka

2012

Akademija nauka i umjetnosti Bosne i Hercegovine

<https://bastina.anubih.ba/items/ff7d5ad2-af81-4f1b-8490-552285003fe6>

Preuzeto s Baštine Akademije nauka i umjetnosti Bosne i Hercegovine

<https://bastina.anubih.ba/>

PAEDIATRIC AGE DILATED CARDIOMYOPATHY (DCM): REPORT ON A FEW CASES

*C. Olteanu¹, G. Privitera, C. Persico, B. Sartori,
C. Flori, R. La Fata, M. Falbo, E. Pedretti*

¹Ospedale “Grigore Alexandrescu” Bucarest Romania
UO Pediatria Fiorenzuola (Piacenza) Italia

Abstract

Dilated Cardiomyopathy in the paediatric patient is a serious condition that asks much of the physician and stresses the family. (1)

We present the following 10 cases for whom, once the precise aetiology and ensuing appropriate therapeutic regimen had been established, conditions improved.

It is of fundamental importance to extensively research all underlying causes for reduced contractility while avoiding the temptation of the panacea of transplant surgery.

INTRODUCTION

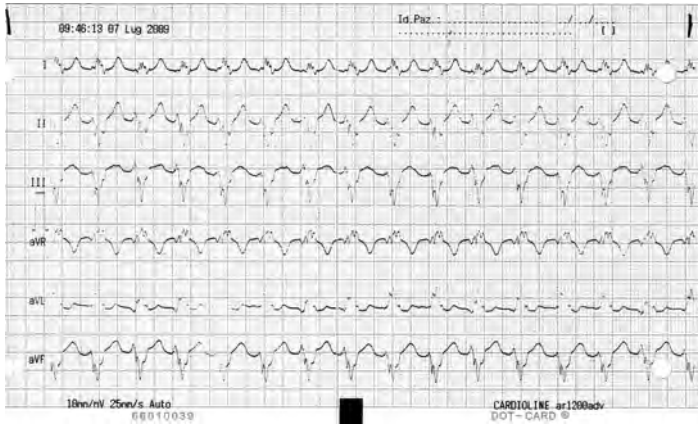
Dilated Cardiomyopathy in the paediatric patient is a life-threatening condition that has a huge impact on the family unit and often poses difficult diagnostic problems with difficult therapeutic and prognostic implications.

All causes of reduced contractility should be evaluated in order to establish the appropriate ensuing therapy.

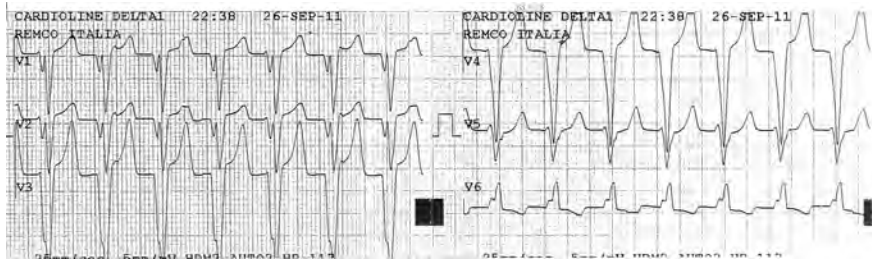
CASES REPORT

Ten cases that evolved favourably (condition reverting to complete normality or bettering of conditions) 4 of the cases, following complete evaluation, were classified as tachycardiomyopathy. (2-3-4)

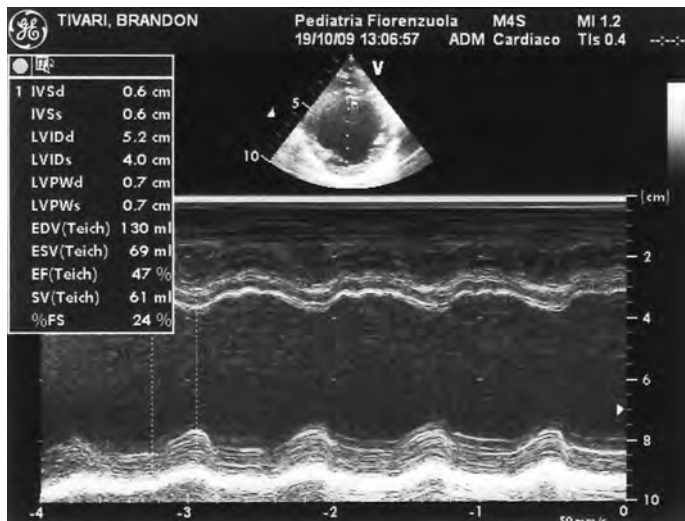
A 5 year old boy who presented incessant ventricular tachycardia (170 bpm) associated with an EF of 10% attained normal contractility following medication and 2 radiofrequency ablations for an ectopic ventricular focus of the right ventricle.



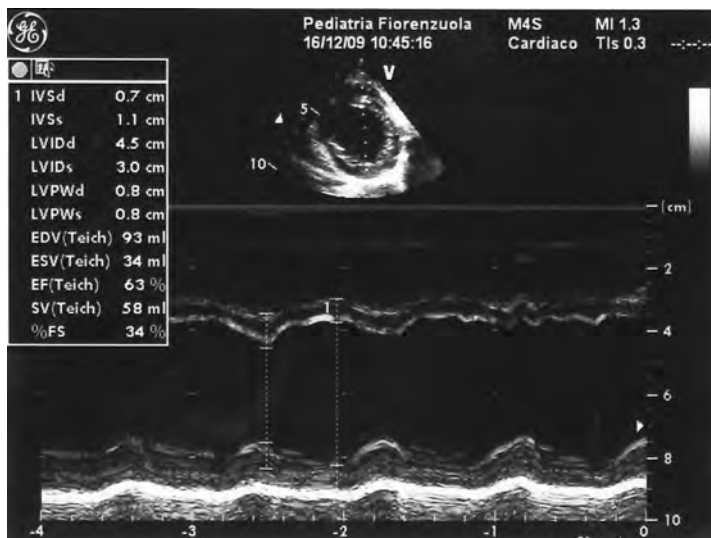
130 bpm ventricular tachycardia



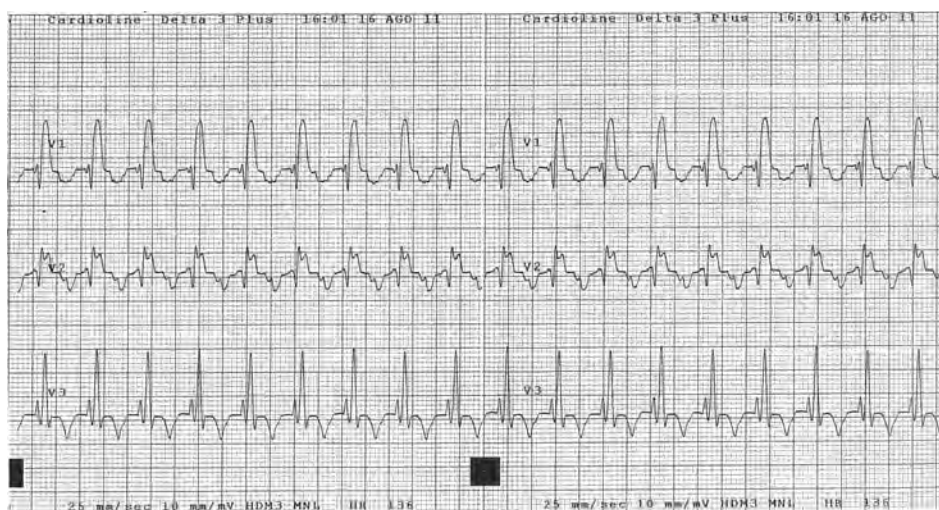
Focus in the right ventricle



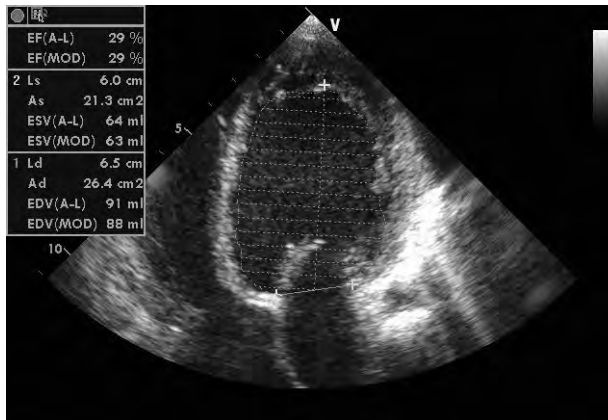
Reduced contractility



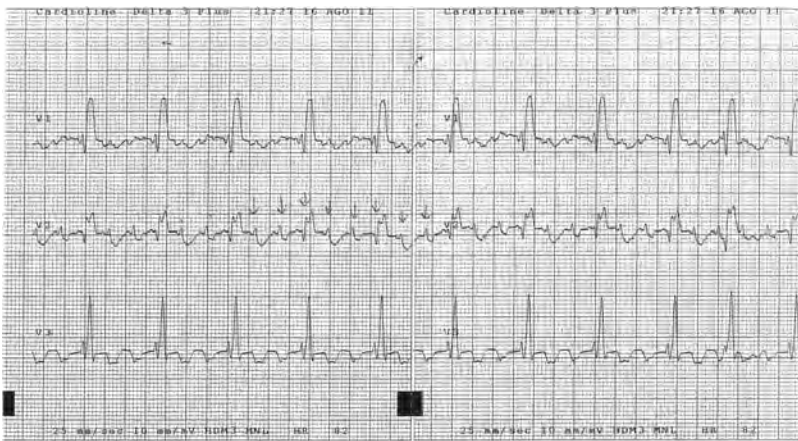
Another 5 year old boy who had previously received surgery for Fallot's tetralogy presenting with an EF of 20% and incessant tachycardia (140 bpm) and for whom transplant had already been suggested elsewhere, received radiofrequency ablation after diagnosis of atrial flutter; ensuing contractility is normal.



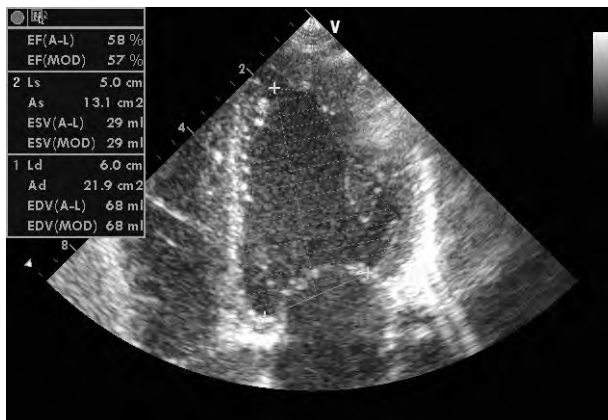
140 bpm fixed rate supraventricular tachycardia



Reduced contractility

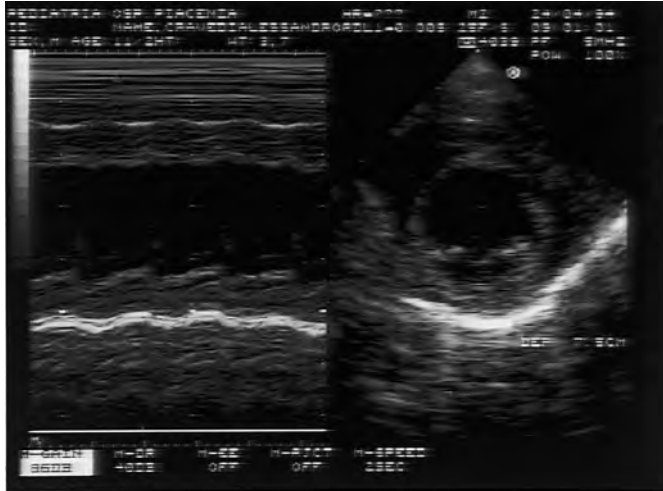


Flutter diagnosis

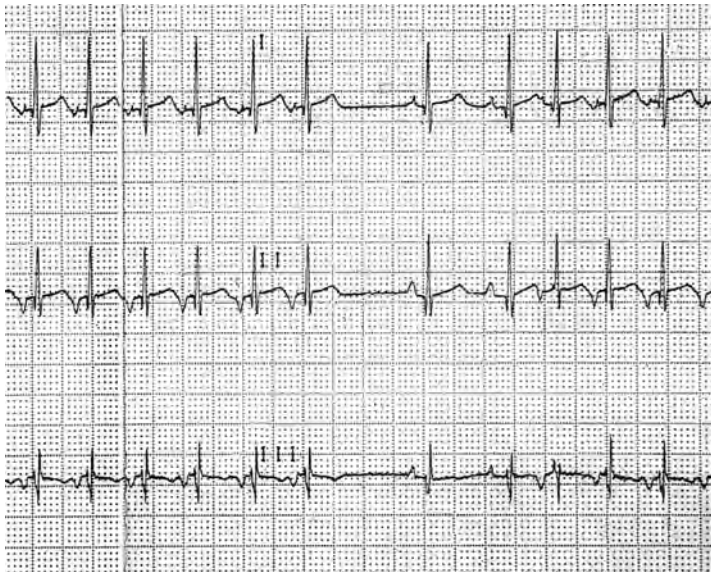


Normal contractility

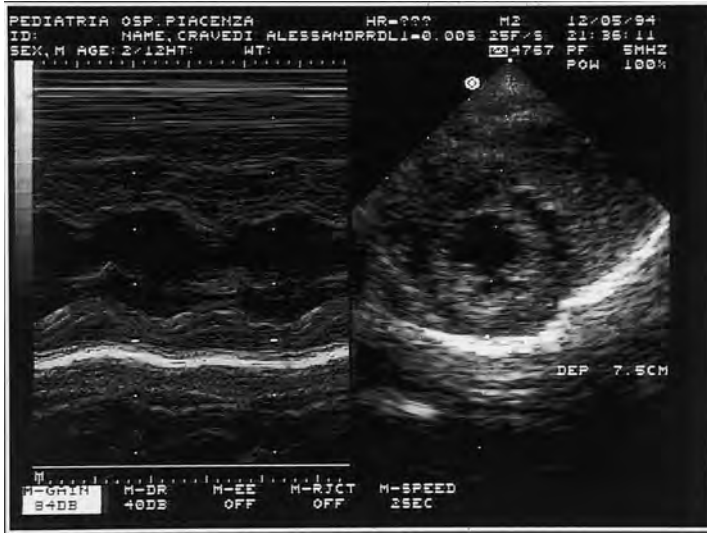
A 30 day old newborn with polypnea, cyanosis and restlessness was admitted to hospital and found to have PJRT - Coumel type supraventricular tachycardia (250 bpm) with an EF of 25%: on the tenth day of medication contractility was normal and sinus rhythm was achieved.



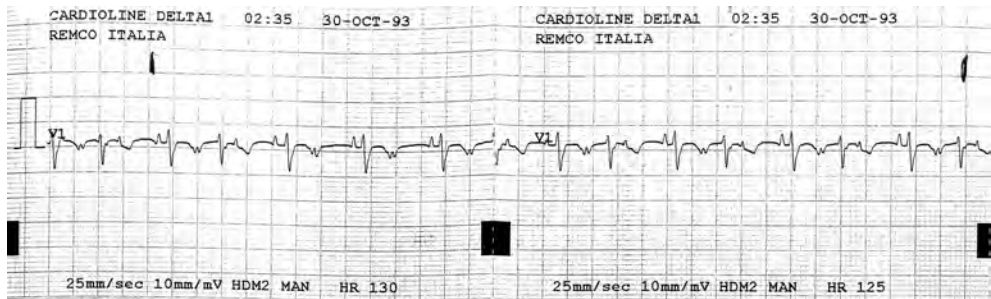
Reduced contractility



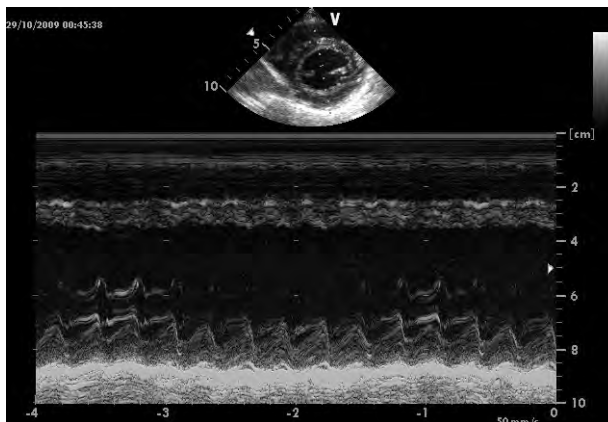
PJRT



Normal contractility

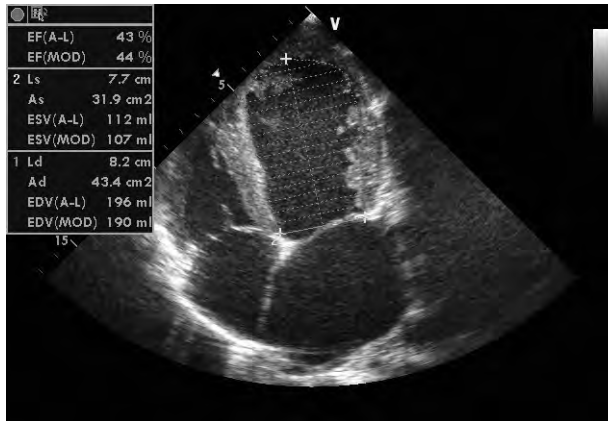


140 bpm atrial tachycardia

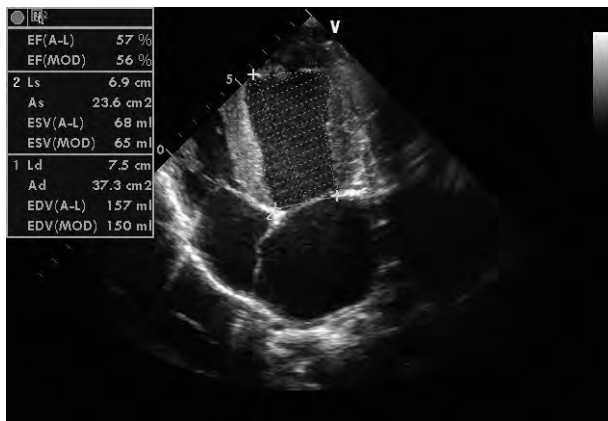


Reduced contractility

A 12 year old who now presents EF of 50%: viral myocarditis at the age of 5 was treated with medical therapy.



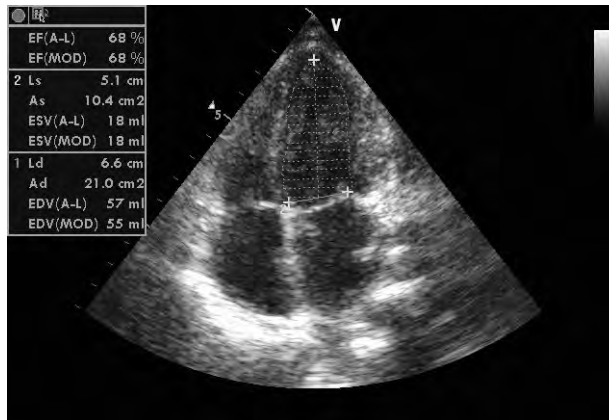
Reduced contractility



Normal contractility

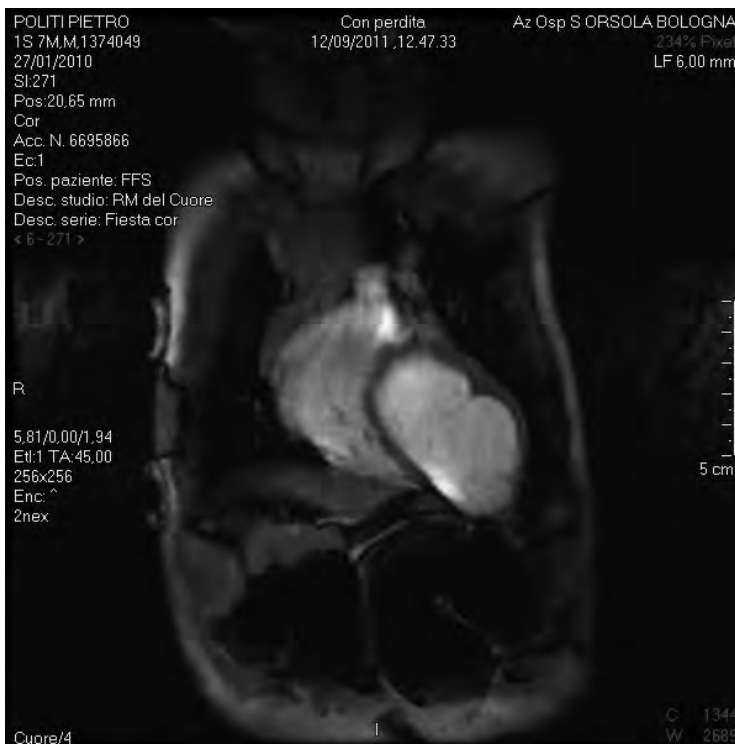A 6 year old girl who was admitted to hospital with dyspnoea, asthenia and muscle pains was found to have an EF of 45% and extremely low plasma levels of Carnithine: 0,7 micromoli/l (V.N. 21,7– 47,3).

Contractility normalized following administration of L- Carnithine at the dose of 150 mg/Kg/die. (6, 7, 8, 9)

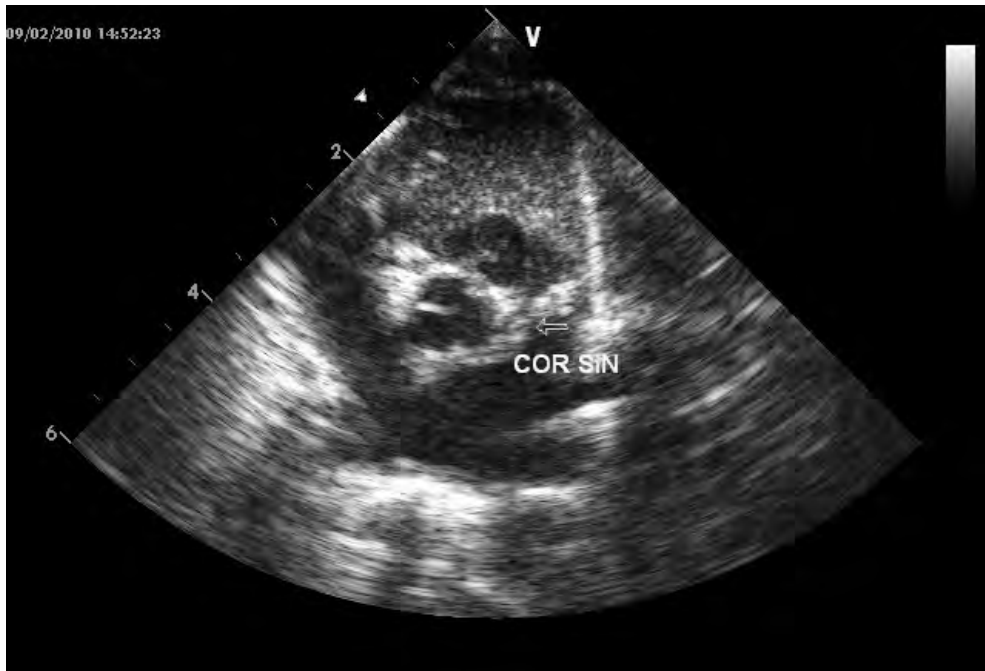


Normal contractility

A 2 year old who is currently asymptomatic was diagnosed, in utero, as having a dilation of the apex of the left ventricle: MR shows partial agenesis of the pericardium and aneurismal thinning of the myocardium.

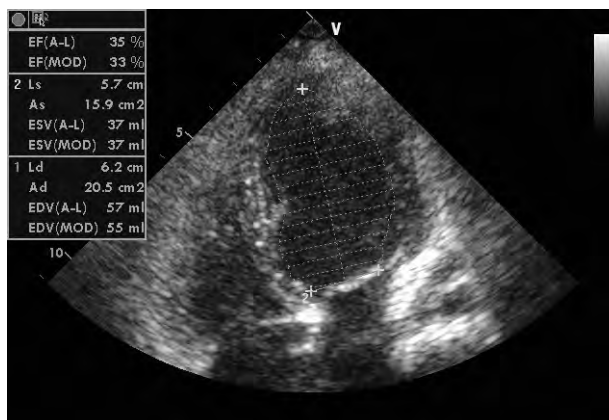


Dilation of the apex of the left ventricle with partial agenesis of the pericardium

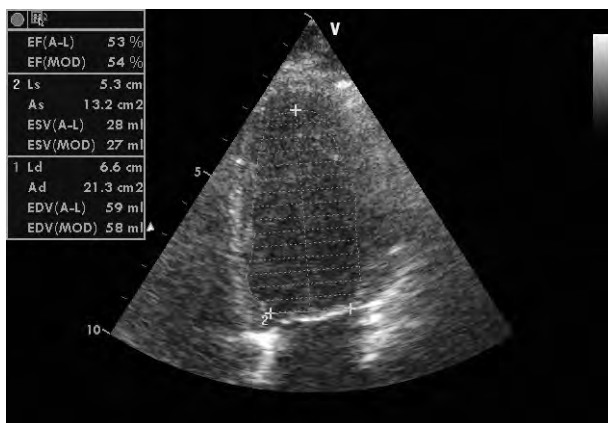


Normal origin of the left coronary artery

A 7 year old boy, with Fallot's disease, underwent two separate surgical procedures: the first operation of radical correction using a trans-annular patch required readmission to surgery following detachment of the inter-ventricular patch. Subsequently ventricular dysfunction and an EF of 20% posed indication for a transplant. He is now on medication and EF is up to 55%.



Reduced contractility



Normal contractility

2 newborns, diagnosed as having ALCAPA after presenting with life-threatening reduction of left ventricle EF, both required emergency surgery.

They are now 5 and 6 years old respectively and both have normal contractility.

DISCUSSION

“Tachycardiomyopathy is an abnormality of systolic or diastolic function of the heart, or both, usually resulting in heart dilatation and ultimately in heart failure caused by a high and/or irregular ventricular rate. This high and/or irregular ventricular rate may result from any type of cardiac arrhythmia.” (Brugada P., Andries E.)

Tachycardiomyopathy and reduced contractility are two intertwining aspects that make diagnosis of the primary cause particularly difficult.

If contractility is ameliorated by reducing heart rate the correct diagnosis is Tachycardiomyopathy. One must bear in mind, however, that if tachycardia has been of long duration or of high frequency contractility it may, in these cases, be only partly ameliorated by reducing heart rate.

Tachycardia-induced damage to the myocardium determined reduced number of beta-receptors, reduced blood-flow in the coronary arteries, most notably in the sub-endocardium, and alteration of Na⁺ and Ca⁺⁺ channels that can determine lengthening of repolarisation time and further arrhythmias.

Incessant tachycardia is often paucisymptomatic and drug-resistant; these are cases where transcatheter ablation play an important role.

Pericardial agenesis is a rare malformation (1 case in 10000 – 14000) and is often asymptomatic and underdiagnosed. (10, 11, 12)

It can be partial or complete. In the complete variant the heart is shifted to the left and interposition of lung tissue between heart and diaphragm is found.

The partial variant is more often symptomatic: stress related dyspnoea, precordialgia, ischemia, syncope and sudden death.

It is currently believed that symptoms are due to compression of the coronary arteries arising from the edge of the “hole” in the pericardium.

Another hypothesis is that the deviation of the heart to the left determines angling of the large blood vessels and distortion of the coronary arteries.

Right cavities are falsely enlarged at ultrasound inspection.

Suspicion levels for ALCAPA must be kept high in cases of neonates with important myocardial hypokinesia and in older children with otherwise unexplained severe mitral insufficiency. (13, 14, 15, 16, 17)

CONCLUSIONS

Life-threatening reduction of EF must not impede extensive research into the cause of cardiomyopathy in every single case as the precise diagnosis and ensuing correct choice of therapy can achieve normalization of cardiac function.

References

1. Timothy M. Olson, MD, Timothy M. Hoffman, MD, David P. Chan, MD. Dilated congestive cardiomyopathy. In Moss and Adams' Heart disease in infants, children, and adolescents, Seventh edition. Eds: Hugh d. Allen, MD, ScD(Hon), David J. Driscoll, MD, Robert E. Shaddy, MD, Timothy F. Feltes, MD, Lippincott Williams & Wilkins, 2008, 1195–1207.
2. Hassan A. Mohamed Tachycardia-induced Cardiomyopathy (Tachycardiomyopathy) *Libyan J Med* 2007; 2(1): 26–29.
3. Yuji Nakazato Tachycardiomyopathy *Indian Pacing Electrophysiol.J.* 2002; 2(4):104–113
4. Brugada P, Andries E. Tachycardiomyopathy. The most frequently unrecognized cause of heart failure? *Acta Cardiologica* 1993;2:165–169
5. Freixa X et al. Characterization of focal right atrial appendage tachycardia *Europace* 2008 Jan;(1): 105–9 10
6. Stanley CA. Carnitine deficiency disorders in children. *Ann N Y Acad Sci.* 2004 Nov;1033:42–51.
7. Wang SM, Hou JW, Lin JL. A retrospective epidemiological and etiological study of metabolic disorders in children with cardiomyopathies. *Acta Pediatr Taiwan* 2006 Mar-Apr; 47(2): 83–7.
8. Gesuete V, Ragni L, Picchio FM. The “big heart” of carnitine. *G. Ital Cardiol(Rome).* 2010 Sep; 11(9):703–5.
9. OMIM® - Online Mendelian Inheritance in Man®. Johns Hopkins University
10. Garnier F et al. Congenital complete absence of the left pericardium: a rare cause of chest pain or pseudo-right heart overload. *Clin Cardiol.* 2010 Feb;33(2): E 52–7

11. Razdan R. et al. Congenital complete absence of the pericardium mimicking myocardial infarction: a case report and literature review. *Conn Med* 2009 Nov–Dec; 73(10): 585–8
12. Ventura F. et al. Sudden cardiac death in a case of undiagnosed pericardial agenesis. *Rev Esp Cardiol*. 2010 Sep; 63(9): 1103–5
13. G. Paul Matherne, MD, D. Scott Lim, MD. Congenital anomalies of the coronary vessels and the aortic root. In Moss and Adams' *Heart disease in infants, children, and adolescents*, Seventh edition. Eds: Hugh d. Allen, MD, ScD(Hon), David J. Driscoll, MD, Robert E. Shaddy, MD, Timothy F. Feltes, MD, Lippincott Williams & Wilkins, 2008, 703–715.
14. L. Grosse-Wortmann, T. Wenzel, H. H. Hevels-Guerich. Anomalous origin of the left coronary artery from the pulmonary artery in a premature infant with preserved left ventricular function. *Pediatr Cardiol* 27: 269–271, 2006.
15. Robert A Crowles, Walter E Berdon. Bland-White-Garland Syndrome of anomalous left coronary artery arising from the pulmonary artery: a historical review. *Pediatr Radiol* 2007 37: 890–895.
16. Claire Irving, Christopher Wren. Asymptomatic anomalous origin of the left coronary artery from the pulmonary artery. *Pediatr cardiol* 2009 30: 385–386.
17. V. T. Tsang, J. Stark. Congenital coronary artery fistula and anomalous origin of the left coronary artery from the pulmonary artery. In *Surgery for congenital heart defects*, third edition. Eds: Jaroslav F. Stark, Marc R. de Leval, Victor T. Tsang, Wiley, 2006, 612–617.