Baština Akademije nauka i umjetnosti Bosne i Hercegovine

Perspectives in Paediatric Cardiology: Perspektive u pedjatrijskoj kardiologiji

Mesihović Dinarević, Senka

2012

Akademija nauka i umjetnosti Bosne i Hercegovine

https://bastina.anubih.ba/items/ff7d5ad2-af81-4f1b-8490-552285003fe6

Preuzeto s Baštine Akademije nauka i umjetnosti Bosne i Hercegovine

https://bastina.anubih.ba/

ECHOCARDIOGRAPHY ASSESSMENT OF SYSTOLIC FUNCTION IN DIFFERENT LEFT VENTRICULAR GEOMETRIES

Ida Jovanovic[1,2], *Tamara Ilisic*[1,2], *Milan Djukic*[1,2], *Vojislav Parezanovic*[1,2], *Jasna Kalanj*[1,2], *Irena Vulicevic*[1,2], *Milica Bajcetic*[1,2], *Goran Cuturilo*[1,2]

[1]Faculty of Medicine, University of Belgrade, Serbia
[2]University Children's Hospital, Serbia

Abstract

Congenital heart diseases (CHD) appear as a large variety of anomalies with different ventricular shapes, sizes and haemodynamics. Reliable assessment of ventricular function in children with complex CHD, such as univentricular heart or after a Fontan operation, is difficult, as the majority of echocardiographic (ECHO) parameters rely on geometric assumptions or haemodynamic factors.

A number of new echo methodologies, like Tissue Doppler Imaging (TDI), strain and strain rate have become available, allowing an assessment of different aspects of left ventricular (LV) contraction. In particular, evaluation of LV longitudinal systolic dynamics has progressively gained importance as a key aspect in the assessment of LV systolic function. Longitudinal measures of wall function are: annular displacement and velocity, the displacement index, myocardial performance index (MPI), as well as mean strain/strain rate.

Annular displacement, determined from M-mod, is a direct, early, sensitive, and easy-to-perform index of global LV systolic function, but is age-dependent. TDI is a quantitative non-geometric measure of systolic and diastolic ventricular function. The most commonly used indices are mitral annular systolic peak S-wave velocity (S') and MPI. The new parameter is displacement index (S'-wave velocity-time integral, divided by the end-diastolic distance from the mitral annulus to the LV apex), very sensitive, not affected by age, heart rate, or BSA.

Conclusions: Reliable assessment of systolic ventricular function in patients with complex CHD is possible through detailed study of LV long-axis dynamics. Most importantly, new, specific TDI indices provide evidence of subtle cardiac dysfunction long before clinical or traditional ECHO signs are appreciable.

Keywords: Congenital heart disease, Ventricular function, Echocardiography

Introduction

Reliable non-invasive assessment of left ventricular (LV) function is essential for the diagnosis and management of heart failure. Echocardiography is currently the technique most widely used for this purpose although cardiac magnetic resonance imaging (CMR) is becoming the reference method, but it is reserved only for a small number of selected patients [1–4]. The assessment of heart function is an indication for ECHO examination in about 60% of adult cardiac patients. In paediatric cardiology, the pathology is completely different, predominantly related to congenital heart diseases (CHD). The congenital malformations are a result of a huge number of genetic abnormalities and thus appear as a large variety of CHDs with different ventricular shapes, sizes and haemodynamic. Most of them involve an important component of volume and/or pressure load, which produces variable degrees of remodelling and adaptation for different loading conditions. Paediatric patients who require close surveillance of myocardial function can range from neonate after arterial switch or Norwood palliative reconstructive surgery, to children with different CHD (pre or post surgery), or an adolescent patient with dilated cardiomyopathy. Particular diagnostic problems appear for patients with systemic right ventricle (RV), single ventricle physiology or univentricular heart (UVH) corrected by Fontan procedure. Finding a common methodology for ECHO evaluation of ventricular function in hearts with completely different ventricular geometry, contraction, and regional wall motion abnormalities remains challenging, as the majority of techniques aimed at the assessment of heart function are developed for biventricular heart and for the LV. Furthermore, many of these patients have limited echocardiographic windows, and inadequate visualization of the endocardial border at end-systole and end-diastole [5]. Complementary diagnostic methods, like measurement of neurohormonal markers, such as brain-type natriuretic peptide (BNP) and N-terminal (NT)-pro BNP, have been increasingly used for children with cardiomyopathies, but also for various congenital anomalies [6, 7]. Unfortunately, several studies for single ventricle anomalies prove that levels of neurohumoral markers are variable and, therefore, this method is not recommended in this group of patients [8–10].

Background

The performance of the ventricle as a pump mostly depends on several components: primarily contraction of the myofibrils/sarcomers (contractility), then ventricular geometry, loading conditions, and heart rate. When we refer to ventricular systolic function, one should be aware of the difference between contractility (the intrinsic property of the myocardium) and ventricular pump function (ventricular performance). During the systole, the main event is force development which, at the myocardial level, results in the production of biventricular pressure as a result of fibre shortening, heart deformation and blood ejection. In clinical practice, ventricular systolic function usually denotes ventricular pump function, which is a global parameter (global function). In some diseases, the contribution of different myocardial

regions to the ventricular pump function can be altered and, in those cases, the analysis of individual wall segments is important – regional myocardial function.

The heart has a unique, three dimensional (3D) architecture, with specific complex fibre orientation [11]. Myofibers at epicardium have predominantly longitudinal (left-hand) orientation, then gradually change direction, to circumferential orientation, in the middle part of the wall before changing direction again in the endocardial (inner portion) of the wall to long-axis (right-hand) orientation. Because of such spiral fibres' orientation during systole, when myofibers shorten, they simultaneously thicken and twist, compressing each other in three directions, thus producing an effect of amplification of all those deformations through a squeezing effect on neighbouring fibres. As a result of this, we see an effect in a healthy heart that, during systole sarcomeres shortening of about 15%, results in 35–40% thickening, and the ejection of about 60–70% of blood volume [12]. In summary, during systole, ventricular walls move in longitudinal, circumferential and transmural (radial) directions, with the following deformations: longitudinal shortening, circumferential shortening and, as a consequence, transmural thickening.

This article is dedicated to the evaluation of global systolic function of the systemic ventricle.

Standard methods for evaluation of LV systolic function

Over the last 3 decades, a large number of ECHO parameters for the evaluation of LV systolic function were published. Most of them are too complex for everyday clinical practice, and only have scientific value, as they are time consuming. Traditional ECHO measures of LV systolic function include: M-mode, two dimensional (2D) examinations for dimensions and derived volume changes, and Doppler-derived ejection indices for ventricular performance. Most ECHO measures of LV systolic function represent ejection phase indices, such as: fractional shortening (FS) and ejection fraction (EF) (dimensional parameters from M-mode or 2D), or velocity of circumferential fibre shortening (Vcf), changes in peak and mean pressure over time ($\Delta p/\Delta t$) (Doppler parameters) and systolic time intervals.

Ejection fraction and fractional shortening

Ejection fraction and FS are still the most widely used measures of global systolic LV function today. Fractional shortening is more commonly used in children and its normal values range between 28 – 44%, with variations for age. EF is the most commonly used parameter in adults, mainly due to the large amount of prognostic information that is included in the cut-off points of EF values [13–15]. Normal values range from 56–78%. This is a single parameter with good perception of its value amongst cardiologists as well as surgeons; thus, it will remain in use in the foreseeable future.

Fractional shortening and EF calculation from LV linear measurements by early-used Teichholz or Quinones formulas, both based on geometrical assumptions, are no longer recommended; however, using 2D echocardiography with modified Simpson's rule with biplane planimetry of LV is currently recommended [16]. In everyday clinical practice the "eyeball" estimation of EF is often performed and experienced physicians get results comparable to those obtained using "trackball" methods [17]. Whichever method for measuring EF is applied to assess global LV systolic function carries important limitations due to its dependence on instantaneous loading conditions, picture quality, suboptimal test-retest reproducibility, and low sensitivity in detecting subtle LV systolic impairment [18]. The majority of new methods still compare their results with EF, as if it were the "gold standard" [19]. There is, however, one important limitation of EF, which is the reason why EF cannot be used in all patients! The EF was primarily introduced in order to characterize the reduced myocardial function in dilated LV, but becomes erroneous in the cases of reduced end diastolic volume (EDV), as well as severe myocardial hypertrophy [20]. A perfect example of this can be seen in those patients with clinical signs of heart failure and small, hypertrophic hearts, known widely as "heart failure with preserved EF (HFPEF)". Today, it is clear that the systolic and diastolic functions are closely related, since a significant part of the diastolic recoil is due to stored elastic energy from previous systolic contraction. It is important to stress that EF should not be used in smaller ventricles, as systematic errors are introduced [20].

Recently, more complex, slow, but accurate methods are becoming available to determine cardiac volumes and EF (e.g. CMR, 3D echocardiography), applicable especially to unusual ventricular geometries, but not in routine clinical practice [3, 21, 22]. There are few acquisition or analysis methods in 3D ECHO and none of them rely on geometric assumptions for volume/mass calculations, since the real geometry is captured by 3D imaging. As a result, none of the 3D methods have plane positioning errors, which can lead to chamber foreshortening [23, 24]. Studies comparing 3D ECHO LV volumes or mass measuring with the CMR, as the current gold standard, have confirmed 3D echocardiography to be accurate. Compared with CMR data, LV and RV volumes calculated from 3D echocardiography showed significantly better correlation and lower intra-observer and inter-observer variability than 2D echocardiography [16].

New methods for evaluation of LV systolic function

Newer ECHO techniques**,** such as TDI, 3D echocardiography, and deformation imaging allowed better understanding and evaluation of the complex mechanism of cardiac contraction and relaxation. Evaluation of LV longitudinal systolic dynamics has become crucial in the assessment of LV systolic function [18]. The idea of analyzing longitudinal motions of AV annulus as well as ventricular walls is based on the contribution of Leonardo da Vinci to cardiology. He anticipated that the heart functions as a double pump, with the atrioventricular plane as a piston, [25] and

later anatomical studies about myocardial fibre orientation in the heart [11]. Since 1990, functional importance of the long-axis dynamics of the left ventricle and the possibility of analyzing it by ECHO has been recognized, [26] and many published studies proved its superior value in comparison with traditional measures [27, 28].

The passive annular movements reflect the longitudinal systolic shortening of the ventricle, which, in a way, represents the global systolic longitudinal function. Annular displacement and velocity are good measurements of total ventricular shortening and shortening velocity (to assess global ventricular function) [20].

Currently, LV long-axis performance can be evaluated using the following techniques: 1. M-mode; 2. pulsed TDI; 3. colour TD-derived techniques (i.e. tissue velocity imaging, strain (S) and strain rate (SR) imaging, and 4. two-dimensional SR imaging.

M-mode indices

Mitral annular excursion

Determination of mitral annular apical systolic excursion (MAE) is possible using 2D-guided M-mode imaging of mitral annular motion from apical views. This is the easiest method of assessing LV global long-axis systolic performance. Variations in excursion across the annulus circumference require that, for precise MAE estimation, evaluation should be performed by averaging measurements obtained in multiple annular sites (usually 4 or 6) [29]. Measurements are usually performed from apical 4-chamber view at the septal and/or lateral annulus level, using zoom function at the level of the annulus (Figure 1) [30].

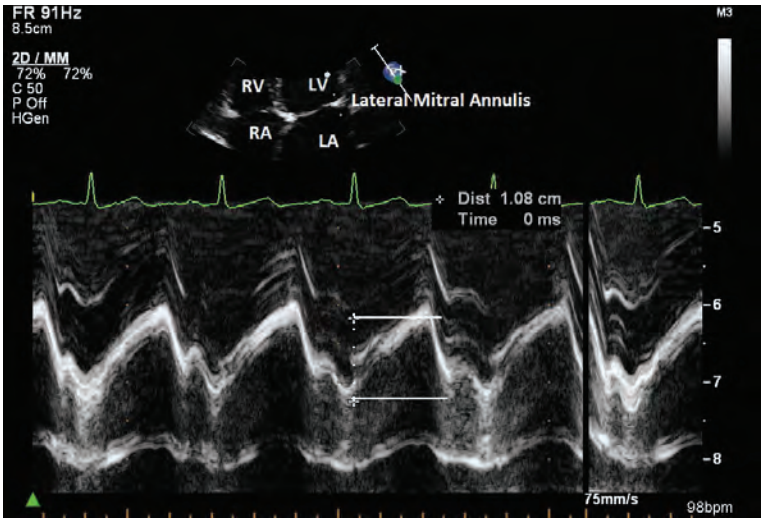

Figure 1. Recording of the motions of lateral mitral annulus by two dimensionally guided M mode, using zoom function. The vertical distance between the point of the annular most distant from the apex and the point closest to the apex is measured in M mode, as indicated.

A study of Emilson K et al. proved that MAE is dependent on the age and size of patient. The normal mean MAE in healthy adults ranges from 14 to 15 mm. These values are regularly higher in younger subjects, and have been reported to decline from 15 mm at 20–40 years, to approximately 10 mm at 61–80 years [31]. Practically, this means that the annular displacement should be normalized for heart size in children [19, 32].

Very good correlation was found between MAE and EF for adults. The value of 12 mm was selected as a cut-off point for MAE for detection of LVEF <50%, regardless of whether MAE was determined by M-mode, 3D echocardiography, or MRI [33, 34].

Additionally, MAE provides good prognostic information in heart failure patients. For example, in patients with myocardial infarction, with a threefold relative increase in the risk of mortality in patients with MAE<8 mm compared to those with MAE >8 mm over a two-year follow-up [35]. A similar study of Cline et al. [36] showed that mortality increased significantly if MAE was less than 6 mm (all patients died within one year).

A depression in MAE can evidence subtle systolic impairment in nearly one quarter of patients with: HFPEF, arterial hypertension and aortic stenosis with preserved EF [37-39].

For a majority of patients, echocardiographic determination of MAE is fast and easy and at the same time highly reproducible and sensitive index of global LV systolic function [18].

Pulsed tissue Doppler indices

Heart pump function significantly depends on the myocardial wall function, and changing the focus of diagnostics to the myocardium instead of cavity dimensions leads to a new quality in diagnostics. Doppler myocardial velocity measurement by TDI was introduced as a more objective, direct and quantitative method for assessing myocardial function, with the possibility to analyze regional contribution. From a practical point of view, measurements of longitudinal systolic and diastolic components give the best results, due to heart motion. The complexity of understanding TDI delays its implementation in clinical routine but, today, it should be considered a part of routine examination [40].

Peak annular velocity

Pulsed TDI is a technique that allows the recording of instantaneous maximal velocities within a predefined volume sampling region in real-time. By selecting a single sample volume in TDI, high temporal resolution is achieved. Among all the parameters that could be measured, peak annular velocity-Sm is the most commonly used for estimating the global LV long-axis systolic function. Recording should be

performed from apical views, by placing a sample volume at the junction between basal myocardium and mitral annulus. To improve the reliability of the systolic annular dynamics estimation, since inhomogeneity of velocities across annular circumference exists, values recorded in at least two different levels of the annulus (e.g., septal and lateral) should be averaged [18]. This parameter mostly depends on age and heart rate. Age-specific reference ranges for Sm were published [41]. Eidem et al. [42] analyzed the impact of growth on TD velocities during childhood. This study demonstrated that measures of cardiac growth, most notably LV end diastolic dimension and LV mass, had significant correlation with TD systolic and early diastolic velocities, particularly for neonates and infants. In the same paper [42] it was proven that HR has significant influence on tissue velocities. According to this study, normal values of mitral valve maximal systolic velocities (Sm) at the lateral mitral annulus (and basal septum) are presented at Table 1 [42]. Another large study from Roberson et al. [43] confirmed correlations of maximal TD annular velocity with age, body surface area (BSA) and heart rate (HR). Variations in Sm value between healthy children of different age and HR were much greater than in most prior studies. The principal contribution of this research is the development of *Z*-score tables from a large number of patients covering all ages, HR, and BSA. These tables serve as reference data for longitudinal-directed TD annular and septal Sm, as well as for diastolic parameter (E' and A') normal values in children [43].

Table 1. Normal values of mitral valve maximal systolic velocities (Sm) [42].

Age / Velocity (cm/s)	Less than 1 year	1 – 5 years	6 – 9 years	10 – 13 years	14 – 18 years
Lateral mitral annulus	5.7 ± 1.6	7.7 ± 2.1	9.5 ± 2.1	10.8 ± 2.9	12.3 ± 2.9
Basal septum	5.4 ± 1.2	7.1 ± 1.5	8.0 ± 1.3	8.2 ± 1.3	9.0 ± 1.5

Extensive debate regarding the influence of volume and pressure loading on tissue velocities has taken place. Initially, the prevailing opinion was that tissue velocities were relatively independent, an opinion that was later partially denied. Conflicting results still exist, but it seems that for the same preload, there is a difference in tissue velocities between acute and chronic types of disease [44]. Chronic volume overload [45] has a smaller effect on tissue velocities than the acute variety [46]. Pressure loading influences tissue velocities in the following way: increased ventricular pressure (acute or chronic, like in aortic stenosis), leads to decreased tissue velocities [47]. Kiraly et al. [48] showed that in children with aortic valve stenosis, longitudinal TD velocities were more reduced than TD radial velocities.

In patients suffering from CHD the RV is commonly affected by volume and/or pressure overload or by surgery. Tissue velocities have a great potential for assessment of RV function because the RV has predominantly longitudinal orientation

of myofibres. There are several studies of longitudinal RV function in tetralogy of Fallot (TOF), showing the usefulness of TDI in early recognition of RV, as well as LV dysfunction [59, 51].

The use of TD velocities in functionally univentricular hearts has also been studied. Vitarelli et al. [52] studied 24 patients who had undergone Fontan surgery and found a linear correlation between Sm and echocardiographic estimates of EF. In the large study undertaken by Rhodes et al., [53] performed on 416 Fontan patients, statistically significant correlations existed between Sm, Tei index, and echocardiography-based estimates of EF, but these correlations were weaker than the correlation between traditionally-calculated EF and new, more sophisticated parameters, as well as CMR-derived EF.

Mitral annular displacement index

Recently, a new and promising parameter of longitudinal ventricular systolic function was introduced by Roberson et al. [19], entitled Mitral Annular Displacement Index (MADI). This is a TD annular systolic (Sm) wave velocity time integral (VTI) divided by the end-diastolic distance from the mitral annulus to the LV apex. It is, in fact, the measure of relative change in longitudinal ventricular length during systole found through Doppler measurements (Figure 2). Doppler measurements are more precise than distance measurements and less observer-dependent if the beam direction is correct, wherein lies the reason as to why this method is promising.

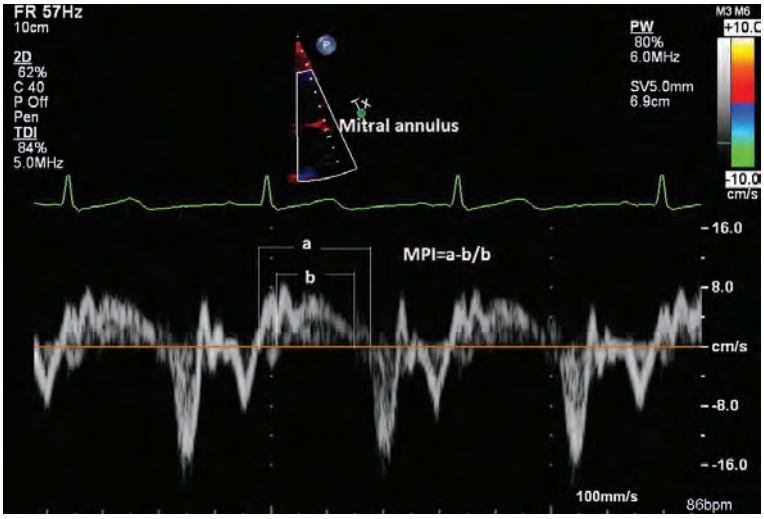

Figure 2. Left ventricular Myocardial Performance Index (MPI) calculation from mitral annulus tissue Doppler recording. The a component (isovolumic contraction time + ejection time + isovolumic relaxation time). The b component is ejection time. MPI=a-b/b

In the study of Roberson et al., [19] 80 children (age-range from 21 days to 18 years) were analyzed, with 46 of them displaying normal systolic function (EF>55%). The

normal values in this study population were displacement index 26 ±4%, with cut-off values of MADI less than 22% for myocardial dysfunction. Displacement index is not affected by age, HR, or BSA and, therefore, z-score tables or regression equation adjustments are not required. MADI also has low observer variability, is simple and rapid, and requires no complex computer analysis or special software. It can be obtained in the large majority of patients in our experience, and can be easily introduced in clinical practice [19]. MADI is similar to longitudinal LV mean Lagrangian strain and numeric values are similar as well.

Myocardial performance index

Myocardial performance index (MPI) is a measure of global myocardial performance, both systolic and diastolic. It was created by Tei et al. [53] with the idea of assessing overall cardiac function/dysfunction, bearing in mind that systolic and diastolic dysfunction frequently coexist and is widely known as a Tei Index. In fact, this is a parameter based on time intervals, used for a long time in the evaluation of myocardial function. MPI is the sum of the isovolumic relaxation time (IRT) and isovolumic contraction time (ICT) divided by ejection time (ET): MPI = (ICT+IRT)/ET. It can be determined by 3 different ECHO methods: M-mode, pulse wave Doppler (PWD) and TDI [45, 54-57]. For all 3 methods, one should measure two time intervals: the period from MV closure to the MV opening (*a* value), which equals the sum of isovolumic contraction time plus ejection time plus isovolumic relaxation time and ejection time interval (*b* value), and then calculate MPI as *a* -*b*/*b* (Figure 3).

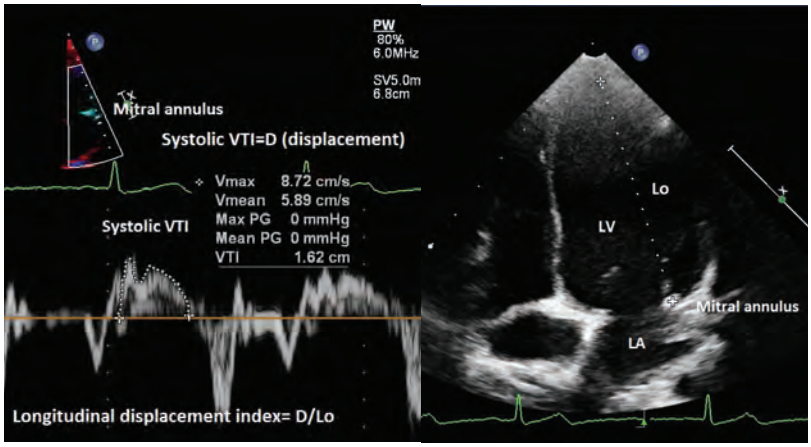

Figure 3. Method of measurement of longitudinal mitral annular systolic displacement index from mitral annulus TDI recording. LA-left atrium, LV-left ventricle, L0, distance from mitral valve annulus to LV apex at end-diastole; Systolic VTI-VTI of tissue Doppler systolic S wave.

Several studies were performed to determine the normal values of MPI in the paediatric population [42, 54–57]. Cui and Roberson [57] published normal values for

MPI in the paediatric population determined by all 3 methods and compared their result with other similar studies. There was no clinically significant dependence on age, heart rate, and BSA for paediatric patients. There were some differences between the LV MPI values for the 3 methods, as they in fact measure different time interval parameters for the *a* and *b* components of the MPI. The best method is the measuring of MPI by TDI, because it requires imaging in only one view; thus, *a* and *b* components are measured in the same cardiac cycle in all cases. Normal values of LVMPI determined by TDI ranged from 0.38±0.06 [57], to 0.42±0.09 [56]. Assuming the normal range for MPI is the mean ±2SD, the upper limit of normal for LV MPI should be considered as 0.50, determined by TDI or PWD, so the MPI value greater than 0.5 is a sign of global ventricular dysfunction [57].

MPI can be calculated for RV as well. The normal value of the RV MPI is 0.32 ±0.03 [58].

In patients with dilated cardiomyopathy, MPI is increased and has important prognostic value [59, 60].

For most patients with RV as a systemic ventricle, as with patients after Mustard repair for transposition of the great arteries, the RV is impaired. For many years these patients are asymptomatic or minimally symptomatic. MPI, NT-proBNP and VO2max are simple screening methods to assess patients with impaired cardiac dysfunction before they become symptomatic [61].

MPI has a particular value in the evaluation of heart function in patients with univentricular heart, pre or post surgery (Glenn or Fontan operation), and there appears to be a logical explanation for that fact. The majority of patients with this type of disease have a different degree and type of dysfunction – systolic and/or diastolic – and frequently have segmental wall motion abnormalities/dyskinesia. Over time their heart function usually deteriorates, but for a long time these patients are asymptomatic. There is a need for a sensitive and non-invasive method for assessment of their ventricular function. Additionally, many of these patients have a common technical limitation regarding the echocardiographic window, resulting in an inadequate visualization of the endocardial border. In routine clinical practice assessment of ventricular function is therefore subjective and semi-quantitative. In several studies related to ECHO evaluation of ventricular function of single ventricle it was found that MPI was increased. Williams et al. [62] found that MPI was significantly higher in patients with functionally single ventricle than in healthy children, but there was no difference in MP before or post bidirectional cavopulmonary anastamosis**.** Mahle et al. [63] evaluated systemic ventricular function in 35 asymptomatic patients with functionally single right ventricle, and found that MPI was significantly higher than in controls. In a large study by Rhodes et al. [5] on 416 Fontan patients, MPI was elevated, but there was no correlation between ECHO indices and CMR-derived EF. These studies all suggested that MPI is a sensitive and objective method of assessing of ventricular function in patients with single ventricles and has particular value for serial quantitative follow-up.

In conclusion, TDI is a very important tool in the assessment of longitudinal myocardial function. The suggested measurements are suitable for patients with CHD, as they are easily applicable, suitable for serial non-invasive analysis, do not rely on geometric assumptions, and are partially load-independent. This is especially important for analyzing patients with complex CHD with unusual ventricular geometry and especially the right ventricle in general. However, there are some significant intrinsic limitations of TDI velocity imaging: angle dependency, noise, and the unidimensional assessment of myocardial motion (longitudinal, circumferential, or radial). Global cardiac translation of the entire heart during the cardiac cycle also affects the measurement and tethering effects between myocardial segments. Originally it was expected that TDI would be a useful method for the assessment of regional myocardial function, but this is not the case. The main reason is that if a dysfunctional segment is moved by a healthy segment (tethering effect), regional dysfunction will be masked [64].

Deformation imaging – strain rate and strain

Previous TDI methods for analyzing myocardial function are based on motion images, where velocity and displacement are measured. In deformation imaging the basic concept is the same, but the strain rate (SR) and strain (S) are being measured. However, there are some advantages and some limitations in this new methodology in comparison with TDI.

In order to understand the concept of SR and S, one should be aware of the term of deformation. During the heart cycle ventricular walls are moving in different directions and with different velocities, meaning that the ventricular walls and the heart are deforming. Generally, during systole, the base of the heart moves toward the apex, which is stationary. There are the following main directions of wall motion and deformation: longitudinal, circumferential, and radial or transmural. Additionally, different segments of myocardium move with different velocities. For instance, the basal segment of ventricular walls moves faster than the middle or the distal segments. Upon analyzing radial (transmural) velocities of thickening and thinning, subendocardial myocardium is moving faster than subepicardial (there is transmural velocity gradient) [65]. The result of that entire phenomenon is a deformation of the myocardium, as well as the heart. Ventricular wall deformation can be shortening and lengthening, and thickening and thinning.

The essence of deformation imaging is the analysis of segmental movements. This analysis mainly provides information about regional myocardial function, but also global function as well (global and regional SR and S). It is possible to analyze deformation in all three directions, longitudinal, circumferential and radial.

Strain rate and strain are measures of deformation, not contractility. Strain rate is the velocity motion of one part of the wall, which is calculated from the difference between the velocities of surrounding parts of myocardium, thus eliminating the effect

of heart movement in the chest. Strain rate values are expressed as s^{-1}. The strain is deformation, or relative change to its original length, expressed as a percentage of change. Decrease of the dimension (shortening of the wall in longitudinal direction during systole, or decrease of the circumferential dimension during systole, as well as thinning of the wall during diastole) is marked with a negative number (has the negative sign –). Contrary increase of the dimension (lengthening of the wall in a longitudinal direction during diastole, or increase of the circumferential dimension during systole, as well as thickening of the wall during systole) is marked with positive number (has the positive sign *+)*.

There are two methods for SR and S imaging: colour TDI and speckle-tracking in 2D greyscale images. The first one is based on color TDI with the determination of velocities in predefined wall regions. This method is rather complex; the operator should be well-trained, with different software solutions and with significant inter-observer variability. There are also several intrinsic limitations of this method, such as noise, angle-dependence, etc. There are a limited number of publications in paediatric cardiology with experience in CHD [66–77]**.**

Another method, 2D speckle-tracking, is based on greyscale images. The basic principle is based on the normal presence of an irregular – random – speckled pattern in myocardium, with those speckles following the motion of myocardium. The machine recognizes speckles, then follows them and calculates new position, distance and velocity [78, 79]. This method is easier to perform, allows immediate quantification and is, therefore, more suitable for everyday clinical practice.

Normal values for SR have already been investigated in several studies. One of the largest studies was performed on 1266 healthy individuals (HUNT study), and normal values for SR and S were published. Differences in SR and S between walls are small: normal peak systolic LV SR values are around $–1±0.26$ s^{-1}, and for S –16.2–17.3±4.3% [80]. Weidemann et al. [81] published normal values of 33 healthy children for SR and S. LV longitudinal deformation was homogeneous for LV basal, mid and apical segments (peak systolic SR: $–1.9 ± 0.7$ s^{-1}, systolic S –25 ± 7%), which are higher than in the adult population.

Deformation imaging techniques (SR and S) have some important advantages over the standard ECHO techniques. The main benefit of regional S and SR lies in the rapid and objective detection of regions with delayed or decreased deformation, while for traditional ECHO methods, one has to rely on subjective assessment for this information. Another advantage of this technique is its independence of ventricular geometry; therefore, it is suitable for evaluating right ventricular function or function of hearts with single-ventricle physiology. In adult cardiology deformation imaging is extremely useful in myocardial infarction and other diseases with regional wall motion abnormalities. Unfortunately, those methods are loading-dependent and dependent of age and heart rate [66].

With regard to the assessment of global and regional myocardial deformation, deformation imaging techniques are becoming useful tools for children and adults suffering from different CHDs [*67*].

Assessment of right ventricular function in CHD is still a great challenge, and as a result, the majority of studies are performed in patients with TOF, hypoplastic left heart syndrome, or right ventricle on systemic position [68–70].

It is well known that RV function is impaired in TOF patients after surgery, but the new methodology allowed the analysis of regional wall motion abnormalities. Weidemann et al. [71] published the results of 30 asymptomatic patients after operation of TOF and found that abnormalities in RV deformation were more marked in patients with transannular patches versus infundibular patches and were associated with electrical depolarization abnormalities. From a practical point of view, in the long-term follow-up optimal timing for pulmonary valve replacement in TOF patient is still an important question. Knirsch W et al. [72] published their initial results regarding the SR and S in TOF patients following surgical replacement of the pulmonary valve. Surprisingly, 6 months after surgery, right ventricular SR and S were lower than before the operation.

Another very important group of patients are those with single-ventricle physiology, most commonly after Fontan operation. It is well known that their long-term outcome largely depends on ventricular morphology and ventricular function [73, 74]. Many studies have shown worse systolic and diastolic function in patients with the right ventricular morphology in comparison with the left one [75, 76]. Recently, Petko et al. [77] published a study about longitudinal myocardial deformation and dyssynchrony in children with left and right ventricular morphology after the Fontan operation by speckle-tracking. The global longitudinal S and SR were similar in left and right ventricular morphology patients in the early period after Fontan operation, reflecting similar adaptation of longitudinal function of both ventricular morphologies to the single-ventricle circulation. Clearly, more studies and experience are necessary in order to better understand the mechanisms of heart dysfunction and the usefulness of new diagnostic methods.

Conclusions

Echocardiography is currently the most widely used method in the assessment of ventricular function. There is no single ideal technique or parameter for this purpose, so the combination of several of them is necessary in order to have more comprehensive information about different aspects of heart function. Besides the traditional methods, with a long-lasting experience in clinical practice, new techniques should be introduced in clinical routine. Evaluation of longitudinal myocardial function is crucial, especially in patients with CHD, using methods like tissue velocities, strain, and strain rate. Their high temporal resolution, relative independence from volume-loading and ease of acquisition are significant benefits. It is important to stress that

serial evaluations are important. Each ECHO laboratory should introduce the set of parameters for assessment of ventricular function, so as to be able to select the right one for different clinical settings and to be able to achieve the right perception of their values. This article has attempted to suggest the group of parameters most suitable for patients suffering from CHD with different ventricular geometries.

References

1. Cheitlin MD, Armstrong WF, Aurigemma GP, Beller GA, Bierman FZ, Davis JL, et al. The ACC/ AHA/ASE 2003 guideline update for the clinical application of echocardiography—summary article: a report of the American College of Cardiology/American Heart Association Task Force on Practice Guidelines (ACC/AHA/ASE Committee to Update the 1997 Guidelines for the Clinical Application of Echocardiography). J Am Coll Cardiol. 2003;42:954–70.
2. Sandstede J, Lipke C, Beer M, Hofmann S, Pabst T, Kenn W, et al. Age- and gender-specific differences in left and right ventricular cardiac function and mass determined by cine magnetic resonance imaging. European Radiology. 2000;10: 438–442.
3. Kühl HP, Schreckenberg M, Rulands D, Katoh M, Schäfer W, Schummers G, et al. High-resolution transthoracic real-time three-dimensional echocardiography quantitation of cardiac volumes and function using semi-automatic border detection and comparison With Cardiac Magnetic Resonance Imaging. J Am Coll Cardiol. 2004;43:2083–90.
4. Margossian R, Schwartz ML, Prakash A, Wruck L, Colan SD, Atz AM, et al. Comparison of echocardiographic and cardiac magnetic resonance imaging measurements of functional single ventricular volumes, mass, and ejection fraction (from the Pediatric Heart Network Fontan Cross-Sectional Study). Am J Cardiol. 2009; 104:419–428.
5. Rhodes J, Margossian R, Sleeper LA, Barker P, Bradley TJ, Lu M, et al. Pediatric Heart Network Investigators. Non-geometric echocardiographic indices of ventricular function in patients with a Fontan circulation. J Am Soc Echocardiogr. 2011;24(11):1213–9.
6. Sugimoto M, Manabe H, Nakau K, Furuya A, Okushima K, Fujiyasu H, et al. The role of N-terminal pro-B-type natriuretic peptide in the diagnosis of congestive heart failure in children: correlation with the heart failure score and comparison with B-type natriuretic peptide. Circ J. 2010; 74:998–1005.
7. Sahin M, Portakal O, Karagoz T, Hasçelik G, Özkutlu S. Diagnostic performance of BNP and NT-ProBNP measurements in children with heart failure based on congenital heart defects and cardiomyopathies. Clin Biochem. 2010; 43:1278–1281.
8. Atz AM, Zak V, Breitbart RE, Colan SD, Pasquali SK, Hsu DT, et al. Factors associated with serum brain natriuretic peptide levels after the Fontan procedure. Congen Heart Dis. 2011; 6:313–321.
9. Niedner MF, Foley JL, Riffenburgh RH, Bichell DP, Peterson BM, Rodarte A. B-type natriuretic peptide: perioperative patterns in congenital heart disease. Congen Heart Dis. 2010; 5:243–255.
10. Koch AM, Zink S, Singer H, Dittrich S. B-type natriuretic peptide levels in patients with functionally univentricular hearts after total cavopulmonary connection. Eur J Heart Fail. 2008;10:60–2.
11. Greenbaum RA, Ho SY, Gibson DG, Becker AE, Anderson RH. Left ventricular fibre architecture in man. Br Heart J. 1981;45:248–63.

12. Sengupta PP, Korinek J, Belohvalek M, Narula J, Vannan MA, Jahangir A, et al. Left ventricular structure and function: basic science for cardiac imaging. J Am Coll Cardiol.2006; 48:1988–2001.
13. Devereux RB, Roman MJ, Palmieri V, Liu JE, Lee ET, Best LG, et al. Prognostic implications of ejection fraction from linear echocardiographic dimensions: the Strong Heart Study. Am Heart J. 2003;146(3):527–34.
14. Palmieri V, Roman MJ, Bella JN, Liu JE, Best LG, Lee ET, et al. Prognostic implications of relations of left ventricular systolic dysfunction with body composition and myocardial energy expenditure: the Strong Heart Study. J Am Soc Echocardiogr. 2008;21(1):66–71.
15. Picard MH, Wilkins GT, Ray PA, Weyman AE. Natural history of left ventricular size and function after acute myocardial infarction. Assessment and prediction by echocardiographic endocardial surface mapping. Circulation. 1990;82:484e94.
16. Lang RM, Bierig M, Devereux RB, Flachskampf FA, Foster E,Pellikka PA, et al. ChamberQuantification Writing Group American Society of Echocardiography's Guidelines, Standards Committee, European Association of Echocardiography. Recommendations for chamber quantification: a report from the American Society of Echocardiography's Guidelines and Standards Committee and the Chamber Quantification Writing Group, developed in conjunction with the European Association of Echocardiography, a branch of the European Society of Cardiology. J Am Soc Echocardiogr. 2005; 18:1440–1463.
17. Marwick TH. Techniques for comprehensive two dimensional echocardiographic assessment of left ventricular systolic function. Heart. 2003; 89:iii2–iii8.
18. Zaca V, Ballo P, Galderisi M, Mondillo. Echocardiography in the assessment of left ventricular longitudinal systolic function: current methodology and clinical applications. Heart Fail Rev. 2010;15:23–37.
19. Roberson DA, Cui W. Tissue Doppler imaging measurement of left ventricular systolic function in children: mitral annular displacement index is superior to peak velocity. J Am Soc Echocardiogr. 2009;22:376–82.
20. Støylen A. Strain rate imaging. Cardiac deformation imaging by ultrasound / echocardiography Tissue Doppler and Speckle tracking. folk.ntnu.no/stoylen/strainrate
21. Dulce MC, Mostbeck GH, Friese KK, Caputo GR, Higgins CB. Quantification of the left ventricular volumes and function with cine MR imaging: comparison of geometric models with three-dimensional data. Radiology. 1993;188:371–6.
22. Schmidt MA, Ohazama CJ, Agyeman KO, Friedlin RZ, Jones M, Laurienzo JM, et al. Real-time three-dimensional echocardiography for measurement of left ventricular volumes. Am J Cardiol. 1999;84:1434–9.
23. Gopal AS, Keller AM, Rigling R, King DL Jr, King DL. Left ventricular volume and endocardial surface area by three dimensional echocardiography: comparison with two-dimensional echocardiography and nuclear magnetic resonance imaging in normal subjects. J Am Coll Cardiol. 1993;22:258–70.
24. Nosir YF, Fioretti PM, Vletter WB, Boersma E, Salustri A, Postma JT, et al. Accurate measurement of left ventricular ejection fraction by three-dimensional echocardiography: a comparison with radionuclide angiography. Circulation. 1996;94:460–6.
25. Rushmer RF, Thal N. The mechanics of ventricular contraction: a cine fluorographic study. Circulation. 1951;4:219–228.
26. Jones CJ, Raposo L, Gibson DG. Functional importance of the long axis dynamics of the human left ventricle. Br Heart J. 1990;63:215–20.

27. Vogel M, Derrick G, White PA, Cullen S, Aichner H, Deanfield J, et al. Systemic ventricular function in patients with transposition of the great arteries after atrial repair: a tissue Doppler and conductance catheter study. J Am Coll Cardiol. 2004;43:100–6.
28. Bos JM, Hagler DJ, Silvilairat S, Cabalka A, O'Leary P, Daniels O, et al. Right ventricular function in asymptomatic individuals with a systemic right ventricle. J Am Soc Echocardiogr. 2006;19:1033–7.
29. Mondillo S, Galderisi M, Ballo P, Marino PN; Study Group of Echocardiography of the Italian Society of Cardiology. Left ventricular systolic longitudinal function: comparison among simple M-mode, pulsed, and M-mode color tissue Doppler of mitral annulus in healthy individuals. J Am Soc Echocardiogr. 2006;19(9):1085–91.
30. Simonson JS, Schiller NB. Descent of the base of the left ventricle: an echocardiographic index of left ventricular function. J Am Soc Echocardiogr.1989;2:25–35.
31. Emilsson K, Wandt B. The relation between mitral annulus motion and ejection fraction changes with age and heart size. Clin Physiol. 2000;20(1):38e43.
32. Nestaas E, Støylen A, Brunvand L, Fugelseth D. Longitudinal strain and strain rate by tissue Doppler are more sensitive indices than fractional shortening for assessing the reduced myocardial function in asphyxiated neonates. Cardiology in the Young. 2011; 21: 1–7.
33. Qin JX, Shiota T, Tsujino H, Tsujino H, Saracino G, White RD, Greenberg NL, et al. Mitral annular motion as a surrogate for left ventricular ejection fraction: real e time three-dimensional echocardiography and magnetic resonance imaging studies. Eur J Echocardiogr. 2004;5:407e15.
34. Elnoamany MF, Abdelhameed AK. Mitral annular motion as a surrogate for left ventricular function: Correlation with brain natriuretic peptide levels. Eur J Echocardiography. 2006; 7:187e198.
35. Brand B, Rydberg E, Ericsson G, Gudmundsson P, Willenheimer R. Prognostication and risk stratification by assessment of left atrioventricular plane displacement in patients with myocardial infarction. Int J Cardiol. 2002; 83:35–41.
36. Willenheimer R, Cline C, Erhardt L, Israelsson B. Left ventricular atrioventricular plane displacement: an echocardiographic technique for rapid assessment of prognosis in heart failure. Heart. 1997;78:230–236.
37. Petrie MC, Caruana L, Berry C, McMurray JJ.''Diastolic heart failure'' or heart failure caused by subtle left ventricular systolic dysfunction? Heart. 2002;87:29–31.
38. Koulouris SN, Kostopoulos KG, Triantafyllou KA, Karabinos I, Bouki TP, Karvounis HI, et al. Impaired systolic dysfunction of left ventricular longitudinalfibers: a sign of early hypertensive cardiomyopathy. Clin Cardiol. 2005;28:282–6.
39. Takeda S, Rimington H, Smeeton N, Chambers J. Long axis excursion in aortic stenosis. Heart. 2001; 86:52–6.
40. Sutherland GR, Stewart MJ, Groundstroem KW, Moran CM, Fleming A, Guell-Peris FJ, et al. Color Doppler myocardial imaging: a new technique for the assessment of myocardial function. J Am Soc Echocardiogr. 1994;7:441–58.
41. Innelli P, Sanchez R, Marra F, Esposito R, Galderisi M.The impact of aging on left ventricular longitudinal function in healthy subjects: a pulsed tissue Doppler study. Eur J Echocardiogr. 2008;9:241–9.
42. Eidem BW, McMahon CJ, Cohen RR, Wu J, Finkelshteyn I, MD, Kovalchin JP, et al. Impact of cardiac growth on Doppler tissue imaging velocities: A study in healthy children. J Am Soc Echocardiogr. 2004;17:212 –21.

43. Roberson DA, Cui W, Chen Z, Madronero LF, Cuneo BF. Annular and septal Doppler tissue imaging in children: normal z-score tables and effects of age, heart rate, and body surface area. Am Soc Echocardiogr. 2007;20:1276–1284.
44. Hsiao SH, Huang WC, Sy CL, Lin SK, Lee TY, Liu CP. Doppler tissue imaging and color M-mode flow propagation velocity: are they really preload independent? J Am Soc Echocardiogr. 2005;18:1277–1284.
45. Eidem BW, McMahon CJ, Ayres NA, Kovalchin JP, Denfield SW, Altman CA, et al. Impact of chronic left ventricular preload and afterload on Doppler tissue imaging velocities: a study in congenital heart disease. J Am Soc Echocardiogr. 2005;18:830–8.
46. Vogel M, Cheung MM, Li J, Kristiansen SB, Schmidt MR, White PA, et al. Noninvasive assessment of left ventricular force-frequency relationships using tissue Doppler-derived isovolumic acceleration: validation in an animal model. Circulation. 2003;107:1647–52.
47. Oki T, Fukuda K, Tabata T, Yamada H, Abe M, Onose Y, et al. Effect of an acute increase in afterload on left ventricular regional wall motion velocity in healthy subjects. J Am Soc Echocardiogr. 1999;12:476–83.
48. Kiraly P, Kapusta L, Thijssen JM, Daniëls O. Left ventricular myocardial function in congenital valvar aortic stenosis assessed by ultrasound tissue-velocity and strain-rate techniques. Ultrasound Med Biol. 2003;29:615–20.
49. Weidemann F, Eyskens B, Mertens L, Dommke C, Kowalski M, Simmons L, et al. Quantification of regional right and left ventricular function by ultrasonic strain rate and strain indexes after surgical repair of tetralogy of Fallot. Am J Cardiol. 2002;90:133–8.
50. Toyono M, Harada K, Tamura M, Yamamoto F, Takada G. Myocardial acceleration during isovolumic contraction as a new index of right ventricular contractile function and its relation to pulmonary regurgitation in patients after repair of tetralogy of Fallot. J Am Soc Echocardiogr. 2004;17:332–7.
51. Kondo C, Nakazawa M, Kusakabe K, Momma K. Left ventricular dysfunction on exercise long-term after total repair of tetralogy of Fallot. Circulation. 1995;92:II250–II255.
52. Vitarelli A, Conde Y, Cimino E, D'angeli I, D'Orazio S, Ventriglia F, et al. Quantitative assessment of systolic and diastolic ventricular function with tissue Doppler imaging after Fontan type of operation. Int J Cardiol. 2005;102:61–9.
53. Tei C, Ling LH, Hodge DO, Bailey KR, Oh JK, Rodeheffer RJ, et al. New index of combined systolic and diastolic myocardial performance: a simple and reproducible measure of cardiac function – a study in normals and dilated cardiomyopathy. J Cardiol. 1995;26(6):357–66.
54. Tham EBC, Silverman NH. Measurement of the Tei index: a comparison of M-mode and pulse Doppler methods. J AmSoc Echocardiogr. 2004;17:1259–65.
55. Harada K, Tamura M, Toyono M, Oyama K, Takada G. Assessment of global left ventricular systolic function by tissue Doppler imaging. Am J Cardiol. 2001;88:927–32.
56. Gaibazzi N, Petrucci N, Ziacchi V, del Garda D. Left ventricle myocardial performance index derived either by conventional method or mitral annulus tissue-Doppler: a comparison study in healthy subjects and subjects with heart failure. J Am Soc Echocardiogr. 2005;18:1270–6.
57. Cui W, MD, Roberson DA. Left ventricular Tei Index in children: comparison of tissue Doppler imaging, Pulsed Wave Doppler, and M-Mode echocardiography normal values. J Am Soc Echocardiogr. 2006;19:1438–1445.
58. Eidem BW, Tei C, O'Leary PW, Cetta F, Seward JB. Nongeometric Quantitative Assessment of Right and Left Ventricular Function: Myocardial Performance Index

in Normal Children and Patients with Ebstein Anomaly. J Am Soc Echocardiogr 1998;11:849–56.
59. Dujardin KS, Tei C, Yeo TC, Hodge DO, Rossi A, Seward JB. Prognostic value of a Doppler index combining systolic and diastolic performance in idiopathic-dilated cardiomyopathy. Am J Cardiol. 1998;82:1071–6.
60. Harjai KJ, Scott L, Vivekananthan K, Nunez E, Edupuganti R. The Tei Index: A new prognostic index for patients with symptomatic heart failure. Am Soc Echocardiogr. 2002;15:864–8.
61. Norozi K, Buchhorn R, Alpers V, Arnhold JO, Schoof S, Zoege M, et al. Relation of systemic ventricular function quantified by myocardial performance index (Tei) to cardiopulmonary exercise capacity in adults after Mustard procedure for transposition of the great arteries. Am J Cardiol. 2005;96:1721–5.
62. Williams RV, Ritter S, Tani LY, Pagoto LT, Minich LL. Quantitative assessment of ventricular function in children with single ventricles using the Doppler myocardial performance index. Am J Cardiol. 2000;86:1106–10.
63. Mahle WT, Coon PD, Wernovsky G, Rychik J. Quantitative echocardiographic assessment of the performance of the functionally single right ventricle after the Fontan operation. Cardiol Young. 2001;11:399–406.
64. Dragulescu A, Mertens LL. Developments in echocardiographic techniques for the evaluation of ventricular function in children. Archives of Cardiovascular Disease. 2010; 103: 603—614.
65. Wilkenshoff UM, Sovany A, Wigstrom L, Olstad B, Lindstrom L, Engvall J, et al. Regional mean systolic myocardial velocity estimation by real-time color Doppler myocardial imaging: a new technique for quantifying regional systolic function. J Am Soc Echocardiogr. 1998;11:683–92.
66. Mori K, Hayabuchi Y, Kuroda Y, Nii M, Manabe T. Left ventricular wall motion velocities in healthy children measured by pulsed wave Doppler tissue echocardiography: normal values and relation to age and heart rate. J Am Soc Echocardiogr. 2000;13:1002–11.
67. FriedbergMK, Mertens L. Tissue velocities, strain, and strain rate for echocardiographic assessment of ventricular function in congenital heart disease. Eur J Echocardiogr. 2009;10:585–93.
68. Eyskens B, Weidemann F, Kowalski M, Bogaert J, Dymarkowski S, Bijnens B, et al. Regional right and left ventricular function after the Senning operation: an ultrasonic study of strain rate and strain. Cardiol Young. 2004; 14:255–64.
69. Friedberg MK, Silverman NH, Dubin AM, Rosenthal DN. Right ventricular mechanical dyssynchrony in children with hypoplastic left heart syndrome. J Am Soc Echocardiogr. 2007;20:1073–9.
70. Petko C, Uebing A, Furck A, Rickers C, Scheewe J, Kramer HH. Changes of right ventricular function and longitudinal deformation in children with hypoplastic left heart syndrome before and after the Norwood operation. J Am Soc Echocardiogr. 2011;24:1226–32.
71. Weidemann F, Eyskens B, Mertens L, Dommke C, Kowalski M, Simmons L, et al. Quantification of regional right and left ventricular function by ultrasonic strain rate and strain indexes after surgical repair of tetralogy of Fallot. Am J Cardiol. 2002;90:133–8.
72. Knirsch W, Dodge-Khatami A, Kadner A, Kretschmar O, Steiner J, Bottler P, et al. Assessment of myocardial function in pediatric patients with operated tetralogy of fallot: preliminary results with 2D strain echocardiography. Pediatr Cardiol. 2008;29:718–25.

73. Gentles TL, Mayer JE Jr, Gauvreau K, Newburger JW, Lock JE, Kupferschmid JP, et al. Fontan operation in five hundred consecutive patients: factors influencing early and late outcome. J Thorac Cardiovasc Surg. 1997;114:376–391.
74. Julsrud PR, Weigel TJ, Van Son JA, Edwards WD, Mair DD, Driscoll DJ, et al. Influence of ventricular morphology on outcome after the Fontan procedure. Am J Cardiol. 2000;86:319–323.
75. McGuirk SP, Winlaw DS, Langley SM, Stumper OF, de Giovanni JV, Wright JG, et al. The impact of ventricular morphology on midterm outcome following completion total cavopulmonary connection. Eur J Cardiothorac Surg. 2003;24:37–46.
76. Anderson PA, Sleeper LA, Mahony L, Colan SD, Atz AM, Breitbart RE, et al. Contemporary outcomes after the Fontan procedure: a Pediatric Heart Network multicenter study. J AmColl Cardiol. 2008;52:85–98.
77. Petko C, Hansen JH, Scheewe J, Rickers C,Kramer HH. Comparison of longitudinal myocardial deformation and dyssynchrony in children with left and right ventricular morphology after the Fontan operation using two-dimensional speckle tracking. Congenit Heart Dis. 2012;7:16–23.
78. Kvitting JP, Wigstrom L, Strotmann JM, Sutherland GR. How accurate is visual assessment of synchronicity in myocardial motion? An In vitro study with computer-simulated regional delay in myocardial motion: clinical implications for rest and stress echocardiography studies. J Am Soc Echocardiogr. 1999 Sep;12(9):698–705.
79. Kaluzynski K, Chen X, Emelianov SY, Skovoroda AR, O'Donnell M. Strain rate imaging using two-dimensional speckle tracking. IEEE Trans Ultrason Ferroelectr Freq Control. 2001 Jul;48(4):1111–23.
80. Dalen H, Thorstensen A, Aase SA, Ingul CB, Torp H, Vatten LJ, Stoylen A. Segmental and global longitudinal strain and strain rate based on echocardiography of 1266 healthy individuals: the HUNT study in Norway. Eur J Echocardiogr. 2010 Mar;11(2):176–83.
81. Weidemann F, Eyskens B, Jamal F, Mertens L, Kowalski M, D'Hooge J, et al. Quantification of regional left and right ventricular radial and longitudinal function in healthy children using ultrasound-based strain rate and strain imaging. J Am Soc Echocardiogr. 2002;15:20–8.