Baština Akademije nauka i umjetnosti Bosne i Hercegovine

Human Epidermal Growth Factor Receptors 1 and 2 (EGFR/HER1 and HER-2/NEU) status in invasive apocrine carcinoma of the breast: dissertation

Vranić, Semir

2012

https://bastina.anubih.ba/handle/123456789/846

Preuzeto s Baštine Akademije nauka i umjetnosti Bosne i Hercegovine

https://bastina.anubih.ba/

Središnja medicinska knjižnica

Vranić, Semir (2012) ***Human Epidermal Growth Factor Receptors 1 and 2 (EGFR/HER1 and HER-2/NEU) status in invasive apocrine carcinoma of the breast.*** **Doktorska disertacija, Sveučilište u Zagrebu.**

http://medlib.mef.hr/1636

University of Zagreb Medical School Repository
http://medlib.mef.hr/

UNIVERSITY OF ZAGREB
SCHOOL OF MEDICINE

Semir Vranić

Human Epidermal Growth Factor Receptors 1 and 2 (EGFR/HER1 and HER-2/NEU) status in invasive apocrine carcinoma of the breast

DISSERTATION

Zagreb, 2012

UNIVERSITY OF ZAGREB
SCHOOL OF MEDICINE

Semir Vranić

Human Epidermal Growth Factor Receptors 1 and 2 (EGFR/HER1 and HER-2/NEU) status in invasive apocrine carcinoma of the breast

DISSERTATION

Zagreb, 2012

This Ph.D. thesis has been completed at the Department of Pathology, Creighton University School of Medicine, Omaha, Nebraska, United States of America under supervision of Professor Zoran Gatalica, M.D., D.Sc.
Dr. Vranić was a research fellow at the Creighton University School of Medicine and had been supported by the UICC American Cancer Society Beginning Investigators Fellowship (ASCBI) award (ACS/08/004) funded by the American Cancer Society.

The parts of the dissertation have been published as:

1. **Vranic S**, Tawfik O, Palazzo J, Bilalovic N, Eyzaguirre E, Lee LMJ, Adegboyega P, Hagenkord J, Gatalica Z. EGFR and HER-2/neu expression in invasive apocrine carcinoma of the breast. Mod Pathol 2010;23:644-653.
2. **Vranic S**, Teruya B, Repertinger S, Ulmer P, Hagenkord J, Gatalica Z. Assessment of HER2 gene status in breast carcinomas with polysomy of chromosome 17. Cancer 2011;117:48-53.
3. **Vranic S**, Gatalica Z, Frkovic-Grazio S, Deng H, Lee LMJ, Gurjeva O, Wang ZY. ER-α36 a novel isoform of ER-α66 is commonly over-expressed in apocrine and adenoid cystic carcinoma of the breast. J Clin Pathol 2011;64:54-57.
4. **Vranic S**, Gurjeva O, Frkovic-Grazio S, Palazzo J, Tawfik O, Gatalica Z. IMP3, a proposed novel basal phenotype marker, is commonly over-expressed in adenoid cystic carcinomas but not in apocrine carcinomas of the breast. Appl Immunohistochem Mol Morphol 2011;19:413-416.
5. **Vranic S,** Gatalica Z, Wang ZY. Update on molecular profile of the MDA-MB-453 cell line, as a model for apocrine carcinoma studies. Oncol Lett 2011;2:1131-1137.

Supervisor:

Zoran Gatalica, M.D., D.Sc.

Adjunct Professor of Pathology, Creighton University School of Medicine

Omaha, Nebraska, USA

Director of Oncologic Pathology, Caris Life Sciences

Phoenix, Arizona, USA

ACKNOWLEDGMENTS

First of all I wish to thank Dr. Zoran Gatalica for being an excellent supervisor and friend all these years, particularly during the one year fellowship at Creighton University School of Medicine, Omaha, Nebraska, United States of America.

I highly appreciate a 6-month educative and inspiring period spent in the Lab of Dr. Zhao-Yi Wang and his team at the Creighton University School of Medicine who introduced me into the magic world of cell culturing.

I am very indebted to the very kind and supportive staff of Creighton Medical Laboratories/Pathology including Drs. Joseph Knezetic, Jill Hagenkord, Shera Kesh, Lisa M.J. Lee, as well as technicians Kay M. Krogman, Kristin Bonnstetter and Deborah Jankovich for teaching me various molecular techniques.

I also wish to thank Drs. Warren Sanger, Julia A. Bridge and Ms. Marilu Nelson, Human Genetics Laboratory, Munroe-Meyer Institute, University of Nebraska Medical Center, Omaha, NE for excellent cytogenetics support.

My Sarajevo colleagues led by the head of the Department Dr. Nurija Bilalović have been very supportive and encouraging all these years which I highly appreciate.

Drs. Ivan Damjanov (The University of Kansas School of Medicine, USA), Neil A. Shepherd (Cheltenham General Hospital, Cheltenham, UK), Geraint T. Williams (Cardiff University School of Medicine, UK) and Božo Krušlin ("Sestre milosrdnice" University Hospital and Zagreb University School of Medicine, Croatia) deserve my special thanks as they believed in me and supported my application for UICC/ACS fellowship. Drs. Krušlin and Damjanov have been particularly supportive all these years.

Last but not least is my gratitude to the collaborators – excellent pathologists including Drs. Juan Palazzo (Thomas Jefferson University, Philadelphia, PA), Ossama W. Tawfik (The Kansas University Medical Center, Kansas City, KS), Eduardo Eyzaguirre (The University of Texas Medical Branch, Galveston, TX), and Patrick Adegboyega (The University of Texas Medical Branch, Galveston, TX).

CONTENTS

1. Introduction 1
1.1 Apocrine carcinoma of the breast 1
1.2 The erbB (HER, human epidermal growth factor receptor) family 4
1.2.1 Epidermal growth factor receptor (EGFR/HER-1) 4
1.2.2 HER-2/neu gene 7
1.2.3 HER-3 gene 10
1.2.4 HER-4 gene 10
2. Hypothesis and Aims 11
3. Materials and Methods 12
3.1 Specimens 12
3.2 Immunohistochemistry (IHC) 12
3.3 Automated Cell Imaging System (ACIS) 13
3.4 FISH analysis 13
3.5 Conventional Cytogenetics 14
3.6 SNP array karyotyping 14
3.7 Statistical analysis 15
4. Results 16
4.1 Clinico-pathologic characteristics of the apocrine carcinoma cohort 16
4.1.1 Classification and steroid receptor profile of apocrine carcinomas 16
4.1.2 HER-2/neu expression in apocrine carcinomas 19
4.1.3 EGFR expression in apocrine carcinomas 20
4.1.4 Chromosomal analysis using conventional cytogenetics and SNP array assay 22
4.1.5 Molecular subclassification of carcinomas with apocrine morphology 25
4.2 Clinico-pathologic characteristics of the cohort with CEP17 polysomy 26
4.2.1 FISH results and interpretation 27
4.2.2 SNP array karyotyping and interpretation 29
4.2.3 Correlation between protein expression and HER-2/neu gene status 30
5. Discussion 31
6. Conclusions 38
7. Summary 39
8. Sažetak 40
9. References 42
10. Biography 55
11. Appendix (Published References) .....

ABBREVIATIONS

ACIS = Automated Cell Imaging System

ACS = American Cancer Society

ALC = Apocrine-like Carcinoma

ALDH = Aldehyde dehydrogenase

AR = Androgen Receptor

ASCO = American Society for Clinical Oncology

CAP = College of American Pathologists

CEP17 = Chromosome Enumeration Probe 17

CGH = Comparative Genomic Hybridization

CISH = Chromogenic in Situ Hybridization

CML = Creighton Medical Laboratories

EGF = Epidermal Growth Factor

EGFR = Epidermal Growth Factor Receptor (HER1)

EGFRvIII = Mutant Epidermal Growth Factor Receptor

ER = Estrogen receptor-α

ERK1/2 = Extracellular signal-regulated kinase 1/2

FFPE = Formalin-fixed paraffin-embedded

FISH = Fluorescent in-situ Hybridization

GCDFP-15 = Gross Cystic Disease Fluid Protein-15

H&E = Hematoxylin and eosin stain

HER (erbB) = Human Epidermal Growth Factor Receptor

HER-2/neu = Human Epidermal Receptor 2

HMG-CoA = Hydroxymethyl-glutaryl coenzyme A reductase

Hsr = Homogeneously staining region

IHC = Immunohistochemistry

kD = Kilodalton

MLPA = Multiplex ligation-dependent probe amplification

NAT1 = N-acetyltransferase

NF-κB = Nuclear factor-κB

NRG = The splice variants of neuregulin

NST = No-special-type

PAC = Pure Apocrine Carcinoma

PAK1 = p21/Cdc42/Rac1-activated kinase 1

PI3K = Phosphoinositide-3-kinase

PR = Progesterone Receptor

PTEN = Phosphatase and tensin homolog deleted on Chromosome 10

SNP = Single Nucleotide Polymorphism

TGF-α = Transforming Growth Factor-α

TOP2A = Topoisomerase II-α

UICC = Union for International Cancer Control

UNMC = University of Nebraska Medical Center (Omaha)

15-PGDH = 15-hydroxy-prostaglandin dehydrogenase

1. Introduction

Breast carcinoma is the most common malignancy that affects women and is also the most important cause of cancer-related death (1). The incidence varies substantially but has been increasing even in the regions that recently reported low rates of the disease (1).

1.1 Apocrine carcinoma of the breast

Invasive carcinoma of the breast comprises a heterogeneous group of tumors showing diverse morphologic, molecular, and clinical features (2, 3). Invasive ductal carcinoma of no special type (NST) is the most common type, constituting up to 75% of all breast malignancies (2, 4). The remaining 25% includes various special types with 18 different subtypes including apocrine carcinoma of the breast.

The histopathologic characteristics of breast cancers tend to be associated with distinct arrays of genetic changes, providing evidence for genotypic–phenotypic correlations between morphologic patterns and molecular changes in special types of breast carcinomas (5).

The initial microarray-based expression profile studies on breast carcinomas of NST revealed the existence of five molecular subtypes including luminal types (A and B), basal-like, ERBB2/HER-2-overexpressing and normal-like type (6, 7). Luminal subtypes A and B are estrogen receptor (ER) positive and share expression markers with the luminal epithelial layer of cells whereas basal-like carcinomas share expression markers with the underlying basal (myoepithelial) layer of normal breast ducts and are ER negative. The ERBB2 subtype is associated with expression of genes co-amplified with *ERBB2/HER-2/neu* (encoding Her-2/neu protein), and the normal-like subtype shares expression patterns with normal breast tissue (6, 7).

Apocrine differentiation (metaplasia) is commonly seen in the breast pathology, particularly in the context of fibrocystic breast disease (8-11) although it may be seen in association with other benign and malignant conditions (12). The benign breast lesions with apocrine morphology include papillary apocrine changes, apocrine cysts, apocrine adenosis (sclerosing adenosis with apocrine metaplasia), and apocrine adenoma (2, 8,

13). Malignant apocrine lesions of the breast include apocrine ductal carcinoma in situ and invasive apocrine carcinoma (8).

Apocrine carcinoma of the breast, defined as breast tumors composed of epithelium with apocrine differentiation in more than 90% of the tumor cell population, represents a rare subtype, constituting less than 5% of all breast cancers (4, 14, 15). Apocrine differentiation is defined by the presence of large cells with prominent eosinophilic, flocculent cytoplasm, with sharply defined cell borders, and with large nuclei containing prominent macronucleoli. The majority of cases of apocrine carcinomas tend to be sporadic although an association with Cowden syndrome caused by germline mutations of the tumor suppressor gene *PTEN* has recently been reported (16).

A characteristic steroid receptor expression profile defines apocrine carcinomas as consistently estrogen receptor (ER)-negative, progesterone receptor (PR)-negative, and androgen receptor (AR)-positive (12, 17-20). Although AR expression has been variably observed in up to 60-70% breast carcinomas (21-23), consistent AR expression tends to be a feature of apocrine breast lesions including invasive apocrine carcinomas (12, 17, 18, 24-30). Moreover, recently published gene expression microarray studies defined a characteristic “molecular apocrine” gene expression profile found in apocrine carcinomas (31-35). These studies showed apocrine tumors to be different from common luminal and basal cell breast carcinoma subtypes (31-34) and showed that they are characterized by increased androgen receptor (AR) signaling along with increased *HER-2/neu* gene signaling (31, 34). Differentially expressed genes also included the following genes: SPDEF, FOXA1, XBP1, CYB5, TFF3, NAT1, APOD, and ALCAM (20). These observations were later confirmed by gene expression meta-analysis that revealed the existence of molecular apocrine group characterized by increased AR signaling pathway and interactions between AR and the erbB receptors family (34). Androgen receptor is an active player in several important signaling pathways in breast carcinogenesis (36). Studies using apocrine cell line models (MDA-MB-453 and Sum-190) demonstrated the existence of a functionally significant cross-talk between AR and *HER-2/neu* pathways through ERK1/2 in ER negative breast carcinomas (37, 38). Specifically, AR regulates ERK phosphorylation and kinase activity. Furthermore, AR activation is associated with the overexpression of ERK signaling targets including

phospho-Elk-1 and c-Fos (38). This cross-talk affects cell proliferation and apoptosis and could have a significant therapeutic impact (37, 39, 40). Also, activation of the ERBB2-PI3K-AKT signaling pathway caused by loss of *PTEN* gene function may contribute to development of breast carcinomas with apocrine features (16, 41). Androgen receptor also mediates ligand-dependent activation of Wnt signaling pathway (36) while specific targeting of AR, Wnt or HER-2 signaling impairs androgen-stimulated tumor cell growth (36). Apocrine carcinomas frequently express an AR-producing enzyme 5-α reductase which converts testosterone to a potent dihydrotestosterone (29).

Apocrine carcinomas typically exhibit a strong cytoplasmic expression of gross cystic disease fluid protein-15 (GCDFP-15), an apocrine-specific marker, regulated by AR and other proteins involved in lipid metabolism (8, 15). At proteomic level, when compared with benign apocrine lesions, apocrine carcinomas also are characterized by increased S100A9 and S100A7 and decreased expression of 15-hydroxy-prostaglandin dehydrogenase (15-PGDH) and hydroxymethyl-glutaryl coenzyme A (HMG-CoA) reductase (15).

Although apocrine carcinoma exhibits distinctive histopathologic and molecular features, the lack of standardized diagnostic criteria has produced controversial and heterogeneous results in the scientific literature in terms of its immunohistochemical profile and molecular classification (15, 42-44).

1.2 The erbB (HER, human epidermal growth factor receptor) family

The erbB (HER, human epidermal growth factor receptor) family is composed of four homologous transmembrane receptors involved in growth factor cellular signaling (45). This family includes EGFR (HER-1, ErbB1), ErbB2 (HER-2/neu), ErbB3 (HER-3), and ErbB4 (HER-4) (46).

EGFR (or *HER-1*) and *HER-2/neu* genes are of particular importance in breast cancer pathogenesis as their activation and co-expression are associated with an aggressive clinical course and a poor outcome (46). Both proteins can be targeted by specific therapeutic modalities (monoclonal antibodies and tyrosine kinase inhibitors).

1.2.1 Epidermal growth factor receptor (EGFR/HER-1)

EGFR is a 170 kD transmembrane receptor encoded by the human *HER1* gene which maps to 7p11.2-p12 (47). The EGFR protein has an extracellular ligand binding domain, a transmembrane region, and an intracellular domain with intrinsic protein-tyrosine kinase activity and multiple autophosphorylation sites clustered at the C-terminal tail (46, 47). The extracellular domain of EGFR consists of four subdomains (I–IV). Subdomains I and III (also called L1 and L2) have a beta helical fold and are involved in ligand binding (48).

EGFR is homologous to other members of the EGF receptor/erbB family including HER-2/erbB2 or neu, HER-3/erbB3 and HER-4/erbB4/. All four members can form homo- and heterodimers (46, 47). EGFR-specific ligands include epidermal growth factor [EGF], transforming growth factor-α [TGF-α], and amphiregulin (47, 48) all of which may induce distinct biological responses and patterns related to EGFR signaling (46). EGFR activates several key signaling pathways including PI3K/AKT signaling pathway, Ras/Raf1/Mitogen-activated protein kinase signaling pathway, SRC/NF-κB, catenin/cytoskeleton, and PAK-1/rac signaling pathway and plays a pivotal role in proliferation and survival of breast epithelium (47).

EGFR protein expression has been observed in a variety of normal cells including many epithelial cell types and tumors derived from them. Non-epithelial cell types that may express EGFR include smooth muscle, fibroblasts, endothelial cells, sympathetic ganglia, and peripheral nerve fibers (49).

Dysregulation of EGFR has been described in various human malignancies including breast cancer (46, 47). Dysregulation can occur via increased receptor activation (e.g. binding of ligands: EGFs, TGF-α or amphiregulin), activating mutations, decreased activity of phosphatases that inhibit tyrosine kinase domain of EGFR, abnormal heterodimerization and cross-talk with various molecules including other ErbB receptors, cell adhesion molecules, cytokine receptors, and ion channels (46, 47). A particularly important type of EGFR activation is EGFRvIII mutation frequently encountered in glioblastoma multiforme (48). The EGFRvIII mutant receptor contains an in-frame deletion of exons 2-7 from the extracellular region resulting in the 145 kD constitutively active EGFR protein (48). EGFRvIII has also been described in breast carcinomas, particularly in those exhibiting stem cell features ($CD44^+/CD24^-$ phenotype or ALDH positivity) (50).

EGFR status has been extensively studied in breast pathology including breast cancer (46). Breast cancer cells tend to over-express EGFR protein in a range between 18-35% whereas *EGFR* gene amplification has been only observed in ~6% of breast carcinomas (51). Activating mutations of the *EGFR* gene appear to be an exceptionally rare phenomenon in breast cancer with only single reports harboring *EGFR* gene mutation (52-55).

EGFR protein expression is particularly common (~70%) in a subset of breast carcinomas defined as triple-negative carcinomas with basal-like characteristics ("basal-like") and BRCA-1-mutated breast carcinomas (47, 56-58). Both groups exhibit a characteristic triple-negative immunophenotype (ER-/PR-/Her-2-/) with expression of one of basal cell markers including basal cytokeratins (CK5/6, CK14, CK17) and/or EGFR protein (3, 59, 60). Some researchers proposed EGFR protein to be specific for triple-negative breast carcinomas (61) serving as a surrogate marker for a "basal-like" phenotype (62). Nevertheless, the "basal-like" group also rarely exhibits EGFR gene alterations (mutations or gene amplification) (47, 57, 58, 63).

EGFR status has not been extensively studied in apocrine carcinoma of the breast (34, 42, 64). Apocrine metaplasia of the breast does not tend to over-express EGFR protein (65). A study of *Bhargava et al* (2010) based on a small subset of breast tumors with apocrine differentiation, indicated a preponderance of these tumors to overexpress EGFR protein (64). MDA-MB-453 breast cancer cell line, proposed to have

apocrine features, also tends to over-express EGFR protein without underlying *EGFR* gene amplification (66). Based on the analysis of EGFR phosphorylation sites, *Koletsa et al* (2010) also reported that HER-2-positive breast carcinomas tend to have EGFR protein activated but without *EGFR* gene amplification (67).

1.2.2 HER-2/neu gene

HER-2/neu is a proto-oncogene located on chromosome 17 (17q21-22) (68), (Figure 1). Its structure is similar to that of EGFR. *HER-2/neu* gene encodes a 185 kD tyrosine-kinase receptor located on the surface of the breast epithelial cells (68, 69). Her-2/neu receptor also closely interacts with other erbB family members who act as receptors for various ligands (EGFs, TGF-α, amphiregulin) (48, 70-72). Her-2/neu receptor has no cognate ligands (48). It exerts effects through heterodimerizations among which HER-2/HER-3 heterodimers appear to be the most potent (48). This dimer has a high propensity to activate PI3K/AKT and Ras/Raf1/Mitogen-activated protein kinase signaling pathway both of which are critically important for cell survival and proliferation (48). Besides, HER-2/HER-3 dimers can evade downregulation mechanisms leading to prolonged survival (48).

HER-2/neu status analysis is mandatory in all breast carcinomas as an appropriate therapeutic strategy to target this oncoprotein has been developed (Trastuzumab (Herceptin ®; Genentech, South San Francisco, CA, USA) (73-77). Trastuzumab represents a recombinant humanized monoclonal antibody (rhumAb 4D5) targeted against an extracellular domain of *HER-2/neu* gene (78). Recently, several novel anti-HER-2 based drugs including monoclonal antibodies and tyrosine kinase inhibitors have also demonstrated a promising activity in the treatment of HER-2 positive breast cancer (79).

The protein expression is usually determined by immunohistochemistry (77). Several commercially available antibodies have been validated and routinely used including: A0485 (HercepTest, Rabbit polyclonal, DAKO), CB11 (Mouse monoclonal, Ventana), SP3 (Rabbit monoclonal, NeoMarkers), TAB250 (Mouse monoclonal, Invitrogen), and 4D5 (Mouse monoclonal, Genentech) (77).

The primary mechanism of Her-2/neu overexpression in breast cancer is amplification of the *HER-2/neu* gene (69). The rate of *HER-2/neu* gene amplification is now estimated to be approximately 15% of all breast cancers which is much lower in comparison with the rates reported in the historic studies (25-30%) (69, 80-82). The *HER-2/neu* gene amplification correlates well with overexpression of Her-2/neu protein measured by immunohistochemistry.

Amplification of the *HER-2/neu* gene is typically detected by fluorescence in situ hybridization (FISH), although other in situ hybridization methods are now increasingly used (chromogenic [CISH] and silver in situ hybridization [SISH]) as well as multiplex ligation-dependent probe amplification [MLPA]) and comparative genomic hybridization (CGH) (83-84). Only two of the abovementioned methods (FISH and CISH) have been however approved by the US American Food and Drug Administration for routine diagnostics (83).

For FISH analysis, three different kits have been approved by the US Food and Drug Administration: 1) PathVysion (Abbott Laboratories, Abbott Park, Ill), 2) INFORM (Ventana Medical Systems, Tucson, AZ), or 3) PharmDx (DAKO, Glostrup, Denmark). The INFORM kit evaluates only the HER-2/neu gene copy number, and results are based on the absolute *HER-2/neu* signal count. The PathVysion and PHarmDx kits employ two probes, a HER-2/neu probe and a chromosome 17 centromere enumeration probe (CEP17) hybridization control probe, and results are based on the *HER-2*/CEP17 ratio.

Current American Society of Clinical Oncology/College of American Pathologists (ASCO/CAP) guidelines define HER-2-positive tumors as those with an average *HER-2/neu* gene copy number of > 6 gene copies per nucleus (for single probe assays) or as a *HER-2*/CEP17 ratio of > 2.2 (for double probe assays) (73). Typically, similar conclusions are obtained with either the absolute *HER-2/neu* signal count or the *HER-2*/CEP17 ratio (85), but discrepancies can occur in cancers with increased CEP17 copy number (≥3 copies per tumor cell). For example, tumors with increased CEP17 copy number and slightly increased *HER-2/neu* copy number may be considered amplified by single probe assays but unamplified by double probe assays. It is estimated that this occurs in 2-9% of breast cancers (86-87). However, the reported frequency of CEP17 copy number alteration in breast cancer varies, depending on the study population, selection criteria, and the definition of chromosome 17 polysomy (CEP17) (77, 88-93).

In the literature, it is commonly assumed that an increase in CEP17 copy number is due to polysomy 17, and these terms have been used interchangeably. However, it is important to recognize that an increase in CEP17 signals does not

necessarily represent a true polysomy (i.e. gain of the entire chromosome), but rather may represent a focal pericentromeric gain or a partial polysomy (92-95).

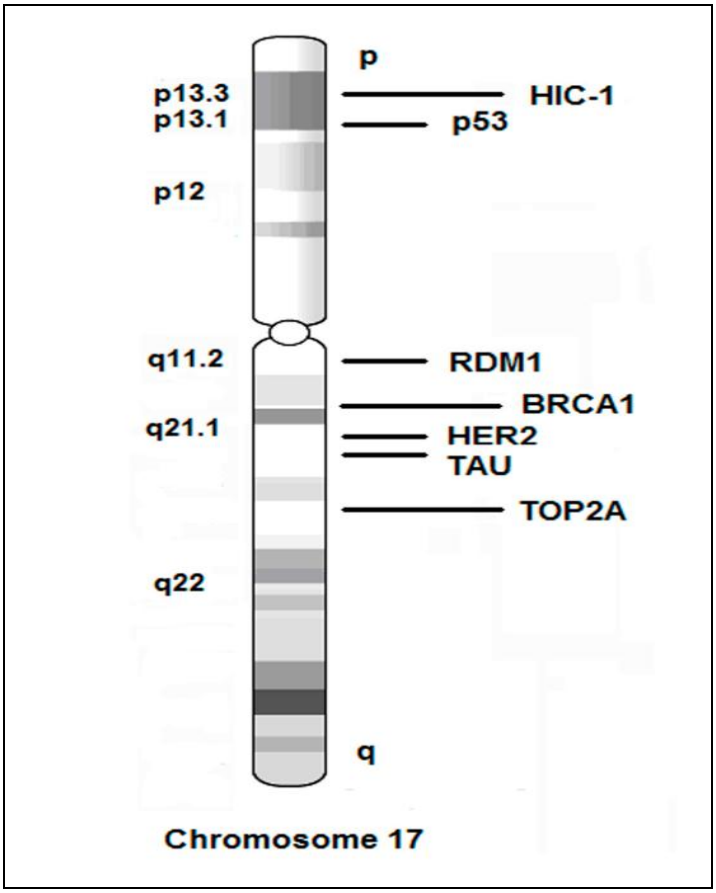

Figure 1. Schematic representation of chromosome 17 with important genes including *HER-2/neu* gene at 17q21-22

(From: Zhang W et al, Int J Mol Sci 2011;12:5672-5683). [Open Access Journal]

1.2.3 HER-3 gene

The *HER-3* gene is located on chromosome 12q13 (96). It encodes protein receptor that binds to the splice variants of neuregulins (NRG-1 and NRG-2) (96). HER-3 activation is closely related to the formation of heterodimers with other erbB/HER family members as HER-3 receptor has no intrinsic kinase activity (96). Of particular importance is the HER-2/HER-3 heterodimer complex that induces a significant mitogenic activity in breast cancer (96).

HER-3 protein overexpression has been observed in approximately 30% of all breast carcinomas with contradictory results in regards to its prognostic significance (96).

HER-3 appears to be involved in apocrine carcinoma pathogenesis as AR induces its expression through close interaction with *HER-2/neu* resulting in a positive feedback loop between AR and *HER-2/neu* (9, 36). This mechanism involves Wnt signaling activation via WNT7B leading to translocation of β-catenin to nucleus to help AR transactivate the *HER-3* promoter region (9, 36).

1.2.4 HER-4 gene

The *HER-4 gene* is located on chromosome 2q33.3-34. It encodes protein that can be activated by both NRGs and various ligands of the EGF family (96). Four different isoforms of HER-4 receptor have been isolated.

In contrast to other erbB family members, it induces antiproliferative and pro-apoptotic effects in breast cancer cells, mainly antagonizing HER-2 signaling activity (96).

HER-4 overexpression has been observed in approximately 50% of breast carcinomas and was associated with a favorable outcome (96).

2. Hypothesis and Aims

Basic hypothesis of the proposal is that cyto-morphologically defined invasive apocrine carcinomas are not a homogenous cancer subtype. Additional molecular investigations are necessary to define apocrine phenotype, and steroid receptor expression profile (immunohistochemistry for estrogen receptor, progesterone receptor, and androgen receptor) is necessary to accurately define this mammary carcinoma subtype. This could result in a sub-classification of this morphologic category into pure apocrine and apocrine-like carcinomas. Importantly, this reclassification can impact a commonly observed association between apocrine breast carcinoma and expression of EGFR and Her-2/neu proteins.

We hypothesize that the primary mechanism of Her-2/neu protein over-expression in apocrine carcinomas is due to the underlying *HER-2/neu* gene amplification while *EGFR* gene amplifications are uncommon.

The aims of this study are:

1. To refine a subgroup of invasive breast carcinomas with apocrine morphology on the basis of characteristic steroid receptor profile (Estrogen Receptor negative, Progesterone Receptor negative, and Androgen Receptor positive).
2. To explore the status of tyrosine kinase receptors epidermal growth factor receptor (EGFR or HER-1) and human epidermal receptor (HER-2/neu) using immunohistochemistry (protein expression) and fluorescent in-situ hybridization (gene copy number).
3. To explore a possible impact of polysomy of chromosomes 7 and 17 on the test interpretation and the status of EGFR and Her-2/neu protein expression.

3. Materials and Methods

3.1 Specimens

The formalin fixed paraffin-embedded (FFPE) tumor samples were obtained from 55 female patients with invasive apocrine carcinomas (52 surgical and 3 core biopsy specimens). Routinely stained hematoxylin and eosin (H&E) tumor sections were re-examined and the diagnoses confirmed. The cases were retrieved from the files of Creighton University Medical Center (Omaha, NE, USA), Kansas University Medical Center (Kansas City, KS, USA), Thomas Jefferson University Hospital (Philadelphia, PA, USA), The University of Texas Medical Branch (Galveston, TX, USA), and Clinical Center of the University of Sarajevo (Sarajevo, Bosnia and Herzegovina).

The Nottingham histologic grading system was applied for the tumor grading (97, 98).

An extended cohort of 72 patients whose breast cancers had greater than or equal to three Chromosome Enumeration Probe 17 (CEP17) signals per nucleus on average by fluorescent in situ hybridization (FISH) was used for further evaluation of impact of polysomy of chromosome 17 (CEP17 polysomy) on *HER-2/neu* gene copy number/Her-2 protein interpretation. These cases were retrieved from the pathology reports from Creighton Medical Laboratories [CML] (Creighton University, Omaha, NE, USA). The cohort represented approximately 12% of all HER2-tested cases in the period 2003-2007.

Institutional review board of Creighton University approved the study.

3.2 Immunohistochemistry (IHC)

Immunohistochemical assays for estrogen receptor-alpha (ERα; clone 6F11, Ventana Medical Systems, Inc. Tucson, AZ), progesterone receptor (PR; clone 16, Ventana Medical Systems, Inc. Tucson, AZ), androgen receptor (AR; Clone AR441, DakoCytomation, Inc. Carpinteria, CA), EGFR (DAKO EGFR PharmDX diagnostic kit; DakoCytomation, Inc. Carpinteria, CA), and Her-2/neu (Clone CB11, Ventana Medical Systems, Inc. Tucson, AZ) expression were performed on FFPE tissue sections using the commercially available detection kits and automated staining procedures.

The tumor was regarded as positive for ER and PR if more than 5% of the cells showed nuclear staining, while a 10% cutoff was applied for AR staining (20, 99, 100).

Her-2/neu protein expression results were scored according to the American Society of Clinical Oncology/College of American Pathologists Guideline Recommendations (73). Briefly, cases showing no membrane immunostaining or membrane immunostaining in less than 10% tumor cells were scored 0+, cases with weak and incomplete membrane staining in more than 10% of tumor cells were scored 1+, cases with complete membrane staining that was either non-uniform or weak in intensity but with obvious circumferential distribution in more than 10% of cells were scored 2+ and cases with strong membrane staining in more than 30% tumor cells were scored 3+ (73).

EGFR protein expression was scored according to the scoring guidelines for Her-2/neu protein (101).

3.3 Automated Cell Imaging System (ACIS)

Quantitative image analysis was performed using ACIS (ChromaVision Medical Systems, Inc., San Juan Capistrano, CA). ACIS was used for measuring the percentage of cells with the nuclear staining for ER, PR, and AR, and the extent and the intensity of the membranous staining of EGFR and Her-2/neu proteins. The images were reviewed and tumor-rich areas of the sections were selected for the analysis. The ACIS scoring system for Her-2/neu protein was as follows: score <1.0 (negative, equivalent to 1+), score 1.0-2.4 (borderline, 2+), and score ≥2.4 (positive, 3+).

3.4 FISH analysis

Fluorescent in-situ hybridization (FISH) was performed to evaluate copy number at *EGFR* and *HER-2/neu* loci. Chromosome enumeration probes CEP7 and CEP17 were used as positive controls and indicators of chromosome ploidy (Abbott Molecular Inc., Des Plaines, IL). Probe signals were enumerated in predominant tumor cell populations. At least thirty nuclei were scored per sample. A ratio of *HER-2/*CEP17 > 2.2 was defined as gene amplification; a ratio 1.8-2.1 was interpreted as borderline, and a ratio < 1.8 was defined as negative. The same criteria were used for interpretation

of *EGFR*/CEP7 ratios. Equivocal FISH results (ratio of 1.8-2.2) were considered as negative for *HER-2/neu* and *EGFR* gene amplification, respectively (73). CEP7 and 17 polysomy were defined as three or more CEP signals per cell (45, 102-104).

Stromal cells and normal breast epithelial cells served as an internal control.

3.5 Conventional Cytogenetics

Cytogenetic analysis was performed on biopsy tissue of one pure apocrine carcinoma harboring *HER-2/neu* gene amplification and CEP17 polysomy. Culture initiation, maintenance and harvesting were done using standard methods (105). Chromosomes were G-banded using pancreatin and analyzed using a Cytovision image analysis system (Applied Imaging, Santa Clara, CA).

3.6 SNP array karyotyping

Single nucleotide polymorphism (SNP) array karyotyping was performed on four cases including two cases of apocrine carcinomas with *HER-2/neu* gene amplification and two cases of invasive ductal carcinomas (NST) exhibiting a borderline Her-2/neu score on IHC (score 2+) and CEP17 polysomy on FISH analysis.

Following tumor enrichment via manual microdissection, DNA was obtained from 10 µm paraffin sections according to a previously described protocol for deparaffinization and DNA extraction (106). Samples were processed with the 250K Nsp Assay Kits (Affymetrix, Santa Clara, CA). Briefly, 1 µg of gDNA was digested with *Nsp* restriction enzyme, ligated to the adaptors, and amplified by PCR using a universal primer. After purification of PCR products with SNP Clean magnetic beads (Agencourt Biosciences, Beverly MA, USA), amplicons were quantified, fragmented, labeled, and hybridized to 250K *Nsp* arrays. After washing and staining, the arrays were scanned to generate CEL files for downstream analysis.

Data acquired from the Affymetrix GeneChip Operating System v4.0 (GCOS) was analyzed using Affymetrix Gene-Chip Genotyping Analysis Software (GTYPE) 4.1. Copy number analysis was performed with Copy Number Analyzer for Affymetrix GeneChip arrays (CNAG 3.0), as described before (107).

3.7 Statistical analysis

Where appropriate, chi-square test/Fisher's exact test or non-parametric tests (Mann-Whitney *U*-Test) were used for comparisons of the groups. Spearman's correlation rank was applied for the correlation between the variables. All statistical tests were 2-sided and *P*-values of less than 0.05 were considered significant. The statistical analysis was done with the Statistical Package for the Social Sciences version 17.0 (SPSS Inc., Chicago, IL).

4. Results

4.1 Clinico-pathologic characteristics of the apocrine carcinoma cohort

All patients were females. Patients' mean age was 62 years (range: 32-92 years). Routinely stained hematoxylin and eosin (H&E) tumor sections were re-examined and the diagnoses confirmed. Morphologically, all 55 cases fulfilled criteria for apocrine carcinoma and were characterized by large cells with prominent eosinophilic, flocculent cytoplasm, sharp cell borders, and large nuclei with prominent macronucleoli (Figure 2A-B).

Of the fifty-five cases 28 cases (50.9%) were histologic grade 3, 24 cases (43.6%) grade 2 and only three cases (5.4%) histologic grade 1.

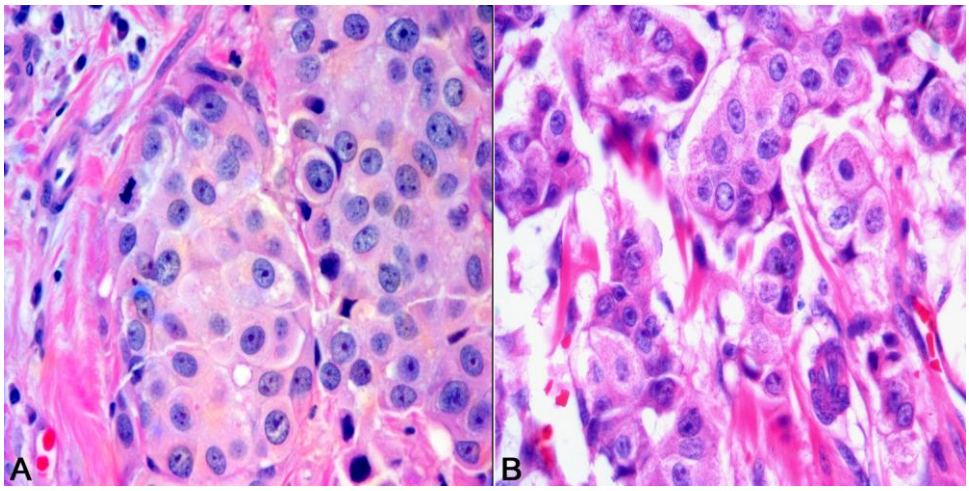

Figure 2A-B. Hematoxylin & eosin (HE) stained sections of two cases of breast carcinomas with similar apocrine morphology: (A): pure apocrine carcinoma (ER-/PR-/AR+); (B): Apocrine-like carcinoma (ER+/PR-/+/AR+/-).

4.1.1 Classification and steroid receptor profile of apocrine carcinomas

Thirty-eight (69.1%) out of 55 cases fulfilled immunophenotypic diagnostic requirements for pure apocrine carcinoma (PAC): ER and PR negative, AR positive (Fig. 2A, 2C, 2E; Table 1). The 17 remaining cases (30.9%) were then termed 'apocrine-like' carcinomas (ALC) because they lacked the specific apocrine immunophenotypic profile (Fig. 2B, 2D, 2F). These were further subcharacterized as:

ALC with ER+/AR- immunophenotype (3 cases), ALC with ER-/AR- immunophenotype (4 cases), and ALC with ER+/AR+ immunophenotype (10 cases) (Table 1).

The mean tumor AR positivity was significantly higher in the PAC subgroup in comparison with the ALC AR+/ER+ subgroup (75.8% vs. 58.9%, p=0.037). PAC exhibited a diffuse and strong nuclear staining of androgen receptor (16/30 or 53.3% of PAC had a 100% cells expressing AR) (Figure 2E). In contrast, none of the 17 ALC cases exhibited such complete AR expression.

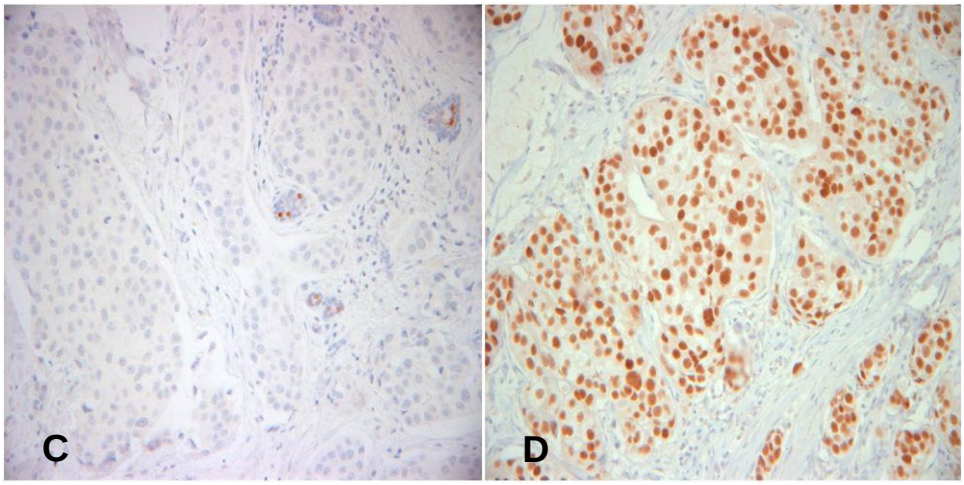

Figure 2C-D: Immunohistochemistry (IHC) showing negative estrogen receptor expression in a case of pure apocrine carcinoma with a positive staining of normal epithelium (C), and strongly positive expression in an apocrine-like breast carcinoma (D).

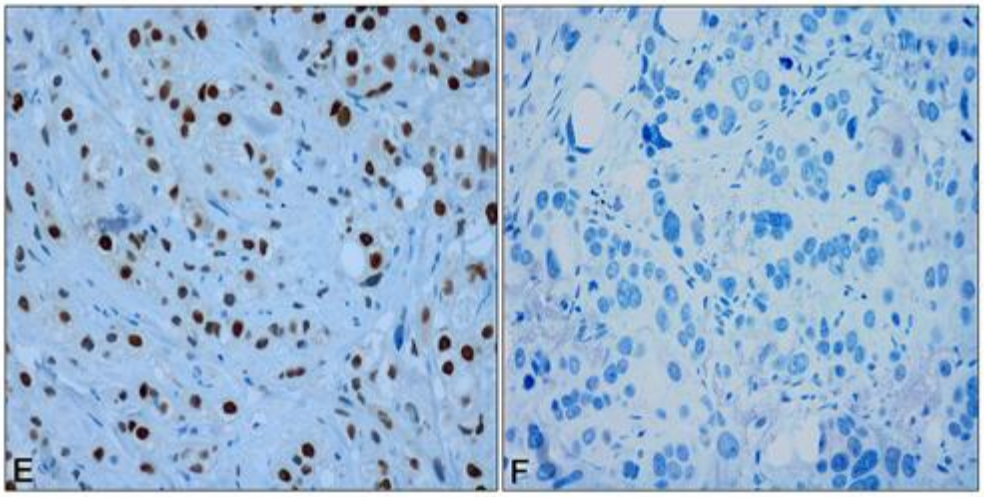

Figure 2E-F: IHC showing diffusely positive androgen receptor expression in a case of a pure apocrine carcinoma (E), and negative expression in an apocrine-like carcinoma (F).

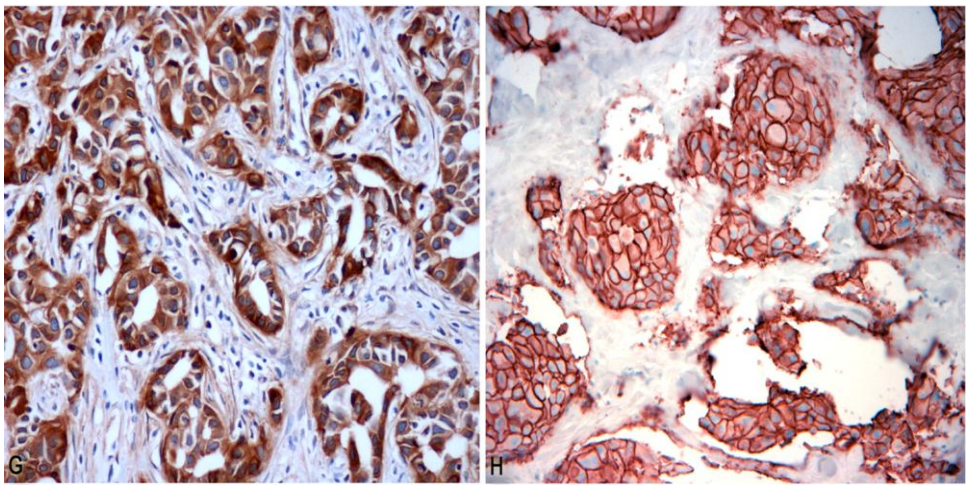

Figure 2G-H: IHC showing strong membrane expression of EGFR protein (score 3+) in a case of pure apocrine carcinoma (G), and 3+ membrane expression of Her-2/neu protein in a case of apocrine-like breast carcinoma (H).

4.1.2 HER-2/neu expression in apocrine carcinomas

Her-2/neu protein overexpression (score 3+) was observed in 53.7% of the cases in the entire cohort without significant difference between the PAC and ALC groups (56.8% vs. 47.1%, p=0.81) (Fig. 2G).

HER-2/neu gene amplification was detected in 28 of 54 tested cases (51.9%) without significant differences between the PAC and the ALC group (54% vs. 46%, p=0.42) (Fig. 3A; Fig. 5A-B). The average *HER-2/neu* gene signal number per cell ranged from 1.67-50 (mean: 9.57). *HER-2/neu* FISH results were concordant with Her-2/neu immunohistochemistry results in 49 of 53 available cases (92.5%). Four positive immunohistochemistry Her-2/neu results (score 3+) were discordant with *HER-2/neu* FISH results (negative for *HER-2/neu* gene amplification). Three of eight cases (37.5%) with equivocal immunohistochemistry (score 2+) had *HER-2/neu* gene amplification.

Six samples had fewer *HER-2/neu* signals per cell than signals for chromosome 17 centromere (ratio: 0.72-0.99). One of these cases had a Her-2/neu protein overexpression.

CEP17 polysomy (defined as three or more copies of CEP17 signals per nucleus) was observed in 10 PACs (32.3%) and 8 ALCs (50%). CEP17 polysomy was seen without *HER-2/neu* gene amplification in 8 cases (Fig. 3C) and with *HER-2/neu* gene amplification in 10 cases. The CEP17 polysomy rate was low: mean 3.55 CEP17 signals; (range: 3.0-6.0). Two PACs and three ALCs (5/8, 62.5%) with CEP17 polysomy alone, had Her-2/neu protein expression scores of 2-3+ by IHC.

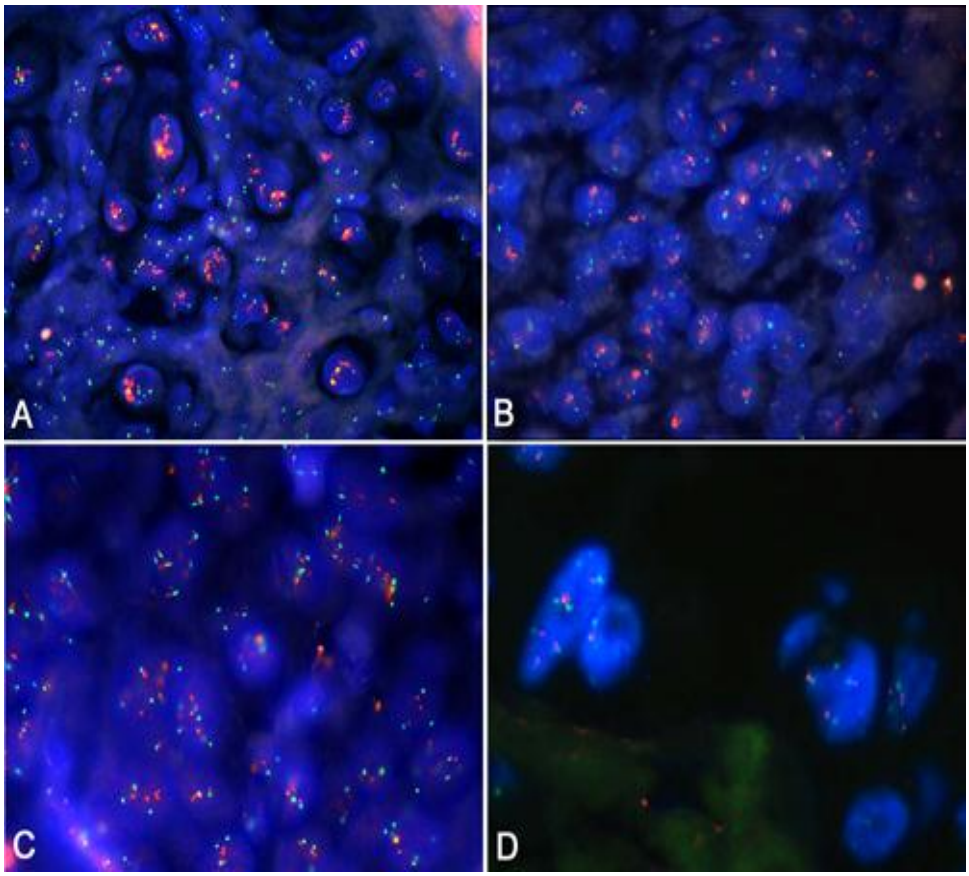

Figure 3. Pure apocrine carcinomas showing *HER-2/neu* gene amplification (A); *EGFR* gene amplification (B); Polysomy 17 (CEP17) without *HER-2/neu* gene amplification in a case of an apocrine-like carcinoma [average: 6.06 signals per cell] (C), and polysomy 7 (CEP7) without *EGFR* gene amplification [average: 3.62 signals per cell] (D).

4.1.3 EGFR expression in apocrine carcinomas

Thirty four out of 55 (61.9%) cases expressed EGFR protein (scores 1-3+). A significantly higher proportion of PACs was positive for EGFR protein in comparison with the ALC subgroups (76.3% vs. 29.4%, p=0.006) (Fig. 2H). A diffuse (more than 50% of positive cells) and strong (intensity scores 2-3+) EGFR expression, was seen in 20/29 (68.9%) of the PAC-positive cases and 5/5 (100%) of the ALC-positive cases.

EGFR gene amplification was a rare event, present only in three (2 PAC and one ALC tumors) of 44 studied cases (6.8%) (Fig. 3B). All three cases exhibited EGFR protein overexpression. The average *EGFR* gene signal number per cell ranged from 1.6-20 (mean: 5.76).

Polysomy of chromosome 7 (CEP7 polysomy) (defined as three or more copies of CEP7 signals per nucleus) was detected in 20/33 PACs (60.6%) and 3/11 ALCs (27.3%) either alone (21 cases) (Fig. 3D) or in association with the *EGFR* gene amplification (2 cases). CEP7 polysomy was more frequently observed in the PAC subgroup compared with the ALC subgroup (p=0.083). Overall, the level of CEP7 polysomy was low (mean: 4.09, range: 3.0-7.06). A weak positive correlation between polysomy 7 and the EGFR protein expression was also present (p=0.025, r=.326).

Table 1. Status of EGFR and Her-2/neu protein expression and gene amplification in pure apocrine carcinomas (PAC) and subgroups of apocrine-like carcinomas (ALC).

Category	**Androgen receptor (AR)[1]**	**Her-2/neu (IHC)[2]**	***HER-2/neu* (FISH)[3]**	**EGFR (IHC)[4]**	***EGFR* (FISH)[3]**
PAC	38/38 (100%) Mean: 75.76 Range: 10-100	21/37 (56.8%)	20/37 (54%)	29/38 (76.3%)	2/35 (5.7%)
ALC (ER+, AR+)	10/10 (100%) Mean: 58.93 Range: 15-90	2/10 (20%)	4/10 (40%)	3/10 (30%)	1/7 (14.3%)
ALC (ER+, AR-)	0/3 (0%)	3/3 (100%)	3/3 (100%)	0/3 (0%)	0/1 (0%)
ALC (ER-, AR-)	0/4 (0%)	3/4 (75%)	1/4 (25%)	2/4 (50%)	0/4 (0%)

[1] Positivity defined if more than 10% cells exhibited nuclear staining
[2] Defined by the 3+ score by IHC
[3] Defined by the gene to centromere ratio > 2.2
[4] Scores 1-3+ by IHC

4.1.4 Chromosomal analysis using conventional cytogenetics and SNP array assay

Corroborative genetic evidence for FISH results (*HER-2/neu* gene amplification, CEP7 and CEP17 polysomy) was obtained in three cases which were further studied by conventional cytogenetics and SNP arrays. One case of PAC [displaying polysomy 7 (4.37 CEP7 copies on average) and *HER-2/neu* gene amplification (*HER-2*/CEP17 ratio: 20/2.1 = 9.5], was analyzed by conventional cytogenetic analysis and showed complex cytogenetic alterations (Fig. 4) described as: 65-69,XXX,+i(1)(q10),-2,-3,add(3)(p12),add(6)(q27),+7,-8,-10,-11,add(11) (p15),add(11)(q23),-12,-13,add(14)(p11.2),-15,+16,-17,-18,-19,dd(19)(q13.4),-20,-21,-22, +mar1,+mar2,+mar3,+mar4,+mar5,+5-8mar[5]/130-138, idemx2[2]/46,XX[13].

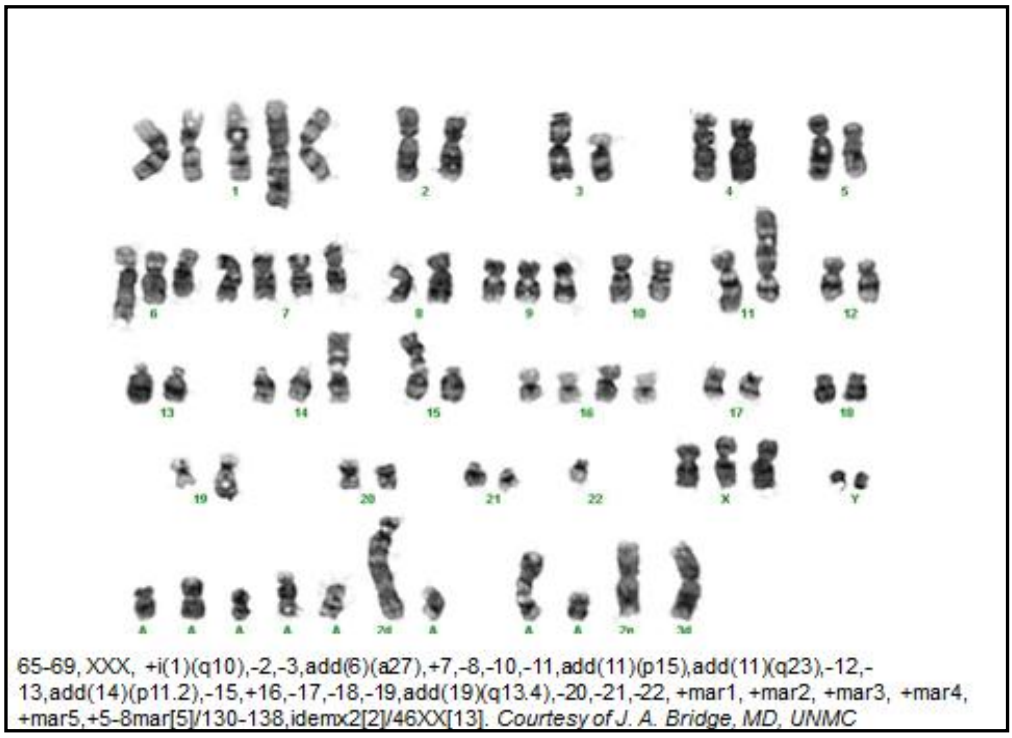

Figure 4. Conventional cytogenetics performed on a case of pure apocrine carcinoma revealed complex cytogenetic alterations including gains of chromosome 7 and loss of chromosome 17.

Another two cases [(one PAC and one ALC, both with *HER-2/neu* gene amplification] were studied by SNP arrays which confirmed FISH results and further revealed amplification of CEP17 without polysomy of chromosome 17 in the first one (Sample GLID09_0048) whereas the second one (Sample GLID09_0050) had co-amplification of *HER-2/neu* and *TOP2A* along with a gain of CEP17 (Fig. 6).

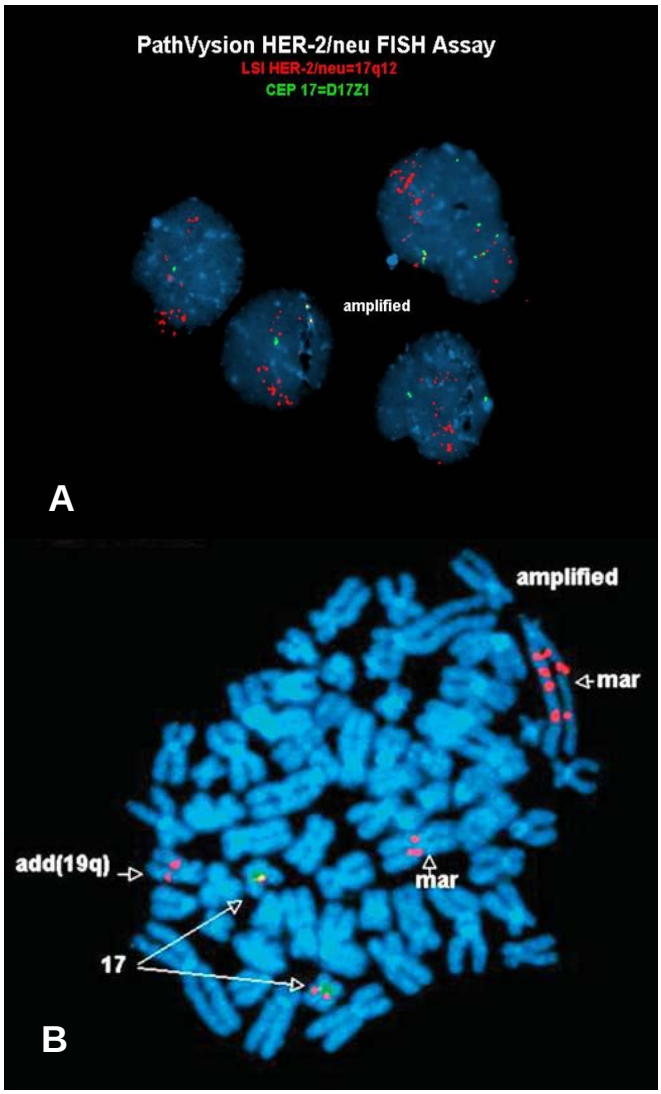

Figure 5A-B. Metaphase FISH analysis of the apocrine carcinoma showing amplification of the *HER-2/neu* gene (red).

One of the larger marker chromosomes contains homogeneously staining region (hsr) of *HER-2/neu* gene amplification.

(Courtesy of Dr. Julia Bridge, University of Nebraska Medical Center, Omaha, NE)

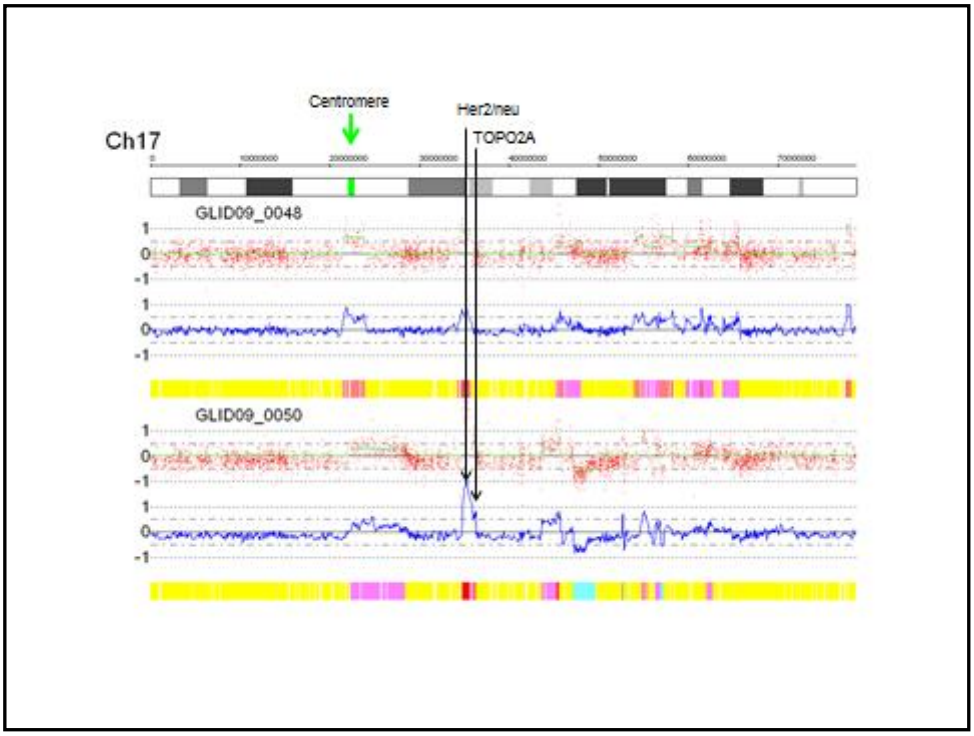

Figure 6. SNP array karyotypes of chromosome 17 for two samples with amplification of *HER-2/neu*. The first one (Sample GLID09_0048) had amplification of both CEP17 and *HER-2/neu* amplification without polysomy 17 whereas the second one (Sample GLID09_0050) had co-amplification of *HER-2/neu* and *TOP2A* genes along with a gain of CEP17.

Plots are as follows: A) The raw log2ratio of tumor/normal for each probe on the array; B) Smoothing average over 10 probes; C) Hidden Markov Model of copy number with aqua = 1, yellow = 2, pink = 3, pink-red = 4, red-pink = 5, and red >5.

4.1.5 Molecular subclassification of carcinomas with apocrine morphology

We found a statistically significant inverse correlation between EGFR and Her-2/neu expression in the PAC subgroup (p=0.006, r=-.499). Therefore, 20/37 (54%) PAC cases can be classified as HER-2-overexpressing whereas the remaining 17 cases (46%) as triple-negative breast carcinomas. Sixteen out of 17 triple-negative PACs (94.1%) overexpressed EGFR and would accordingly be classified as basal-like breast carcinomas (62) (Table 2). None of PACs fulfilled the criteria for luminal tumors (6, 7, 62).

In contrast, a large proportion of ALCs belonged to the luminal group (13/17 cases, 76.5%). Only three cases (17.6%) could be classified as triple-negative breast carcinomas and one case only as HER-2-overexpressing breast carcinoma.

Table 2. Molecular subclassification of apocrine carcinoma subtypes

Apocrine carcinoma subtype	Molecular phenotype
Pure apocrine carcinoma	**HER-2** ***(20/37, 54%)***[1] **Triple-negative** ***(17/37, 46%)*** *- Basal-like breast carcinoma** *(16/17, 94.1%)*
Apocrine-like carcinoma	**Luminal** ***(13/17, 76.5%)*** **Triple-negative** ***(3/17, 17.6%)*** *- Basal-like breast carcinoma*[2] *(2/3, 66.6%)* **HER-2** ***(1/17, 5.9%)***

[1] *HER-2/neu* gene amplification was used as a criterion.
[2] Based on EGFR protein expression (62).

4.2 Clinico-pathologic characteristics of the cohort with CEP17 polysomy

Based on the frequently observed CEP17 polysomy in apocrine carcinomas of the breast, we further investigated our databases for the frequency of CEP17 polysomy and its impact on HER-2/neu status and interpretation. We identified 72 such cases which represented approximately 12% of all HER2-tested cases in the period 2003-2007.

All but two patients were women. The patient's age ranged between 34 and 99 years (mean 58.3 years). The study included 68 primary and 4 metastatic breast carcinomas. The majority of the cases were invasive ductal carcinomas of no special type (65 cases, 90.3%). The remaining cases included three mucinous carcinomas (4.2%), one case of invasive lobular carcinoma (1.4%), one case of mammary Paget's disease in association with invasive ductal carcinoma (1.4%) and two cases of ductal carcinoma in situ (DCIS, 2.8%).

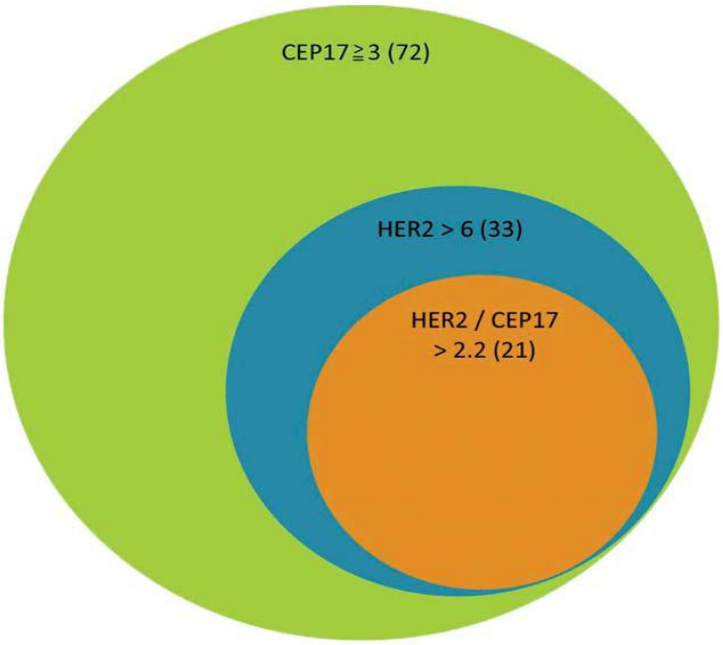

Figure 7. Euler diagram showing sub-distribution of cases of breast carcinomas with CEP17 polysomy.

4.2.1 FISH results and interpretation

The *HER-2/neu* gene and CEP17 copy number, *HER-2*/CEP17 ratio, and Her-2/neu protein expression results are summarized in Table 3 and Figure 7 (Euler diagram). Average CEP17 copy number for the cohort was 4.5 and ranged from 3.0 to 10.4 (Figure 8). *HER-2/neu* gene amplification as defined as the ratio of *HER-2*/CEP17 >2.2, was identified in twenty-one cases (29.2%). All these cases had >6 *HER-2/neu* signals per nucleus. More than 6 *HER-2/neu* copies per nucleus were observed in an additional 12 cases without an increased HER-2/CEP17 ratio, for a total of 33 cases (45.8% of all cases); using the criterion of >6 *HER-2/neu* signals per nucleus as positive for amplification, these 33 cases would be categorized as HER-2 "amplified." These findings, therefore, demonstrate that discrepant interpretation of gene amplification status was detected in 12 cases (36.4%) when the number of CEP17 copies was taken into the account. Of these 12 cases, Her-2/neu protein immunohistochemistry was available for 10 cases: 3 cases had Her-2/neu over-expression (score 3+), 6 cases had borderline score (2+) whereas one case was negative (score 1+).

Interestingly, *HER-2*/CEP17 ratios smaller than 1.0 were observed in nine cases (12.5%), of which three cases (4%) had *HER-2*/CEP17 ratio ≤ 0.7. One of these cases had a ratio of less than 0.5 (1.71 *HER-2/neu* signals and 4.06 CEP17 signals, ratio = 0.42), indicating that amplification of the centromeric region may not be accompanied by amplification of the *HER-2/neu* gene region in some cases.

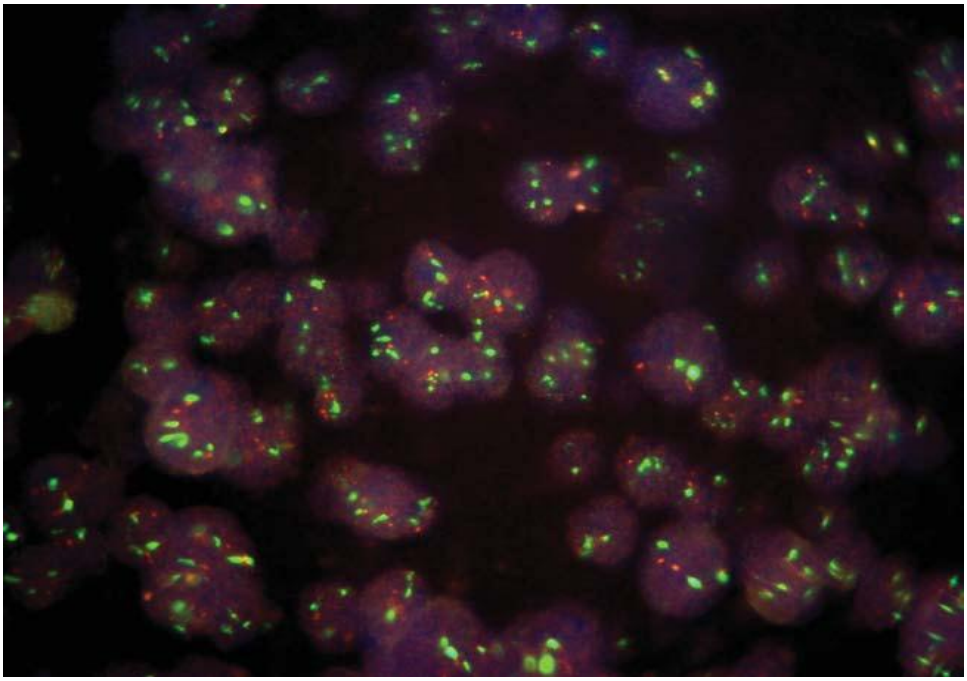

Figure 8. Dual color fluorescent in-situ hybridization assay showing multiple copies of the CEP17 (green) and the *HER-2/neu* gene (red).

Table 3. Results of the immunohistochemistry and fluorescent in situ hybridization in a cohort of 72 cases with CEP17 polysomy

***HER-2/neu* gene copy number**		***HER-2*/CEP17 ratio**	
>6 copies	33 (45.8%)	>2.2	21 (29.2%)
≤ 6 copies	39 (54.2%)	<2.2	51 (70.8%)
CEP17 copy number		**Her-2/neu protein expression**	
> 6 copies	9 (12.5%)	≥2.4 (score 3+)	22 (36.1%)
≤ 6 copies	63 (87.5%)	<2.4 (score 0-2+)	39 (63.9%)

4.2.2 SNP array karyotyping and interpretation

Cytogenomic arrays provide high resolution, genome-wide copy number information. Affymetrix 250K Nsp mapping arrays contain 250,000 probes genome-wide, including 4,854 probes on chromosome 17 and was used in 2 cases of invasive ductal carcinomas (NST) to further investigate the relationship between CEP17, *HER-2/neu* gene and other loci on chromosome 17. SNP array analysis of the first case with a FISH *HER-2*/CEP17 ratio of 0.7 (2.3/3.3), revealed that copy number variability occurring along chromosome 17 may be undetected when using one or two FISH probes to determine chromosome 17 copy number. In this case, the copy number at the CEP17 locus is 3, while that at the *HER-2/neu* locus is 2, generating a ratio of 0.67 (Figure 9). Another case with similar FISH result [*HER-2*/CEP17 ratio 0.7 (5.7/7.7)] showed discrete amplifications of both the centromeric region and the *HER-2/neu* locus along with complex cytogenetic changes that included a relative loss of 17p and a relative gain of most of 17q chromosome.

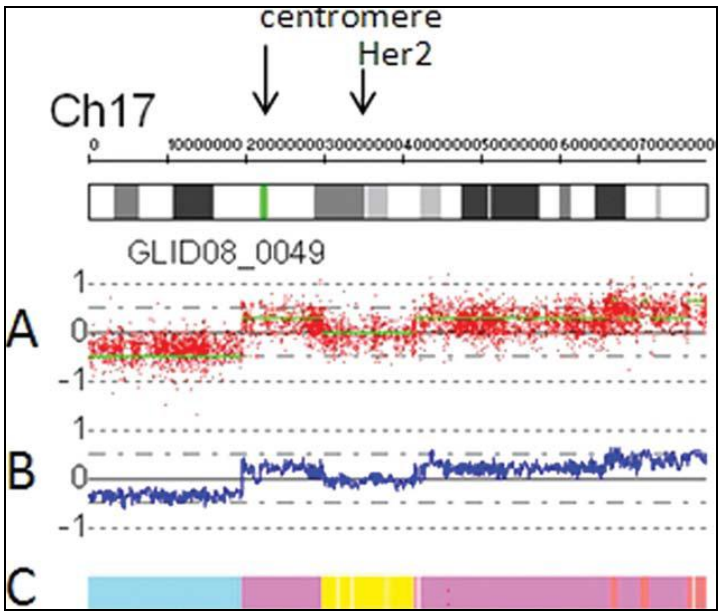

Figure 9. SNP array karyotype of chromosome 17 demonstrating the copy number variability along the length of the chromosome.

Plot descriptions, A) Raw log2ratio of the tumor/normal for each SNP probe on chromosome 17. Copy number of 2 = zero. B) Log2ratio smoothed over 10 SNPs. C) Copy number Hidden Markov Model with blue = 1, yellow = 2, pink = 3, pink-red = 4, red-pink = 5, and red > 5.

4.2.3 Correlation between protein expression and HER-2/neu gene status

Her-2/neu protein expression results were available for 61 cases. 9 cases (14.8%) were negative (scores 0-1+), 30 cases (49.2%) borderline (score 2+) and 22 cases (36%) positive (score 3+).

Her-2/neu protein expression positively correlated with both *HER-2/neu* gene copy number and *HER-2*/CEP17 ratio ($p<0.01$, rs=0.56 and 0.64, respectively). A trend towards positive correlation was found between Her-2/neu protein expression and CEP17 copy number, but did not reach the statistical significance ($p=0.067$).

Notably, 6/22 cases (27.3%) with Her-2/neu protein scores of 3+ had no *HER-2/neu* gene amplification (ratio < 2.2). However, 4 out of these 6 cases harbored more than 6 copies of the *HER-2/neu* gene, fulfilling the absolute copy number criterion for *HER-2/neu* gene amplification (73). In the borderline protein expression category (score 2+), only 4 of 30 cases had *HER-2/neu* gene amplification (ratio < 2.2, 13.3%). None of the cases with score 0-1+ showed *HER-2/neu* gene amplification by FISH.

5. Discussion

The diagnosis of apocrine carcinoma of the breast has been controversial because of the lack of strict diagnostic criteria. With the increasing use of immunohistochemistry, apocrine breast cancer differentiation has shown a consistent pattern of steroid receptor expression irrespective of grade (20, 100) and this method should be applied for unequivocal definition of this special carcinoma type. With such consistency, additional correlations between the histologic phenotype and biologic potential should become more meaningful.

In this study, we applied stringent morphologic and immunohistochemical criteria to correctly classify and characterize apocrine carcinoma of the breast. Consequently, our results clearly separated breast tumors with apocrine cyto-morphology into two different groups: the pure apocrine carcinomas with consistent lack of ER and overexpression of AR, and morphologically apocrine-like carcinomas that did not exhibit the protein expression profile associated with the true apocrine phenotype (17, 18, 31, 108). Similarly, *Celis et al* using another set of morphologic and immunohistochemical criteria for classification of apocrine carcinoma defined and confirmed the existence of a distinct apocrine carcinoma group with a consistent steroid receptor profile (ER-, AR+) (20, 35, 64, 100). Together, these results strongly support the recent advances in molecular classification of breast carcinoma which have revealed the existence of a specific 'molecular apocrine' gene expression profile among ER-negative breast carcinomas characterized primarily by increased AR signaling, along with a common *Her-2/neu* gene amplification (31, 35, 64, 100). The pure apocrine carcinoma subgroup from our study seems to be equivalent to the 'molecular apocrine' group from Farmers' study although that cohort was not entirely compatible with pure apocrine carcinomas (31). Our findings showing co-expression of AR and Her-2/neu proteins in pure apocrine carcinomas also support results of other studies that highlighted a functional cross-talk and association between AR and *HER-2/neu* in a subset of breast carcinomas and breast carcinoma cell lines (36-38, 64, 66).

Pure apocrine carcinomas were further characterized by a complimentary expression of Her-2/neu and EGFR proteins. Thus, a majority of HER-2-negative cases (i.e. triple-negative apocrine carcinomas) over-expressed EGFR and accordingly could

be classified as basal-like breast carcinomas (6, 7, 61, 62, 101). These results are in line with a study of *Tsutsumi* who reported a 100% positivity rate of EGFR protein among triple-negative apocrine carcinomas of the breast (27). The author did not however explore the status of the *EGFR* gene. Similar rate of EGFR protein positivity was also recently reported by *Wen et al* (101). On the other hand, HER-2-overexpressing pure apocrine carcinomas were mostly negative for EGFR protein expression. However, those who were both HER-2/neu and EGFR positive may exhibit Trastuzumab resistance as indicated by the recent study (109).

The apocrine-like carcinomas were much more heterogeneous with various combinations of steroid receptor expression including AR. Apocrine-like carcinomas are characterized by a common ER expression and *HER-2/neu* gene amplification but significantly less common EGFR over-expression, thus mainly belonging to the luminal phenotypes (A and B) according to the molecular classification of breast carcinomas (6, 7). Notably, of the remaining four ER-negative apocrine-like carcinomas only one case had *HER-2/neu* gene amplification.

Our results suggest that a strict definition of pure apocrine carcinomas could clarify some of the previous contradictions in the classification of apocrine carcinoma (variable and heterogeneous gene expression profiles of morphologically defined apocrine tumors) that lead some investigators to challenge its existence altogether (42).

The consistent expression of androgen receptor in pure apocrine carcinomas holds promise as a potential therapeutic target (8, 110). Experimental studies showed that AR closely interferes with several important oncogenic pathways including PI3K/AKT/PTEN and Wnt pathways whose inhibition along with AR blockade results in tumor cell growth arrest (36). A recent study of *Kasashima et al* revealed that a substantial proportion of apocrine carcinomas overexpress 5-α reductase that converts testosterone into the more potent dihydrotestosterone (29). At clinical level, there are several ongoing clinical trials with antiandrogen drugs aimed to treat metastatic and ER-negative breast cancers (available at: www.clinicaltrials.gov, visited: April 5, 2012 and reference 110). These trials should result in definitive guidance in regards to the effects of these drugs in treatment of AR-positive breast cancer (110). AR status may also affect endocrine response to tamoxifen in patients with ER-positive breast cancers (111).

Epidermal growth factor receptor (EGFR) is a 170-kDa transmembrane glycoprotein encoded by the *HER-1* protooncogene, located at 7p11.2-p12 (46, 47, 112). High expression of EGFR in a variety of epithelial tumors has led to the development of a number of drugs specifically targeting the EGFR that are now in use for treatment of advanced colorectal carcinoma, non-small cell lung carcinoma (adenocarcinoma), head and neck squamous cell carcinoma, and pancreatic carcinoma (113). EGFR protein expression has also been a common finding in breast carcinoma (27), particularly in a subgroup of triple-negative, basal-like breast carcinomas (more than 50%) leading some investigators to use it as a surrogate marker for a basal-like breast carcinoma (58, 62, 67). However, *EGFR* gene alterations (activating mutations and gene amplification) tend to be a rare event in breast carcinoma and were found in less than 8% of the cases (51, 57, 58, 114). A study of *Teng et al* recently reported an 11% prevalence of EGFR gene mutations in triple-negative breast carcinomas (115). In the present study, we demonstrated EGFR protein expression in 62% of the cases. The expression pattern was predominantly strong (scores 2-3+) and diffuse (more than 50% of positive cells) in both subgroups and was not accompanied by the *EGFR* gene amplification, similar to the results of a study by *Park et al* (114).

Polysomy of chromosome 7 (*CEP7* polysomy) which we found associated with the pure apocrine carcinoma subgroup is a novel finding, not previously associated with apocrine breast cancer (116-119). It also correlated and might be responsible for the EGFR protein overexpression in the pure apocrine carcinoma. Of note, *Koletsa et al* recently reported a common *CEP7* polysomy in HER-2-positive breast cancers but without association with EGFR protein status (67). They also found no *EGFR* gene amplification in any of the cases they studied but confirmed the activation of EGFR protein through its phosphorylation (67). *CEP7* polysomy have also been observed in breast cancers with EGFR protein over-expression including triple-negative basal-like breast carcinomas (of no-special-type) as well as in some special types (e.g. metaplastic carcinoma of the breast) (56, 57, 119).

HER-2/neu status is routinely assessed in all patients with a new diagnosis of invasive breast carcinoma as it predicts a response to the targeted therapy with Trastuzumab (Herceptin ®; Genentech, South San Francisco, CA, USA) (73-77, 83). HER-2/neu status has also a prognostic value in breast cancer. Over-expression of Her-

2/neu protein has been reported in approximately 15% of invasive breast carcinomas (NST) and has been associated with a worse clinical outcome (69, 80-82, 120). In most cases, Her-2/neu overexpression can be attributed to amplification of the *HER-2/neu* gene located on the long arm of chromosome 17 (17q12) (85). Our study on apocrine carcinomas revealed *HER-2/neu* gene amplification in approximately 52% of the cases, similar to the rate of *HER-2/neu* gene amplification in invasive apocrine carcinomas of the breast observed in two previously published small cohorts (44% and 50%, references 25 and 121, respectively). The pure apocrine carcinoma subgroup exhibited slightly higher rate of *HER-2/neu* gene amplification in comparison with the apocrine-like carcinoma subgroup, but the difference was not statistically significant. This is in line with previous studies which demonstrated a strong association between *HER-2/neu* status and apocrine differentiation (26, 31, 61, 64, 100, 122). Although we found a high degree of concordance between immunohistochemistry and FISH results, four cases were negative for *HER-2/neu* gene amplification despite a high protein expression on immunohistochemistry which was previously explained by various preanalytical and analytical factors including tissue fixation, a choice of the anti-Her-2/neu antibody, and scoring system (122, 123).

Abnormalities of chromosome 17 are important genetic alterations in breast cancer as several important oncogenes, tumor suppressor genes, and DNA repair genes are located on it (124). One of the most common genetic events is aneusomy of chromosome 17, including polysomy 17 (87, 90). However, the definition of polysomy 17 is not universally accepted (74). Therefore, we followed the arbitrary cutoff of 3 or more copies of CEP17 applied in previous publications (89, 101-102). Our FISH analysis revealed CEP17 polysomy in a substantial proportion of apocrine carcinomas (33%), either as the sole finding or in combination with *HER-2/neu* gene amplification. *CEP17* polysomy without concomitant *HER-2/neu* gene amplification was seen in eight cases of which five cases had Her-2/neu protein overexpression scores 2+ and 3+. Several investigators previously considered CEP17 polysomy a potential cause of equivocal *HER-2/neu* results by FISH or immunohistochemistry (90, 101, 125). The problem may be related to the methodology and interpretation applied for the HER-2/neu analysis as the most accurate method of assessing *HER-2/neu* status is yet to be determined (73). In addition, the interpretation guidelines as given by ASCO/CAP may

give conflicting results, depending on whether the laboratory uses a single probe kit or a double probe kit (73). The most recent ASCO/CAP guidelines for *HER-2/neu* testing define *HER-2/neu* amplification by FISH as more than six *HER-2/neu* gene copies per nucleus or a ratio *HER-2/neu* gene signals to chromosome 17 (CEP17) signals of more than 2.2 (73). Although this appears rather straightforward, abnormalities of chromosome 17 in breast cancer are frequent and may include whole chromosome copy number gains (polysomy 17) or losses (monosomy 17), focal copy number gains and losses, and other structural rearrangements (88). These abnormalities of chromosome 17 can lead to discrepant interpretations of FISH data, depending on which criterion is used. The potential for such misinterpretations is significant, given that polysomy 17 is relatively common in breast carcinomas, although the reported frequency of this finding varies in the literature (88-91, 126). The discrepancy may be further complicated by different cutoff scoring systems recommended by the FDA (>10% of positive tumor cells with score 3+ on IHC or HER-2/CEP17 ratio > 2 on FISH) and ASCO/CAP (>30% of positive tumors cells on IHC or HER-2/CEP17 ratio > 2.2 on FISH) (103, 126).

In a recently published series by *Vanden Bempt et al*, more than 40% of breast carcinomas were found to harbor increased CEP17 copy number (89). In addition, increased CEP17 copy number is frequently found in tumors showing Her-2/neu over-expression, including those with a borderline (2+) score, as confirmed in our study on both apocrine carcinoma and invasive ductal carcinoma of NST (101, 127, 128). Our series included unselected (no prior immunohistochemical determination of Her-2/neu protein) and selected (equivocal IHC staining results) cases, reflecting CML's referral laboratory's mixture of cases received from differing institutions.

Our study on invasive ductal carcinomas (NST) with CEP17 polysomy indicates that determination of *HER-2/neu* amplification status may show discordant results, depending on whether CEP17 copy number was taken into account. Indeed, more than 1/3 of the studied invasive ductal carcinomas (NST) harboring more than 6 copies of the *HER-2/neu* gene did not show *HER-2/neu* gene amplification (ratio>2.2). Importantly, a majority of these cases had a borderline score (2+) on IHC, thus being not amenable for the targeted therapy. Similarly, increased CEP17 copy number appears to contribute to the discordant results between protein expression and gene amplification (IHC 3+/FISH

negative), since 6 out of 22 cases (27%) with a 3+ result on immunohistochemistry did not show a *HER-2*/CEP17 ratio >2.2. Notably, 4 of 6 cases demonstrated greater than 6 copies of the *HER-2* gene. Therefore, these cases did not fit within the *HER-2*-amplified breast carcinoma category (102, 129). Taken together, a subgroup of borderline (2+) breast carcinomas represented a majority of the cases with increased CEP17 copy number in our study and only 13% of the cases showed *HER-2/neu* gene amplification. This finding is in line with previous studies that confirmed that breast cancers with an equivocal IHC score (2+) harbored CEP17 polysomy instead of *HER-2/neu* gene amplification (101, 130, 131). In contrast, *Panvichian et al* reported no effects of isolated CEP17 polysomy on Her-2/neu protein expression (132).

We point out here that the term "polysomy 17" is commonly used when there is an increase in CEP17 signals by FISH. However, FISH analysis is a targeted assay and cannot assess the copy number of an entire chromosome. An increased number of CEP17 signals may represent a focal gain in the centromeric region of chromosome 17 rather than a true polysomy 17 (77, 80, 83, 92, 93, 94, 125), and our whole genome analysis using SNP arrays in both invasive apocrine carcinoma and invasive ductal carcinoma (NST) also supports this observation. Affymetrix 250K *Nsp* mapping arrays contain 4,854 probes on chromosome 17. By generating a SNP array karyotype, one can discern between true polysomy 17 and focal gain of CEP17. Our re-analysis of published data (GEO dataset record GSE10099) revealed that true polysomy of chromosome 17 is a rare event, present in 1% of all analyzed cases (133). Most increases in CEP17 copy number by FISH are due to focal gains rather than true polysomy 17. *Vanden Bempt et al* also found neither increased Her-2/neu protein nor increased *HER-2 mRNA* in CEP17 polysomy cases and concluded that the tumors displaying unamplified CEP17 polysomy probably represented more Her-2/neu-negative than HER-2-positive breast carcinomas (89). Some other investigators questioned also the interpretation of the *CEP17* copy number as a reliable predictor of the entire chromosome 17 polysomy (90, 92, 93, 94, 125, 134). Instead of, these investigators used the alternative chromosome 17 reference genes (e.g. MED1, STARD3, GRB7, TOP2A, RARA) (80, 95). These studies also confirmed that true polysomy 17 in breast cancer is uncommon and revealed novel predictors of outcome in patients with HER-2-positive breast carcinomas (80). Notably, a study of *Lamy et al*

revealed the key role of *HER-2/neu* gene in genomic instability along chromosome 17q (80). Taken together, we prefer the term CEP17 polysomy and find the term "polysomy 17" as a potential misnomer.

Interestingly, CEP17 copy number may have a predictive therapeutic value; increased CEP17 copy number along with TOP2A status appear to be a predictive marker for anthracycline-based chemotherapy in breast cancer (135-137). However, a recent study of *Pritchard et al* on a larger series of node positive breast carcinomas showed a borderline association of CEP17 duplication with clinical responsiveness to anthracycline-based chemotherapy (138).

Similar to gains in CEP17 copy number as seen on FISH testing, deletions of the CEP17 copy number do not necessarily correlate with deletion of the entire chromosome. In a previous study by *Tubbs et al*, monoallelic deletion of the *HER-2/neu* gene (*HER-2*/CEP17≤0.7) was demonstrated in 2% (12/742) of breast carcinomas (139). We likewise found deletion of the *HER-2/neu* gene in a subset of invasive ductal carcinomas (NST) with "polysomy" 17 (3/72, 4%) while six cases of apocrine carcinomas had fewer *HER-2/neu* signals per cell than CEP17 signals (ratio: 0.72-0.99). Conventional cytogenetics performed on a case of PAC with *HER-2/neu* gene amplification also revealed a loss of chromosome 17 (Figure 4). *HER-2/neu* gene deletion can also be associated with simultaneous loss of the *TOP2A* gene (140).

6. Conclusions

- Breast carcinomas with apocrine differentiation are heterogeneous in molecular terms. The combination of morphologic and immunohistochemical criteria are essential for the proper identification of pure apocrine carcinomas. When strictly defined, these carcinomas express either Her-2/neu or EGFR in a nearly exclusive manner, resulting in their classification as either HER-2-overexpressing or triple-negative types of breast carcinomas. In contrast, apocrine-like carcinomas predominantly belong to the luminal molecular phenotype (both A and B).
- *EGFR* and *HER-2/neu* play important roles in the pathogenesis of apocrine carcinomas and these findings may have significant therapeutic implications. *HER-2/neu* gene amplification is the primary mechanism of Her-2/neu protein over-expression. Amplification of the *EGFR* gene is rarely seen in invasive apocrine carcinoma of the breast. Instead of CEP7 polysomy was frequently observed and weakly correlated with EGFR protein expression.
- A consistent AR expression in pure apocrine carcinomas could also have a potential therapeutic impact.
- *CEP17* polysomy is a common finding in invasive mammary carcinoma (both apocrine and non-apocrine type) and is not necessarily associated with *HER-2/neu* gene amplification. CEP17 polysomy is not a good surrogate for the status of the entire chromosome 17 and therefore the term “polysomy 17” should be avoided.
- *CEP17* polysomy may be associated with an equivocal (2+) score on immunohistochemistry. It can lead to discrepant interpretations depending on which criterion for the interpretation was used: *HER-2*/CEP17 ratio *versus* absolute *HER-2/neu* gene copy. However, positive gene dosage (>6 *HER-2/neu* genes or *HER-2*/CEP17 ratio>2.2), regardless of the evaluation method used, is positively correlated with Her-2/neu protein expression. As a result of our findings, we propose that the average number of *HER-2/neu* genes per nucleus be reported alongside the average *HER-2*/CEP17 ratio and Her-2/neu protein status, in order to accurately identify all patients eligible for trastuzumab treatment.

7. Summary

The study was undertaken to investigate EGFR and HER-2/neu expression in a cohort of apocrine carcinomas of the breast with emphasis on the classification of the breast carcinomas with apocrine morphology. In total, 55 breast carcinomas morphologically diagnosed as apocrine were evaluated for steroid receptor expression profile characteristic of normal apocrine epithelium (ER-/PR-/AR+), and for the expression of EGFR and Her-2/neu proteins, and the copy number ratios of the genes *EGFR*/CEP7 and *HER-2*/CEP17. Another cohort composed of 72 invasive ductal carcinomas of no-special-type was used to further determine the impact of CEP17 polysomy on the interpretation of *HER-2/neu* testing.

Our study confirms that apocrine carcinomas of the breast are molecularly diverse group of carcinomas. Strictly defined, pure apocrine carcinomas (ER-, PR-, AR+) (38 cases, 69%) are either HER-2 overexpressing breast carcinomas (52%) or triple-negative breast carcinomas (48%). Apocrine-like carcinomas (ER+/-, PR+/-, AR+/-) (17 cases, 31%) belong predominantly to the luminal phenotype (76%).

Pure apocrine carcinomas show consistent over-expression of either EGFR or Her-2/neu. *EGFR* gene amplification was observed in two pure apocrine carcinomas and one apocrine-like carcinoma. CEP7 polysomy (defined as three or more CEP7 signals) was seen in 61% pure apocrine carcinomas and 27% of apocrine-like carcinomas and showed a weak positive correlation with EGFR protein expression.

HER-2/neu gene amplification is the primary mechanism of Her-2/neu activation and is found in 52% of all apocrine carcinomas. CEP17 polysomy (defined as three or more CEP17 signals) was observed in 10 pure apocrine carcinomas (32%) and 8 apocrine-like carcinomas (50%).

CEP17 polysomy may be seen without *HER-2/neu* gene amplification. Further exploration on a cohort of invasive ductal carcinomas of no-special-type confirmed that increased CEP17 signals may lead to discordant interpretation of *HER-2/neu* gene amplification in a significant proportion of the cases, depending on which criterion (ratio versus absolute number) is used for interpretation. However, increased gene dosage (>6 *HER-2/neu* genes or *HER-2*/CEP17 ratio>2.2), regardless of the evaluation method, is positively correlated with Her-2/neu protein expression.

8. Sažetak

Cilj istraživanja je bio ispitati ekspresiju EGFR i Her-2/neu proteina u skupini apokrinih karcinoma dojke s posebnim osvrtom na klasifikaciju karcinoma dojke s apokrinom morfologijom. Ukupno 55 karcinoma dojke s apokrinom morfologijom testirano je na karakteristični profil steroidnih receptora koji se susreće kod normalnog apokrinog epitela (ER-/PR-/AR+), ekspresiju Her-2/neu i EGFR proteina, te broj kopija i odnos HER-2/CEP17 i EGFR/CEP7. Dodatna skupina sastavljena od 72 karcinoma dojke (opći tip) poslužila je za daljnje ispitivanje utjecaja polisomije CEP17 na status i interpretaciju HER-2/neu gena.

Rezultati istraživanja pokazuju da su apokrini karcinomi dojke molekularno heterogena skupina tumora. Striktno definirani, tzv. čisti apokrini karcinomi (ER-/PR-/AR+) (38 slučajeva, 69%) su ili HER-2 pozitivni (52%) ili "trostruko-negativni" karcinomi (48%). "Apocrine-like" karcinomi dojke (ER+/-, PR+/-, AR+/-) (17 slučajeva, 31%) pripadaju pretežno luminalnom fenotipu (76%).

Čisti apokrini karcinomi pokazuju konzistentnu ekspresiju ili EGFR ili HER-2/neu. Amplifikacija *EGFR* gena je bila utvrđena kod 2 čista apokrina i jednog „apocrine-like" karcinoma dojke. Polisomija CEP7 (definirana kao tri i više CEP7 signala) je bila prisutna kod 61% čistih apokrinih i 27% „apocrine-like" karcinoma dojke. Polisomija CEP7 je pokazivala statistički slabu pozitivnu korelaciju s ekspresijom EGFR proteina.

Amplifikacija *HER-2/neu* gena je osnovni mehanizam aktivacije Her-2/neu proteina i pronađena je kod 52% svih apokrinih carcinoma. Polisomija CEP17 (definirana kao tri ili više CEP17 kopija) je bila prisutna kod 10 čistih apokrinih karcinoma (32%) i 8 „apocrine-like" karcinoma dojke (50%).

Polisomija CEP17 se može javiti i bez amplifikacije *HER-2/neu* gena. Daljnja analiza utjecaja polisomije CEP17 na kohorti invazivnih karcinoma dojke (opći tip) potvrdila je da povećani broj CEP17 signala može utjecati na proturječnu interpretaciju amplifikacije *HER-2/neu* gena kod signifikantnog broja karcinoma dojke, ovisno koji kriterij za interpretaciju se primjenjuje (odnos *HER-2*/CEP17 naspram apsolutnog broja kopija *HER-2/neu* gena). Ipak, povećana količina gena (>6 kopija *HER-2/neu* gena ili

odnos *HER-2*/CEP17>2.2), bez obzira na način interpretiranja je pozitivno korelirala s ekspresijom Her-2/neu proteina.

9. References

1. Key TJ, Verkasalo PK, Banks E. Epidemiology of breast cancer. Lancet Oncol 2001;2:133-140.
2. Schnitt SJ, Collins LC. Biopsy interpretation of the breast. Philadelphia: Lippincott Williams & Wilkins; 2009.
3. Badve S, Dabbs DJ, Schnitt SJ, et al. Basal-like and triple-negative breast cancers: a critical review with an emphasis on the implications for pathologists and oncologists. Mod Pathol 2011;24:157-167.
4. Tavassoli FA, Devilee P (eds.) World Health Organization Classification of tumours. Pathology and genetics of tumours of the breast and female genital organs. Lyon: IARC Press; 2003.
5. Reis-Filho JS, Pusztai L. Gene expression profiling in breast cancer: classification, prognostication, and prediction. Lancet 2011;378:1812-1823.
6. Sørlie T, Perou CM, Tibshirani R, et al. Gene expression patterns of breast carcinomas distinguish tumor subclasses with clinical implications. Proc Natl Acad Sci U S A 2001;98:10869-10874.
7. Perou CM, Sørlie T, Eisen MB, et al. Molecular portraits of human breast tumours. Nature 2000;406:747-752.
8. Gerhard R, Costa JL, Schmitt F. Benign and malignant apocrine lesions of the breast. Expert Rev Anticancer Ther 2012;12:215-221.
9. Iggo RD. New insights into the role of androgen and oestrogen receptors in molecular apocrine breast tumours. Breast Cancer Res 2011;13:318.
10. Wells CA, El-Ayat GA. Non-operative breast pathology: apocrine lesions. J Clin Pathol 2007;60:1313-1320.
11. Elayat G, Selim AG, Wells CA. Cell turnover in apocrine metaplasia and apocrine adenosis of the breast. Ann Diagn Pathol 2010;14:1-7.
12. Masood S, Rosa M. The challenge of apocrine proliferations of the breast: a morphologic approach. Pathol Res Pract 2009;205:155-164.

13. Fuehrer N, Hartmann L, Degnim A, et al. Atypical apocrine adenosis of the breast: long-term follow-up in 37 patients. Arch Pathol Lab Med 2012;136:179-182.
14. O'Malley FP, Bane A. An update on apocrine lesions of the breast. Histopathology 2008;52:3-10.
15. Celis JE, Gromova I, Gromov P, et al. Molecular pathology of breast apocrine carcinomas: a protein expression signature specific for benign apocrine metaplasia. FEBS Lett 2006;580:2935-2944.
16. Banneau G, Guedj M, MacGrogan G, et al. Molecular apocrine differentiation is a common feature of breast cancer in patients with germline PTEN mutations. Breast Cancer Res 2010;12:R63.
17. Gatalica Z. Immunohistochemical analysis of apocrine breast lesions. Consistent over-expression of androgen receptor accompanied by the loss of estrogen and progesterone receptors in apocrine metaplasia and apocrine carcinoma in situ. Pathol Res Pract 1997;193:753-758.
18. Tavassoli FA, Purcell CA, Bratthauer GL, et al. Androgen receptor expression along with loss of bcl-2, ER, and PR expression in benign and malignant apocrine lesions of the breast: implications for therapy. Breast J 1996;2:261–269.
19. Leal C, Henrique R, Monteiro P, et al. Apocrine ductal carcinoma in situ of the breast: histologic classification and expression of biologic markers. Hum Pathol 2001;32:487-493.
20. Celis JE, Cabezon T, Moreira JM, et al. Molecular characterization of apocrine carcinoma of the breast: Validation of an apocrine protein signature in a well-defined cohort. Mol Oncol 2009;3:220-237.
21. Nicolás Díaz-Chico B, Germán Rodríguez F, González A, et al. Androgens and androgen receptors in breast cancer. J Steroid Biochem Mol Biol 2007;105:1-15.
22. Isola JJ. Immunohistochemical demonstration of androgen receptor in breast cancer and its relationship to other prognostic factors. J Pathol 1993;170:31-35.
23. Collins LC, Cole KS, Marotti JD, Hu R, Schnitt SJ, Tamimi RM. Androgen receptor expression in breast cancer in relation to molecular phenotype: results from the Nurses' Health Study. Mod Pathol 2011;24:924-931.

24. Bratthauer GL, Lininger RA, Man YH, Tavassoli FA. Androgen and estrogen receptor mRNA status in apocrine carcinomas. Diagn Mol Pathol 2002;11:113-118.
25. Moinfar F, Okcu M, Tsybrovskyy O, et al. Androgen receptors frequently are expressed in breast carcinomas. Cancer 2003;98:703-711.
26. Niemeier LA, Dabbs DJ, Beriwal S, Striebel JM, Bhargava R. Androgen receptor in breast cancer: expression in estrogen receptor-positive tumors and in estrogen receptor-negative tumors with apocrine differentiation. Mod Pathol 2010;23:205-212.
27. Tsutsumi Y. Apocrine Carcinoma as Triple-negative Breast Cancer: Novel Definition of Apocrine-type Carcinoma as Estrogen/Progesterone Receptor-negative and Androgen Receptor-positive Invasive Ductal Carcinoma. Jpn J Clin Oncol 2012;42: 375-386.
28. Miller WR, Telford J, Dixon JM, Shivas AA. Androgen metabolism and apocrine differentiation in human breast cancer. Breast Cancer Res Treat 1985;5:67-73.
29. Kasashima S, Kawashima A, Ozaki S, Nakanuma Y. Expression of 5α-reductase in apocrine carcinoma of the breast and its correlation with clinicopathological aggressiveness. Histopathology 2012;60(6B):E51-57.
30. Suzuki T, Miki Y, Takagi K, et al. Androgens in human breast carcinoma. Med Mol Morphol 2010;43:75-81.
31. Farmer P, Bonnefoi H, Becette V, et al. Identification of molecular apocrine breast tumours by microarray analysis. Oncogene 2005;24:4660-4671.
32. Doane AS, Danso M, Lal P, et al. An estrogen receptor-negative breast cancer subset characterized by a hormonally regulated transcriptional program and response to androgen. Oncogene 2006;25:3994-4008.
33. Kreike B, van Kouwenhove M, Horlings H, et al. Gene expression profiling and histopathological characterization of triple-negative/basal-like breast carcinomas. Breast Cancer Res 2007;9:404.
34. Sanga S, Broom BM, Cristini V, Edgerton ME. Gene expression meta-analysis supports existence of molecular apocrine breast cancer with a role for androgen

receptor and implies interactions with ErbB family. BM Med Genomics 2009;2:59.

35. Guedj M, Marisa L, de Reynies A, et al. A refined molecular taxonomy of breast cancer. Oncogene 2012;31:1196-1206.
36. Ni M, Chen Y, Lim E, et al. Targeting androgen receptor in estrogen receptor-negative breast cancer. Cancer Cell 2011;20:119-131.
37. Naderi A, Hughes-Davies L. A functionally significant cross-talk between androgen receptor and erbB2 pathways in estrogen receptor negative breast cancer. Neoplasia 2008;10:542-548.
38. Chia KM, Liu J, Francis GD, Naderi A. A feedback loop between androgen receptor and ERK signaling in estrogen receptor-negative breast cancer. Neoplasia 2011;13:154-166.
39. Naderi A, Liu J. Inhibition of androgen receptor and Cdc25A phosphatase as a combination targeted therapy in molecular apocrine breast cancer. Cancer Lett 2010;298:74-87.
40. Naderi A, Chia KM, Liu J. Synergy between inhibitors of androgen receptor and MEK has therapeutic implications in estrogen receptor-negative breast cancer. Breast Cancer Res 2011;13:R36.
41. Wang Y, Romigh T, He X, et al. Differential regulation of PTEN expression by androgen receptor in prostate and breast cancers. Oncogene 2011;30:4327-4338.
42. Weigelt B, Horlings HM, Kreike B, et al. Refinement of breast cancer classification by molecular characterization of histological special types. J Pathol 2008;216:141-150.
43. Kaya H, Bozkurt SU, Erbarut I, Djamgoz MB. Apocrine carcinomas of the breast in Turkish women: hormone receptors, c-erbB-2 and p53 immunoexpression. Pathol Res Pract 2008;204:367-371.
44. Matsuo K, Fukutomi T, Hasegawa T, Akashi-Tanaka S, Nanasawa T, Tsuda H. Histological and immunohistochemical analysis of apocrine breast carcinoma. Breast Cancer 2002;9:43-49.
45. Chan SK, Hill ME, Gullick WJ. The role of the epidermal growth factor receptor in breast cancer. J Mammary Gland Biol Neoplasia 2006;11:3-11.

46. Foley J, Nickerson NK, Nam S, et al. EGFR signaling in breast cancer: bad to the bone. Semin Cell Dev Biol 2010;21:951-960.
47. Burness ML, Grushko TA, Olopade OI. Epidermal growth factor receptor in triple-negative and basal-like breast cancer: promising clinical target or only a marker? Cancer J 2010;16:23-32.
48. Normanno N, De Luca A, Bianco C, et al. Epidermal growth factor receptor (EGFR) signaling in cancer. Gene 2006;366:2-16.
49. Real FX, Rettig WJ, Chesa PG, Melamed MR, Old LJ, Mendelsohn J. Expression of epidermal growth factor receptor in human cultured cells and tissues: relationship to cell lineage and stage of differentiation. Cancer Res 1986;46:4726-4731.
50. Del Vecchio CA, Jensen KC, Nitta RT, Shain AH, Giacomini CP, Wong AJ. Epidermal Growth Factor Receptor Variant III Contributes to Cancer Stem Cell Phenotypes in Invasive Breast Carcinoma. Cancer Res 2012;72:2657-2671.
51. Bhargava R, Gerald WL, Li AR, et al. EGFR gene amplification in breast cancer: correlation with epidermal growth factor receptor mRNA and protein expression and HER-2 status and absence of EGFR-activating mutations. Mod Pathol 2005;18:1027-1033.
52. Jacot W, Lopez-Crapez E, Thezenas S, et al. Lack of EGFR-activating mutations in European patients with triple-negative breast cancer could emphasise geographic and ethnic variations in breast cancer mutation profiles. Breast Cancer Res 2011;13:R133.
53. Generali D, Leek R, Fox SB, et al. EGFR mutations in exons 18-21 in sporadic breast cancer. Ann Oncol 2007;18:203-205.
54. Uramoto H, Shimokawa H, Nagata Y, Ono K, Hanagiri T. EGFR-activating mutations are not present in breast tumors of Japanese patients. Anticancer Res 2010;30:4219-4222.
55. Lv N, Xie X, Ge Q, et al. Epidermal growth factor receptor in breast carcinoma: association between gene copy number and mutations. Diagn Pathol 2011;6:118.
56. Shao MM, Zhang F, Meng G, et al. Epidermal growth factor receptor gene amplification and protein overexpression in basal-like carcinoma of the breast. Histopathology 2011;59:264-273.

57. Martin V, Botta F, Zanellato E, et al. Molecular characterization of EGFR and EGFR-downstream pathways in triple negative breast carcinomas with basal like features. Histol Histopathol 2012;27:785-792.
58. Nakajima H, Ishikawa Y, Furuya M, et al. Protein expression, gene amplification, and mutational analysis of EGFR in triple-negative breast cancer. Breast Cancer 2012 Apr 6. [Epub ahead of print]
59. Rakha EA, El-Sayed ME, Green AR, Paish EC, Lee AH, Ellis IO. Breast carcinoma with basal differentiation: a proposal for pathology definition based on basal cytokeratin expression. Histopathology 2007;50:434-438.
60. Silva E, Gatalica Z, Snyder C, Vranic S, Lynch JF, Lynch HT. Hereditary breast cancer: part II. Management of hereditary breast cancer: implications of molecular genetics and pathology. Breast J 2008;14:14-24.
61. Rydén L, Jirström K, Haglund M, Stål O, Fernö M. Epidermal growth factor receptor and vascular endothelial growth factor receptor 2 are specific biomarkers in triple-negative breast cancer. Results from a controlled randomized trial with long-term follow-up. Breast Cancer Res Treat 2010;120:491-498.
62. Nielsen TO, Hsu FD, Jensen K, et al. Immunohistochemical and clinical characterization of the basal-like subtype of invasive breast carcinoma. Clin Cancer Res 2004;10:5367-5374.
63. Gumuskaya B, Alper M, Hucumenoglu S, Altundag K, Uner A, Guler G. EGFR expression and gene copy number in triple-negative breast carcinoma. Cancer Genet Cytogenet 2010;203:222-229.
64. Bhargava R, Beriwal S, Striebel JM, Dabbs DJ. Breast cancer molecular class ERBB2: preponderance of tumors with apocrine differentiation and expression of basal phenotype markers CK5, CK5/6, and EGFR. Appl Immunohistochem Mol Morphol 2010;18:113-118.
65. Feuerhake F, Unterberger P, Höfter EA. Cell turnover in apocrine metaplasia of the human mammary gland epithelium: apoptosis, proliferation, and immunohistochemical detection of Bcl-2, Bax, EGFR, and c-erbB2 gene products. Acta Histochem 2001;103:53-65.

66. Vranic S, Gatalica Z, Wang ZY. Update on the molecular profile of the MDA-MB-453 cell line as a model for apocrine breast carcinoma studies. Oncol Lett 2011;2:1131-1137.
67. Koletsa T, Kotoula V, Karayannopoulou G, et al. EGFR expression and activation are common in HER2 positive and triple-negative breast tumours. Histol Histopathol 2010;25:1171-1179.
68. Akiyama T, Sudo C, Ogawara H, Toyoshima K, Yamamoto T. The product of the human c-erbB-2 gene: a 185-kilodalton glycoprotein with tyrosine kinase activity. Science 1986;232:1644-1646.
69. Allred DC. Issues and updates: evaluating estrogen receptor-alpha, progesterone receptor, and HER2 in breast cancer. Mod Pathol 2010;23 Suppl 2:S52-59.
70. Harari D, Yarden Y. Molecular mechanisms underlying ErbB2/HER2 action in breast cancer. Oncogene 2000;19:6102-6114.
71. Gullick WJ, Srinivasan R. The type 1 growth factor receptor family: new ligands and receptors and their role in breast cancer. Breast Cancer Res Treat 1998;52:43-53.
72. Ménard S, Tagliabue E, Campiglio M, Pupa SM. Role of HER2 gene overexpression in breast carcinoma. J Cell Physiol 2000;182:150-162.
73. Wolff AC, Hammond ME, Schwartz JN, et al. American Society of Clinical Oncology/College of American Pathologists guideline recommendations for human epidermal growth factor receptor 2 testing in breast cancer. J Clin Oncol 2007;25:118-145.
74. Nahta R, Esteva FJ. HER2 therapy: molecular mechanisms of trastuzumab resistance. Breast Cancer Res 2006;8:215.
75. Nahta R, Yu D, Hung MC, Hortobagyi GN, Esteva FJ. Mechanisms of disease: understanding resistance to HER2-targeted therapy in human breast cancer. Nat Clin Pract Oncol 2006;3:269-280.
76. De P, Smith BR, Leyland-Jones B. Human epidermal growth factor receptor 2 testing: where are we? J Clin Oncol 2010;28:4289-4292.
77. Moelans CB, van Diest PJ. Re. How do you tell whether a breast cancer is HER2 positive? Ongoing studies keep debate in high gear. J Natl Cancer Inst 2011;103:698-699.

78. Carter P, Presta L, Gorman CM, et al. Humanization of an anti-p185HER2 antibody for human cancer therapy. Proc Natl Acad Sci U S A 1992;89:4285-4289.
79. Awada A, Bozovic-Spasojevic I, Chow L. New therapies in HER2-positive breast cancer: A major step towards a cure of the disease? Cancer Treat Rev 2012;38:494-504.
80. Lamy PJ, Fina F, Bascoul-Mollevi C, et al. Quantification and clinical relevance of gene amplification at chromosome 17q12-q21 in human epidermal growth factor receptor 2-amplified breast cancers. Breast Cancer Res 2011;13:R15.
81. Baehner FL, Achacoso N, Maddala T, et al. Human epidermal growth factor receptor 2 assessment in a case-control study: comparison of fluorescence in situ hybridization and quantitative reverse transcription polymerase chain reaction performed by central laboratories. J Clin Oncol 2010;28:4300-4306.
82. Susini T, Bussani C, Marini G, et al. Preoperative assessment of HER-2/neu status in breast carcinoma: the role of quantitative real-time PCR on core-biopsy specimens. Gynecol Oncol 2010;116:234-239.
83. Moelans CB, de Weger RA, Van der Wall E, van Diest PJ. Current technologies for HER2 testing in breast cancer. Crit Rev Oncol Hematol 2011;80:380-392.
84. Bravaccini S, Rengucci C, Medri L, Zoli W, Silvestrini R, Amadori D. Detection of HER2 and Topo 2 in breast cancers: comparison between MLPA and FISH approaches. J Clin Pathol 2012;65:183-185.
85. Sauter G, Lee J, Bartlett JM, Slamon DJ, Press MF. Guidelines for human epidermal growth factor receptor 2 testing: biologic and methodologic considerations. J Clin Oncol 2009;27:1323-1333.
86. Bartlett J, Going J, Mallon E, et al. Evaluating HER2 amplification and overexpression in breast cancer. J Pathol 2001;195:422-428.
87. Watters AD, Going JJ, Cooke TG, et al. Chromosome 17 aneusomy is associated with poor prognostic factors in invasive breast carcinoma. Breast Cancer Res Treat 2003;77: 109-114.
88. Reinholz MM, Bruzek AK, Visscher DW, et al. Breast cancer and aneusomy 17: implications for carcinogenesis and therapeutic response. Lancet Oncol 2009;10:267-277.

89. Vanden Bempt I, Van Loo P, Drijkoningen M, et al. Polysomy 17 in breast cancer: clinicopathologic significance and impact on HER-2 testing. J Clin Oncol 2008;26:4869-4874.
90. Yeh IT, Martin MA, Robetorye RS, et al. Clinical validation of an array CGH test for HER2 status in breast cancer reveals that polysomy 17 is a rare event. Mod Pathol 2009;22:1169-1175.
91. Wang S, Saboorian H, Frenkel EP, et al. Aneusomy 17 in breast cancer: Its role in HER-2/neu protein expression and implication for clinical assessment of HER-2/neu status. Mod Pathol 2002;15:137-145.
92. Moelans CB, de Weger RA, van Diest PJ. Absence of chromosome 17 polysomy in breast cancer: analysis by CEP17 chromogenic in situ hybridization and multiplex ligation-dependent probe amplification. Breast Cancer Res Treat 2010;120:1-7.
93. Moelans CB, Reis-Filho JS, van Diest PJ. Implications of rarity of chromosome 17 polysomy in breast cancer. Lancet Oncol 2011;12:1087-1089.
94. Marchiò C, Lambros MB, Gugliotta P, et al. Does chromosome 17 centromere copy number predict polysomy in breast cancer? A fluorescence in situ hybridization and microarray-based CGH analysis. J Pathol 2009;219:16-24.
95. Tse CH, Hwang HC, Goldstein LC, et al. Determining true HER2 gene status in breast cancers with polysomy by using alternative chromosome 17 reference genes: implications for anti-HER2 targeted therapy. J Clin Oncol 2011;29:4168-4174.
96. Koutras AK, Fountzilas G, Kalogeras KT, Starakis I, Iconomou G, Kalofonos HP. The upgraded role of HER3 and HER4 receptors in breast cancer. Crit Rev Oncol Hematol 2010;74:73-78.
97. Edge SB, Byrd DR. AJCC Cancer Staging Manual. 7th edn. Berlin: Springer; 2010.
98. Elston CW, Ellis IO. Pathological prognostic factors in breast cancer. I. The value of histological grade in breast cancer: experience from a large study with long-term follow-up. Histopathology 1991;19:403-410.

99. Honma N, Sakamoto G, Akiyama F, et al. Breast carcinoma in women over the age of 85: distinct histological pattern an androgen, oestrogen, and progesterone receptor status. Histopathology 2003;42:120-127.
100. Niemeier LA, Dabbs DJ, Beriwal S, Striebel JM, Bhargava R. Androgen receptor in breast cancer: expression in estrogen receptor-positive tumors and in estrogen receptor-negative tumors with apocrine differentiation. Mod Pathol 2010;23:205-212.
101. Wen YH, Ho A, Patil S, et al. Id4 protein is highly expressed in triple-negative breast carcinomas: possible implications for BRCA1 downregulation. Breast Cancer Res Treat 2012 Apr 27. [Epub ahead of print]
102. Krishnamurti U, Hammers JL, Atem FD, Storto PD, Silverman JF. Poor prognostic significance of unamplified chromosome 17 polysomy in invasive breast carcinoma. Mod Pathol 2009;22:1044-1048.
103. Varshney D, Zhou YY, Geller SA, Alsabeh R. Determination of HER-2 status and chromosome 17 polysomy in breast carcinomas comparing HercepTest and PathVysion FISH assay. Am J Clin Pathol 2004;121:70-77.
104. Brunelli M, Manfrin E, Martignoni G, et al. Genotypic intratumoral heterogeneity in breast carcinoma with HER2/neu amplification: evaluation according to ASCO/CAP criteria. Am J Clin Pathol 2009;131:678-682.
105. Shaffer LG, Tommerup N. ISCN 2005 An International System for Human Cytogenetics Nomenclature. Basel: Karger; 2005.
106. Lyons-Weiler M, Hagenkord J, Sciulli CM, Dhir R, Monzon FA. Optimization of the Affymetrix GeneChip mapping 10 K 2.0 assay for routine clinical use on formalin fixed paraffin embedded tissues. Diagn Mol Pathol 2008;17:3-13.
107. Monzon FA, Hagenkord J, Lyons-Weiler M, et al. Whole genome SNP arrays as a potential diagnostic tool for the detection of characteristic chromosomal aberrations in renal epithelial tumors. Mod Pathol 2008;21:599-608.
108. Moe RE, Anderson BO. Androgens and androgen receptors: A clinically neglected sector in breast cancer biology. J Surg Oncol 2007;95:437-439.
109. Gallardo A, Lerma E, Escuin D, et al. Increased signalling of EGFR and IGF1R, and deregulation of PTEN/PI3K/Akt pathway are related with trastuzumab resistance in HER2 breast carcinomas. Br J Cancer 2012;106:1367-1373.

110. Protheroe CA, Dueck AC, Lee JJ, et al. Androgen Receptor-Positive Triple Negative Breast Cancer: A Unique Breast Cancer Subtype. Ann Surg Oncol 2012;19(suppl.1):S12.
111. Lundin KB, Henningson M, Hietala M, Ingvar C, Rose C, Jernström H. Androgen receptor genotypes predict response to endocrine treatment in breast cancer patients. Br J Cancer 2011;105:1676-1683.
112. Hynes NE, Lane HA. ERBB receptors and cancer: the complexity of targeted inhibitors. Nature Rev Cancer 2005;5:341–354.
113. Laurent-Puig P, Lievre A, Blons H. Mutations and response to epidermal growth factor receptor inhibitors. Clin Cancer Res 2009;15:1133-1139.
114. Park K, Han S, Shin E, Kim HJ, Kim JY. EGFR gene and protein expression in breast cancers. Euro J Surg Oncol 2007;33:956-960.
115. Teng YH, Tan WJ, Thike AA, et al. Mutations in the epidermal growth factor receptor (EGFR) gene in triple negative breast cancer: possible implications for targeted therapy. Breast Cancer Res 2011;13:R35.
116. Corzo C, Tusquets I, Salido M, et al. Characterization of HER1 (c-erbB1) status in locally advanced breast cancer using fluorescence in situ hybridization and immunohistochemistry. Tumour Biol 2005;26:25-30.
117. Kapranos N, Kounelis S, Karantasis H, Kouri E. Numerical aberrations of chromosomes 1 and 7 by fluorescent in situ hybridization and DNA ploidy analysis in breast cancer. Breast J 2005;11:448-453.
118. Sauer T, Beraki K, Jebsen PW, Naess O. Numerical abnormalities of chromosome 7 in interphase cell nuclei of breast carcinoma have no impact on immunohistochemically determined EGFR status. APMIS 1999;107:211-216.
119. Gwin K, Lezon-Geyda K, Harris L, Tavassoli FA. Chromosome 7 aneusomy in metaplastic breast carcinomas with chondroid, squamous, and spindle-cell differentiation. Int J Surg Pathol 2011;19:20-25.
120. Slamon D, Clark G, Wong S, Levin WJ, Ullrich A, McGuire WL. Human breast cancer: Correlation of relapse and survival with amplification of the HER-2/neu oncogene. Science 1987;235:177-182.

121. Varga Z, Zhao J, Öhlschlegel C, Odermatt B, Heitz PU. Preferential HER-2/neu overexpression and/or amplification in aggressive histological subtypes of invasive breast cancer. Histopathology 2004;44:332-338.
122. Bhargava R, Striebel J, Beriwal S, et al. Prevalence, morphologic features and proliferation indices of breast carcinoma molecular classes using immunohistochemical surrogate markers. Int J Clin Exp Pathol 2009;2:444-455.
123. Gown AM, Goldstein LC, Barry TS, et al. High concordance between immunohistochemistry and fluorescence in situ hybridization testing for HER2 status in breast cancer requires a normalized IHC scoring system. Mod Pathol 2008;21:1271-1277.
124. Zhang W, Yu Y. The important molecular markers on chromosome 17 and their clinical impact in breast cancer. Int J Mol Sci 2011;12:5672-5683.
125. Ross JS. Human epidermal growth factor receptor 2 testing in 2010: does chromosome 17 centromere copy number make any difference? J Clin Oncol 2010;28:4293-4295.
126. Brunelli M, Manfrin E, Martignoni G, et al. HER-2/neu assessment in breast cancer using the original FDA and new ASCO/CAP guideline recommendations: impact on selecting patients for herceptin therapy. Am J Clin Pathol 2008;129:907-911.
127. Hyun CL, Lee HE, Kim KS, et al. The effect of chromosome 17 polysomy on HER-2/neu status in breast cancer. J Clin Pathol 2008;61:317-321.
128. Cuadros M, Talavera P, López FJ, García-Peréz I, Blanco A, Concha A. Real-time RT-PCR analysis for evaluating the Her2/neu status in breast cancer. Pathobiology 2010;77:38-45.
129. Ma Y, Lespagnard L, Durbecq V, et al. Polysomy 17 in HER-2/neu status elaboration in breast cancer: effect on daily practice. Clin Cancer Res 2005;11:4393-4399.
130. Salido M, Tusquets I, Corominas JM, et al. Polysomy of chromosome 17 in breast cancer tumors showing an overexpression of ERBB2: a study of 175 cases using fluorescence in situ hybridization and immunohistochemistry. Breast Cancer Res 2005;7:R267-273.

131. Merola R, Mottolese M, Orlandi G, et al. Analysis of aneusomy level and HER-2 gene copy number and their effect on amplification rate in breast cancer specimens read as 2+ in immunohistochemical analysis. Eur J Cancer 2006;42:1501-1506.
132. Panvichian R, Tantiwetrueangdet A, Wongwaisayawan S, Nampoon A, Lertsithichai P, Leelaudomlipi S. HER2 Expression in Breast Cancer With Nonamplified HER2 and Gains of Chromosome 17 Centromere. Appl Immunohistochem Mol Morphol 2012;20:367-374.
133. Zhang Y, Martens JW, Yu JX, et al. Copy number alterations that predict metastatic capability of human breast cancer. Cancer Res 2009;69:3795-3801.
134. Viale G. Be precise! The need to consider the mechanisms for CEP17 copy number changes in breast cancer. J Pathol 2009;219:1-2.
135. Bartlett J, Munro A, Desmedt C, et al. Cancer duplication of chromosome 17 CEP predicts for anthracycline benefit: A meta-analysis of 4 trials. Cancer Res 2009;69:716S (Suppl. 24, Abstract nr 4030)
136. Bartlett J, Munro A, Dunn J, et al. Predictive markers of anthracycline benefit: a prospectively planned analysis of the UK National Epirubicin Adjuvant Trial (NEAT/BR9601). Lancet Oncol 2010;11:266-274.
137. Di Leo A, Desmedt C, Bartlett JM, et al. HER2 and TOP2A as predictive markers for anthracycline-containing chemotherapy regimens as adjuvant treatment of breast cancer: a meta-analysis of individual patient data. Lancet Oncol 2011;12:1134-1142.
138. Pritchard KI, Munro A, O'Malley FP, et al. Chromosome 17 centromere (CEP17) duplication as a predictor of anthracycline response: evidence from the NCIC Clinical Trials Group (NCIC CTG) MA.5 Trial. Breast Cancer Res Treat 2012;131:541-551.
139. Tubbs RR, Hicks DG, Cook J, et al. Fluorescence in situ hybridization (FISH) as primary methodology for the assessment of HER2 status in adenocarcinoma of the breast: a single institution experience. Diagn Mol Pathol 2007;16:207-210.
140. Nielsen KV, Müller S, Møller S, et al. Aberrations of ERBB2 and TOP2A genes in breast cancer. Mol Oncol 2010;4:161-168.

10. Biography

I studied medicine at the Sarajevo University School of Medicine from 1997 till 2004. I joined the pathology residency program at the Clinical Center of the University of Sarajevo in 2006. After obtaining the Board of Certification in pathology in 2011, I became a staff pathologist at the Department of Pathology, Clinical Center of the University of Sarajevo.

In 2007 I got a fellowship for breast pathology training program from the European Society of Mastology (EUSOMA), completed at the Breast Unit, Nottingham City Hospital, Nottingham, United Kingdom (2008).

In 2008 I was awarded a UICC/ACS fellowship for beginning investigators which was successfully completed in 2010 becoming a life time member and fellow of UICC. In the period 2008-2010 the UICC/ACS fellowship was used for research in breast cancer at the Creighton University School of Medicine, Omaha, Nebraska, USA under supervision of Professors Zoran Gatalica M.D., D.Sc. and Zhao-Yi Wang Ph.D.
In 2012 I completed the Ph.D. program in biomedicine at the Zagreb University School of Medicine (Croatia).

In May 2012 I got a post-doc fellowship at the University of Turin (Italy) through the ERAWEB program of the University of Rotterdam (the Netherlands).
I am a member of the United States & Canadian Academy of Pathology (USCAP), European Society of Pathology (ESP), European Society of Pathology Working Group for Breast Pathology, Union for International Cancer Control (UICC), The European Network in Uropathology, European Association for Cancer Research (EACR), and Clinical Genetic Society of Croatia.

I have published 26 papers of which 14 are cited in Current Content Database (Thomson ISI).

Current areas of research include molecular pathology of breast cancer with emphasis on special types of breast cancer (apocrine carcinoma, adenoid cystic carcinoma), germ cell tumors of the testis, and hereditary cancer syndromes.

Original Article

Assessment of *HER2* Gene Status in Breast Carcinomas With Polysomy of Chromosome 17

Semir Vranic, MD[1,2]; Bryan Teruya, MD[1]; Susan Repertinger, MD[1]; Pamela Ulmer, MD[1]; Jill Hagenkord, MD[1]; and Zoran Gatalica, MD, DSc[1]

BACKGROUND: The current study was performed to determine the impact of polysomy 17 on the interpretation of *HER2* testing of invasive breast carcinomas using fluorescent in situ hybridization methods. Current American Society of Clinical Oncology/College of American Pathologists guidelines define *HER2*-positive tumors as those with >6 *HER2* genes per nucleus or those with *HER2*/CEP17 (chromosome 17) ratio >2.2. These guidelines are potentially contradictory in tumors with polysomy of chromosome 17. **METHODS:** Seventy-two breast carcinoma cases with reported polysomy of chromosome 17 (≥3 CEP17 signals on average) by fluorescent in situ hybridization were identified, and the corresponding HER2 immunohistochemistry was obtained. The *HER2* status of the archived samples was reviewed, and the tumors were recategorized according to the 2007 American Society of Clinical Oncology/College of American Pathologists guidelines. **RESULTS:** The average CEP17 copy number for the group was 4.5 (range, 3.0-10.4). Thirty-three (45.8%) cases had >6 copies of *HER2* per nucleus. Twenty-one cases (29.2%) qualified as *HER2* gene amplified using the *HER2*/CEP17 ratio (>2.2) guideline. All these cases had >6 *HER2* signals, which represented 63.6% of all cases with >6 *HER2* signals. HER2 protein expression showed significant positive correlations with both *HER2* gene copy number and *HER2*/CEP17 ratio ($P < .01$, $r_s = 0.56$ and 0.64, respectively). **CONCLUSIONS:** Increased CEP17 signals detected in invasive breast carcinomas may lead to discordant interpretation of gene amplification in a significant proportion of the cases, depending on which criterion (ratio vs absolute number) is used for interpretation. However, increased gene dosage (>6 *HER2* genes or *HER2*/CEP17 ratio >2.2), regardless of the evaluation method, is positively correlated with HER2 protein expression. ***Cancer* 2011;117:48–53.** © *2010 American Cancer Society*.

KEYWORDS: breast cancer, HER2, fluorescent in situ hybridization, amplification, CEP17 polysomy.

HER2 status in breast carcinomas has become a standard prognostic marker and is an essential test for the selection of breast cancer patients eligible for the targeted therapy (eg, trastuzumab and lapatinib).[1,2] Trastuzumab, a humanized monoclonal antibody that targets the HER2 protein, is routinely used in the treatment of patients with breast carcinoma overexpressing this protein. Approximately 20% of breast cancers show HER2 overexpression and are characterized by decreased relapse-free time and overall survival.[3] Therefore, trastuzumab therapy is widely used as a first-line cancer treatment in breast cancer patients whose primary or metastatic tumors overexpress the HER2 protein.[4] Trastuzumab improves response rates and survival, and decreases time to progression when used alone or when added to chemotherapy in metastatic breast cancer.[5] Given the significant clinical benefits of trastuzumab in patients with HER2-positive breast cancer, it is of paramount importance to accurately identify all patients eligible for this therapy.

The primary mechanism of HER2 overexpression is amplification of the *HER2* gene on chromosome 17,[6] which is typically detected by fluorescence in situ hybridization (FISH), although other in situ hybridization methods are now increasingly used (chromogenic and silver in situ hybridization) as well as array comparative genomic hybridization. For FISH analysis, 3 kits approved by the US Food and Drug Administration are available: 1) PathVysion (Abbott

Corresponding author: Zoran Gatalica, MD, DSc, Department of Pathology, Creighton University Medical Center, 601 N 30th Street, Omaha, NE 68131; Fax: (402) 280-5247; zorangatalica@creighton.edu

[1]Department of Pathology, Creighton University School of Medicine, Omaha, Nebraska; [2]Department of Pathology, Clinical Center of the University of Sarajevo, Sarajevo, Bosnia-Herzegovina

We thank Mirza Bašić, BSc, MSc for his excellent technical support and Shera F. Kash, PhD for analyzing breast cancer data.

DOI: 10.1002/cncr.25580, **Received:** April 23, 2010; **Revised:** June 29, 2010; **Accepted:** July 19, 2010, **Published online** August 27, 2010 in Wiley Online Library (wileyonlinelibrary.com)

Laboratories, Abbott Park, Ill), 2) INFORM (Ventana Medical Systems, Tucson, Ariz), or 3) PHarmDx (DAKO, Glostrup, Denmark). The INFORM kit evaluates only the *HER2* gene copy number, and results are based on the absolute *HER2* signal count. The PathVysion and PHarmDx kits use 2 probes, a *HER2* probe and a CEP17 (chromosome 17 centromere enumeration probe) hybridization control probe, and results are based on the *HER2*/CEP17 ratio.

Current American Society of Clinical Oncology/College of American Pathologists guidelines now define *HER2*-positive tumors as those with an average *HER2* gene copy number of >6 gene copies per nucleus (for single probe assays) or as a *HER2*/CEP17 ratio of >2.2 (for double probe assays).[3] Typically, similar conclusions are obtained with either the absolute *HER2* signal count or the *HER2*/CEP17 ratio,[7] but discrepancies can occur in cancers with increased CEP17 copy number (>3 copies per tumor cell). For example, tumors with increased CEP17 copy number and slightly increased *HER2* copy number may be considered amplified by single probe assays but unamplified by double probe assays. It is estimated that this occurs in 2% to 9% of breast cancers.[8,9] However, the reported frequency of CEP17 copy number alteration in breast cancer varies, depending on the study population, selection criteria, and the definition of chromosome 17 polysomy (CEP17).[10-13] In the literature, it is commonly assumed that an increase in CEP17 copy number is because of polysomy 17, and these terms have been used interchangeably. However, it is important to recognize that an increase in CEP17 signals does not necessarily represent a true polysomy (ie, gain of the entire chromosome), but rather may represent a focal pericentromeric gain or a partial polysomy.[12,14]

We have investigated the effect of increased CEP17 signal number on the interpretation of FISH results in breast cancers diagnosed at our institution. We confirm that increased CEP17 signals may lead to discordant interpretations between the *HER2*/CEP17 ratio and absolute *HER2* gene copy number in a significant proportion of cases.

MATERIALS AND METHODS

Patients

Retrospective review of pathology reports from Creighton Medical Laboratories (Creighton University, Omaha, Neb) identified 72 patients whose breast cancers had ≥3 CEP17 signals per nucleus on average by FISH. The cohort represented approximately 12% of all tested cases in the period 2003 to 2007. The study was approved by the Creighton University Institutional Review Board.

Fluorescent In Situ Hybridization

Formalin-fixed paraffin-embedded tissue sections were used in all cases.

Two-color FISH was performed on 3.5 μm-thick sections from the paraffin blocks. Before hybridization, sections were deparaffinized, dehydrated in 100% ethanol, and air dried. Commercially available Locus Specific Identifier *HER2* probe (190 Kb Spectrum Orange directly labeled fluorescent DNA probe) and a CEP17 probe (5.4 Kb Spectrum Green directly labeled fluorescent DNA) were used according to the manufacturer's recommendations (PathVysion, Abbott Molecular, Des Plaines, Ill). Thirty nuclei were scored per sample, and the number of *HER2* (orange) and CEP17 (green) signals were recorded. A ratio of *HER2* to CEP17 >2.2 was defined as gene amplification; polysomy 17 was defined as ≥3 CEP17 signals per nucleus (average for 30 cells).

Immunohistochemistry

Immunohistochemical assay for HER-2/*neu* (IgG1, Clone CB11, Ventana Medical Systems) expression was performed using a commercially available detection kit and automated staining procedures (Benchmark, Ventana Medical Systems).

Automated Cell Imaging System (ACIS, ChromaVision Medical Systems, San Juan Capistrano, Calif) was used for measuring the percentage of cells with membranous staining of HER2 protein. This system combines color-based imaging technology with automated microscopy to provide quantitative information on the intensity and the percentage of cells with positive staining; pathologists reviewed the images on screen and selected tumor-rich areas for analysis. The Automated Cell Imaging System scoring system for HER2 protein was as follows: score <1.0 (negative, equivalent to 1+), score 1.0 to 2.4 (borderline, 2+), and score ≥2.4 (positive, 3+).

Single Nucleotide Polymorphism Array

Single nucleotide polymorphism (SNP) array karyotyping was performed on 2 selected cases with borderline score (2+) of HER-2/*neu* protein on immunohistochemistry (IHC) and polysomy 17 (≥3 signals of CEP17 per nucleus) on FISH. After tumor enrichment via manual microdissection, DNA was obtained from 10 μm paraffin sections as described previously,[15] and 250K *Nsp* Assay

Kits (Affymetrix, Santa Clara, Calif) were used according to the manufacturer's protocol, except for increased starting genomic DNA. One microgram of genomic DNA was digested with *Nsp* restriction enzyme, ligated to adaptors, and amplified by polymerase chain reaction (PCR) using a universal primer. After purification of PCR products with SNP Clean magnetic beads (Agencourt Biosciences, Beverly, Mass), amplicons were quantified, fragmented, labeled, and hybridized to 250K *Nsp* arrays. After washing and staining, the arrays were scanned to generate CEL files for downstream analysis.

Data acquired from the Affymetrix Gene-Chip Operating System v4.0 were analyzed using Affymetrix Gene-Chip Genotyping Analysis Software v4.1. Copy number analysis was performed with Copy Number Analyzer for Affymetrix GeneChip arrays v3.0, as previously described.[16]

Statistical Analysis

A nonparametric chi-square test was used for testing associations between variables. For correlation purposes, the nonparametric Spearman correlation rank was used. All statistical tests were 2-sided, and P values $<.05$ were considered statistically significant. Statistical analysis was performed using the Statistical Package for Social Sciences software (v17.0; SPPS Inc, Chicago, Ill).

RESULTS

Clinicopathologic Characteristics of the Cohort

All but 2 patients were women. The patient's age ranged between 34 and 99 years (mean, 58.3 years). The study included 68 primary and 4 metastatic breast carcinomas. The majority of the cases were invasive ductal carcinomas of no special type (65 cases, 90.3%). The remaining cases included 3 mucinous carcinomas (4.2%), 1 case of invasive lobular carcinoma (1.4%), 1 case of mammary Paget disease in association with invasive ductal carcinoma (1.4%), and 2 cases of ductal carcinoma in situ (2.8%).

FISH Results and Interpretation

The *HER* gene and CEP17 copy number, *HER2*/CEP17 ratio, and HER2 protein expression results are summarized in Table 1 and Figure 1 (Euler diagram). Average CEP17 copy number for the cohort was 4.5 and ranged from 3.0 to 10.4 (Fig. 2). *HER2* gene amplification as defined as the ratio of *HER2*/CEP17 >2.2, was identified in 21 cases (29.2%). All these cases had >6 *HER2* signals per nucleus. More than 6 *HER2* copies per nucleus were observed in an additional 12 cases without an increased *HER2*/CEP17 ratio, for a total of 33 cases (45.8% of all cases); using the criterion of >6 *HER2* signals per nucleus as positive for amplification, these 33 cases would be categorized as *HER2* amplified. These findings, therefore, demonstrate that discrepant interpretation of gene amplification status was detected in 12 (36.4%) cases when the number of CEP17 copies was taken into account. Of these 12 cases, HER-2/*neu* protein IHC was available for 10 cases: 3 cases had HER2 overexpression (score 3+), and 6 cases had borderline score (2+), whereas 1 case was negative (score 1+).

Interestingly, *HER2*/CEP17 ratios <1.0 were observed in 9 (12.5%) cases, of which 3 (4%) cases had a *HER2*/CEP17 ratio ≤0.7. One of these cases had a ratio

Table 1. Results of the Immunohistochemistry and Fluorescent In Situ Hybridization in a Cohort of 72 Cases with CEP17 Polysomy

***HER2* Gene Copy No.**	***HER2*/CEP17 Ratio**
>6 copies, 33 (45.8%)	>2.2, 21 (29.2%)
≤6 copies, 39 (54.2%)	<2.2, 51 (70.8%)
CEP17 Copy No.	**HER-2/*neu* Protein Expression**
>6 copies, 9 (12.5%)	≥2.4 (score 3+), 22 (36.1%)
≤6 copies, 63 (87.5%)	<2.4 (score 0 to 2+), 39 (63.9%)

HER2 indicates human epidermal growth factor receptor 2.

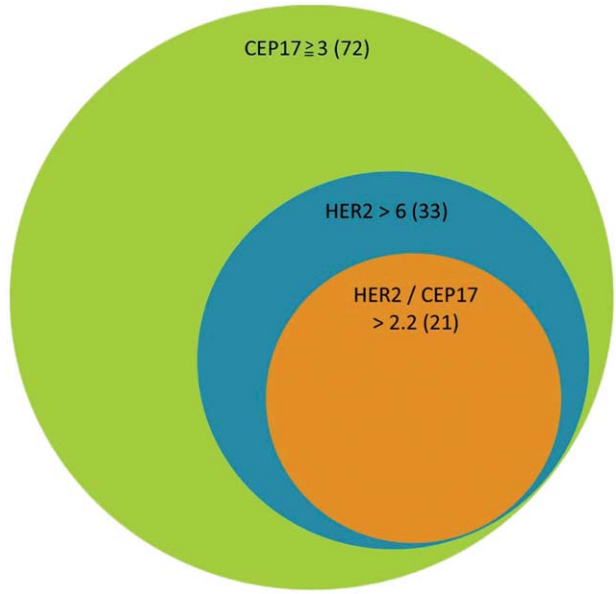

Figure 1. A Euler diagram showing the subdistribution of cases of breast carcinomas with CEP17 polysomy is presented.

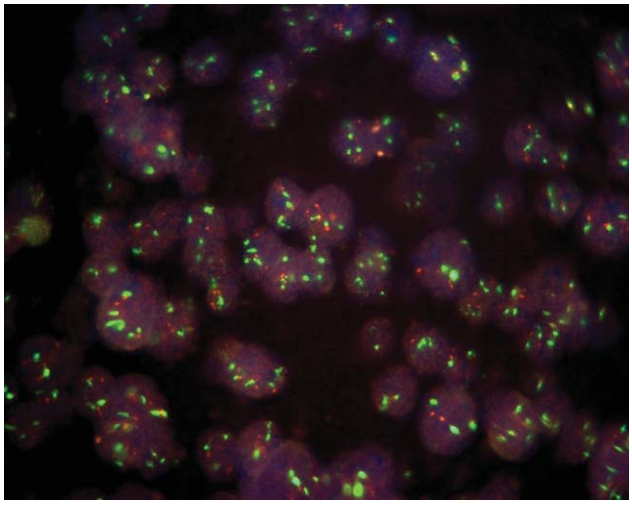

Figure 2. A dual-color fluorescent in situ hybridization assay demonstrating multiple copies of the CEP17 (green) and *HER2* (red) genes is shown.

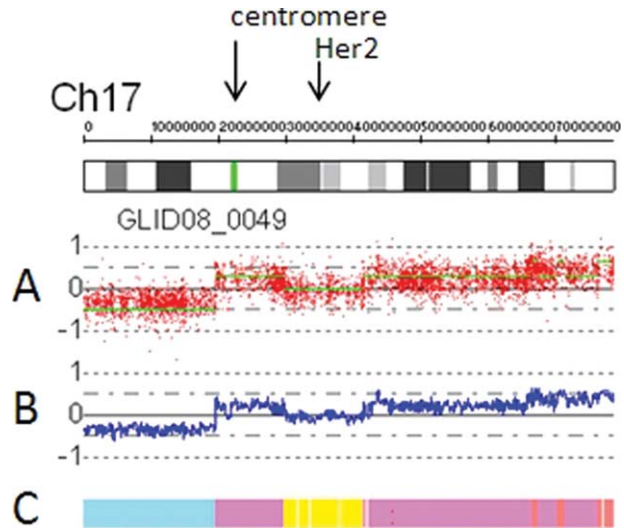

Figure 3. A single nucleotide polymorphism (SNP) array karyotype of chromosome 17 demonstrating the copy number variability along the length of the chromosome is shown. (A) Raw log2 ratio of the tumor/normal for each SNP probe on chromosome 17 is shown. A copy number of 2 indicates 0. (B) Log2 ratio smoothed over 10 SNPs is shown. (C) A copy number hidden Markov model is shown, in which blue indicates 1; yellow, 2; pink, 3; pink-red, 4; red-pink, 5; and red >5.

of <0.5 (1.71 *HER2* signals and 4.06 CEP17 signals, ratio = 0.42), indicating that amplification of the centromeric region may not be accompanied by amplification of the *HER2* gene region in some cases.

SNP Array Karyotyping and Interpretation

Cytogenomic arrays provide high-resolution, genome-wide copy number information. Affymetrix 250K Nsp mapping arrays contain 250,000 probes genome-wide, including 4854 probes on chromosome 17, and were used in 2 cases in our series to further investigate the relationship between CEP17, *HER2* gene, and other loci on chromosome 17. SNP array analysis of the first case, with a FISH *HER2*/CEP17 ratio of 0.7 (2.3 of 3.3), revealed that copy number variability occurring along chromosome 17 may be undetected when using 1 or 2 FISH probes to determine chromosome 17 copy number. In this case, the copy number at the CEP17 locus is 3, whereas that at the *HER2* locus is 2, generating a ratio of 0.67 (Fig. 3). Another case with similar FISH result (*HER2*/CEP17 ratio 0.7 [5.7 of 7.7]) showed discrete amplifications of both the centromeric region and the *HER2* locus along with complex cytogenetic changes that included a relative loss of 17p and a relative gain of most of the 17q chromosome.

Correlation Between Protein Expression and HER2 Gene Status

HER2 protein expression results were available for 61 cases. Nine (14.8%) cases were negative (scores 0-1+), 30 (49.2%) cases were borderline (score 2+), and 22 (36%) cases were positive (score 3+).

HER2 protein expression positively correlated with both *HER2* gene copy number and *HER2*/CEP17 ratio ($P < .01$, $r_s = 0.56$ and 0.64, respectively). A trend toward positive correlation was found between HER2 protein expression and CEP17 copy number, but did not reach statistical significance ($P = .067$).

Notably, 6 (27.3%) of 22 cases with HER2 protein scores of 3+ had no *HER2* gene amplification (ratio, <2.2). However, 4 of these 6 cases harbored >6 copies of the *HER2* gene, fulfilling the absolute copy number criterion for *HER2* gene amplification.[3] In the borderline protein expression category (score 2+), only 4 of 30 cases had *HER2* gene amplification (ratio, <2.2; 13.3%). None of the cases with score 0 to 1+ showed *HER2* gene amplification by FISH.

DISCUSSION

HER2 status is routinely assessed in all patients with a new diagnosis of invasive breast carcinoma. However, the most accurate method of assessing *HER2* status is yet to be determined, and interpretation guidelines[3] as given by American Society of Clinical Oncology/College of American Pathologists may give conflicting results, depending

on whether the laboratory uses a single probe kit or a double probe kit. The most recent American Society of Clinical Oncology/College of American Pathologists guidelines for *HER2* testing define *HER2* amplification by FISH as >6 *HER2* gene copies per nucleus or a ratio (*HER2* gene signals to chromosome 17 signals) of >2.2.[3] Although this appears rather straightforward, abnormalities of chromosome 17 in breast cancer are frequent and may include whole chromosome copy number gains (polysomy 17) or losses (monosomy 17), focal copy number gains and losses, and other structural rearrangements.[10] These abnormalities of chromosome 17 can lead to discrepant interpretations of FISH data, depending on which criterion is used.

The potential for such misinterpretations is significant, given that polysomy 17 is relatively common in breast carcinomas, although the reported frequency of this finding varies in the literature.[10-13] In a recently published series by Vanden Bempt et al, >40% of breast carcinomas were found to harbor increased CEP17 copy number.[11] Our recent study on apocrine carcinoma of the breast also revealed increased CEP17 copy number in 33% of the apocrine carcinomas of the breast.[17] The present study also revealed a smaller overall proportion (12% of all tested cases) of increased CEP17 copy number cases, composed predominantly of invasive breast carcinomas of no special type. In addition, increased CEP17 copy number is frequently found in tumors showing HER2 overexpression, including those with a borderline (2+) score, as confirmed in our study.[18-20] Our series included unselected (no prior IHC determination of HER-2/*neu* protein) and selected (equivocal IHC staining results) cases, reflecting our referral laboratory's mixture of cases received from different institutions.

HER2 status determination by FISH depends on the criteria used.[21] Our study indicates that determination of *HER2* amplification status may show discordant results, depending on whether CEP17 copy number was taken into account. Indeed, more than one-third of the studied cases harboring >6 copies of the *HER2* gene did not show *HER2* gene amplification (ratio, >2.2). Importantly, a majority of these cases had a borderline score (2+) on IHC, and therefore were not amenable for the targeted therapy. Similarly, increased CEP17 copy number appears to contribute to the discordant results between protein expression and gene amplification (IHC 3+/FISH negative), because 6 (27%) of 22 cases with a 3+ result on IHC did not show a *HER2*/CEP17 ratio >2.2. Notably, 4 of 6 cases demonstrated >6 copies of the *HER2* gene. Therefore, these cases did not fit within the *HER2*-amplified breast carcinoma category.[21,22] Taken together, a subgroup of borderline (2+) breast carcinomas represented a majority of the cases with increased CEP17 copy number in our study, and only 13% of the cases showed *HER2* gene amplification. This finding is in line with previous studies that confirmed that breast cancers with an equivocal IHC score (2+) harbored CEP17 polysomy instead of *HER2* gene amplification.[18,23,24]

It is common in the literature to use the term *polysomy 17* when there is an increase in CEP17 signal by FISH. However, FISH analysis is a targeted assay and cannot assess the copy number of an entire chromosome. An increased number of CEP17 signals may represent a focal gain in the centromeric region of chromosome 17 rather than a true polysomy 17. Affymetrix 250K *Nsp* mapping arrays contain 4854 probes on chromosome 17. By generating a SNP array karyotype, one can discern between true polysomy 17 and focal gain of CEP17. Our reanalysis of published data (GEO dataset record GSE10099) revealed that true polysomy of chromosome 17 is a rare event, present in 1% of all analyzed cases.[25] Most increases in CEP17 copy number by FISH are because of focal gains rather than true polysomy 17. This finding has been reported by others.[14,26]

Interestingly, CEP17 copy number may have a predictive therapeutic value; increased CEP17 copy number appears to be a predictive marker for anthracycline-based chemotherapy in breast cancer.[27,28]

Similar to gains in CEP17 copy number as seen on FISH testing, deletions of the CEP17 copy number do not necessarily correlate with deletion of the entire chromosome. In a previous study by Tubbs et al, *HER2* monoallelic deletion (*HER2*/CEP17 $\leq$0.7) was demonstrated in 2% (12 of 742) of breast carcinomas.[29] We likewise found deletion of the *HER2* gene in a subset of cases with polysomy 17 (3 of 72, 4%). This finding is also supported by the SNP array karyotype of the 2 cases included in the present study.

In summary, we found that increased CEP17 copy number ($\geq$3 copies of CEP17) is seen in 12% of breast tumors undergoing routine assessment of *HER2* gene status. Half of these cases exhibited an equivocal (2+) score on IHC. Furthermore, a significant proportion of cases showing increased CEP17 copy number led to discrepant interpretations based on which criterion was used (*HER2*/CEP17 ratio vs absolute *HER2* gene copy). However, positive gene dosage (>6 *HER2* genes or *HER2*/CEP17 ratio >2.2), regardless of the evaluation method used, is

positively correlated with HER2 protein expression. As a result of our findings, we propose that the average number of *HER2* genes per nucleus be reported alongside the average *HER2*/CEP17 ratio, to accurately identify all patients eligible for trastuzumab treatment.

CONFLICT OF INTEREST DISCLOSURES

Dr. Jill Hagenkord is a cofounder and chief medical officer in iKaryos Diagnostics, which uses Affymetrix and single nucleotide polymorphism arrays for commercial testing.

REFERENCES

1. Perez EA. Cardiac toxicity of ErbB2-targeted therapies: what do we know? *Clin Breast Cancer*. 2008;8(suppl 3):S114-S120.
2. Geyer CE, Forster J, Lindquist D, et al. Lapatinib plus capecitabine for HER2-positive advanced breast cancer. *N Engl J Med.* 2006;355:2733-2743.
3. Wolff AC, Hammond ME, Schwartz JN, et al. American Society of Clinical Oncology; College of American Pathologists. American Society of Clinical Oncology/College of American Pathologists guideline recommendations for human epidermal growth factor receptor 2 testing in breast cancer. *J Clin Oncol*. 2007;25:118-145.
4. Amar S, Roy V, Perez EA. Treatment of metastatic breast cancer: looking towards the future. *Breast Cancer Res Treat.* 2009;114:413-422.
5. Slamon DJ, Leyland-Jones B, Shak S, et al. Use of chemotherapy plus a monoclonal antibody against HER2 for metastatic breast cancer that overexpresses HER2. *N Engl J Med.* 2001;344:783-792.
6. Akiyama T, Sudo C, Ogawara H, Toyoshima K, Yamamoto T. The product of the human c-erbB-2 gene: a 185-kilodalton glycoprotein with tyrosine kinase activity. *Science.* 1986;232:1644-1646.
7. Sauter G, Lee J, Bartlett JMS, Slamon DJ, Press MF. Guidelines for human epidermal growth factor receptor 2 testing: biologic and methodologic considerations. *J Clin Oncol.* 2009;27:1323-1333.
8. Bartlett J, Going J, Mallon E, et al. Evaluating HER2 amplification and overexpresson in breast cancer. *J Pathol.* 2001;195:422-428.
9. Watters AD, Going JJ, Cooke TG, et al. Chromosome 17 aneusomy is associated with poor prognostic factors in invasive breast carcinoma. *Breast Cancer Res Treat.* 2003;77:109-114.
10. Reinholz MM, Bruzek AK, Visscher DW, et al. Breast cancer and aneusomy 17: implications for carcinogenesis and therapeutic response. *Lancet Oncol.* 2009;10:267-277.
11. Vanden Bempt I, Van Loo P, Drijkoningen M, et al. Polysomy 17 in breast cancer: clinicopathologic significance and impact on HER-2 testing. *J Clin Oncol.* 2008;26:4869-4874.
12. Yeh IT, Martin MA, Robetorye RS, et al. Clinical validation of an array CGH test for HER2 status in breast cancer reveals that polysomy 17 is a rare event. *Mod Pathol.* 2009;22:1169-1175.
13. Wang S, Saboorian H, Frenkel EP, et al. Aneusomy 17 in breast cancer: its role in HER-2/neu protein expression and implication for clinical assessment of HER-2/neu status. *Mod Pathol.* 2002;15:137-145.
14. Marchio C, Lambros MB, Gugliotta P, et al. Does chromosome 17 centromere copy number predict polysomy in breast cancer? A fluorescence in situ hybridization and microarray-based CGH analysis. *J Pathol.* 2009;219:16-24.
15. Lyons-Weiler M, Hagenkord J, Sciulli CM, Dhir R, Monzon FA. Optimization of the Affymetrix GeneChip mapping 10 K 2.0 assay for routine clinical use on formalin fixed paraffin embedded tissues. *Diagn Mol Pathol.* 2008;17:3-13.
16. Monzon FA, Hagenkord J, Lyons-Weiler M, et al. Whole genome SNP arrays as a potential diagnostic tool for the detection of characteristic chromosomal aberrations in renal epithelial tumors. *Mod Pathol.* 2008;21:599-608.
17. Vranic S, Tawfik O, Palazzo J, et al. EGFR and HER-2/neu expression in invasive apocrine carcinoma of the breast. *Mod Pathol.* 2010;23:644-653.
18. Krishnamurti U, Hammers JL, Atem FD, Storto PD, Silverman JF. Poor prognostic significance of unamplified chromosome 17 polysomy in invasive breast carcinoma. *Mod Pathol.* 2009;22:1044-1048.
19. Hyun CL, Lee HE, Kim KS, et al. The effect of chromosome 17 polysomy on HER-2/neu status in breast cancer. *J Clin Pathol.* 2008;61:317-321.
20. Cuadros M, Talavera P, Lopez FJ, Garcia-Perez I, Blanco A, Concha A. Real-time RT-PCR analysis for evaluating the Her2/neu status in breast cancer. *Pathobiology.* 2010;77:38-45.
21. Ma Y, Lespagnard L, Durbecq V, et al. Polysomy 17 in HER-2/neu status elaboration in breast cancer: effect on daily practice. *Clin Cancer Res.* 2005;11:4393-4399.
22. Varshney D, Zhou YY, Geller SA, Alsabeh R. Determination of HER-2 status and chromosome 17 polysomy in breast carcinomas comparing HercepTest and PathVysion FISH assay. *Am J Clin Pathol.* 2004;121:70-77.
23. Salido M, Tusquets I, Corominas JM, et al. Polysomy of chromosome 17 in breast cancer tumors showing an overexpression of ERBB2: a study of 175 cases using fluorescence in situ hybridization and immunohistochemistry. *Breast Cancer Res.* 2005;7:R267-R273.
24. Merola R, Mottolese M, Orlandi G, et al. Analysis of aneusomy level and HER-2 gene copy number and their effect on amplification rate in breast cancer specimens read as 2+ in immunohistochemical analysis. *Eur J Cancer.* 2006;42:1501-1506.
25. Zhang Y, Martens JW, Yu JX, et al. Copy number alterations that predict metastatic capability of human breast cancer. *Cancer Res.* 2009;69:3795-3801.
26. Moelans CB, de Weger RA, van Diest PJ. Absence of chromosome 17 polysomy in breast cancer: analysis by CEP17 chromogenic in situ hybridization and multiplex ligation-dependent probe amplification. *Breast Cancer Res Treat.* 2010;120:1-7.
27. Bartlett J, Munro A, Desmedt C, et al. Cancer duplication of chromosome 17 CEP predicts for anthracycline benefit: a meta-analysis of 4 trials [abstract]. *Cancer Res*. 2009;69(suppl 24):716S Abstract nr 4030.
28. Bartlett J, Munro A, Dunn J, et al. Predictive markers of anthracycline benefit: a prospectively planned analysis of the UK National Epirubicin Adjuvant Trial (NEAT/BR9601). *Lancet Oncol.* 2010;11:266-274.
29. Tubbs RR, Hicks DG, Cook J, et al. Fluorescence in situ hybridization (FISH) as primary methodology for the assessment of HER2 status in adenocarcinoma of the breast: a single institution experience. *Diagn Mol Pathol.* 2007;16:207-210.

Modern Pathology (2010) 23, 644–653
© 2010 USCAP, Inc. All rights reserved 0893-3952/10 $32.00

EGFR and HER-2/neu expression in invasive apocrine carcinoma of the breast

Semir Vranic[1,2], Ossama Tawfik[3], Juan Palazzo[4], Nurija Bilalovic[2], Eduardo Eyzaguirre[5], Lisa MJ Lee[1], Patrick Adegboyega[5], Jill Hagenkord[1] and Zoran Gatalica[1]

[1]*Department of Pathology, Creighton University Medical Center, Omaha, NE, USA;* [2]*Department of Pathology, Clinical Center of the University of Sarajevo, Sarajevo, Bosnia and Herzegovina;* [3]*Department of Pathology and Laboratory Medicine, University of Kansas Medical Center, Kansas City, KS, USA;* [4]*Department of Pathology, Anatomy and Cell Biology, Thomas Jefferson University Hospital, Philadelphia, PA, USA and* [5]*Department of Pathology, The University of Texas Medical Branch, Galveston, TX, USA*

This study was undertaken to investigate epidermal growth factor receptor (EGFR) and human epidermal growth factor receptor 2 (HER-2)/neu expression in a cohort of apocrine carcinomas of the breast with emphasis on the classification of the breast tumors with apocrine morphology. In total, 55 breast carcinomas morphologically diagnosed as apocrine were evaluated for the steroid receptor expression profile characteristic of normal apocrine epithelium (androgen receptor positive/estrogen receptor (ER) negative/progesterone receptor (PR) negative), and for the expression of EGFR and Her-2/neu proteins, and the copy number ratios of the genes *EGFR/CEP7* and *HER-2/CEP17*. On the basis of the results of steroid receptors expression, 38 (69%) cases were classified as pure apocrine carcinoma (androgen receptor positive/ER negative/PR negative), whereas 17 (31%) were re-classified as apocrine-like carcinomas because they did not have the characteristic steroid receptor expression profile. Her-2/neu overexpression was observed in 54% of the cases (57% pure apocrine carcinomas *vs* 47% apocrine-like carcinomas). *HER-2/neu* gene amplification was demonstrated in 52% of all cases (54% pure apocrine carcinomas *vs* 46% apocrine-like carcinomas). EGFR protein (scores 1 to 3+) was detected in 62% of all cases and was expressed in a higher proportion of pure apocrine carcinomas than in the apocrine-like carcinomas group (76 *vs* 29%, $P=0.006$). In the pure apocrine carcinoma group, Her-2/neu and EGFR protein expression were inversely correlated ($P=0.006$, $r=-0.499$). *EGFR* gene amplification was observed in two pure apocrine carcinomas and one apocrine-like carcinoma. Polysomy 7 was commonly present in pure apocrine carcinomas (61 *vs* 27% of apocrine-like carcinomas; $P=0.083$) and showed a weak positive correlation with EGFR protein expression ($P=0.025$, $r=0.326$). Our study showed that apocrine breast carcinomas are molecularly diverse group of carcinomas. Strictly defined pure apocrine carcinomas are either HER-2-overexpressing breast carcinomas or triple-negative breast carcinomas, whereas apocrine-like carcinomas predominantly belong to the luminal phenotype. Pure apocrine carcinomas show consistent overexpression of either EGFR or HER-2/neu, which could have significant therapeutic implications.
Modern Pathology (2010) **23,** 644–653; doi:10.1038/modpathol.2010.50; published online 5 March 2010

Keywords: apocrine carcinoma; breast; HER-1/EGFR; HER-2/neu; gene amplification; polysomy

Apocrine carcinomas of the breast, defined as breast tumors composed of epithelium with apocrine differentiation in >90% of the tumor cell population, represent a rare subtype, constituting <5% of all breast cancers.[1–3] Apocrine differentiation is defined by the presence of large cells with prominent eosinophilic, flocculent cytoplasm, with sharply defined cell borders, and with large nuclei containing prominent macronucleoli. Importantly, a characteristic steroid receptor expression profile further defines these tumors as consistently estrogen receptor (ER) negative, progesterone receptor (PR) negative and androgen receptor (AR) positive.[4–8]

Correspondence: Dr Z Gatalica, MD, DSc, Department of Pathology, Creighton University Medical Center, 601 N 30th Street, Omaha, NE 68131, USA.
E-mail: zorangatalica@creighton.edu
Received 29 July 2009; revised and accepted 25 January 2010; published online 5 March 2010

Although AR expression has been variably observed in up to 60–70% breast carcinomas,[9,10] consistent AR expression tends to be a feature of apocrine breast lesions including invasive apocrine carcinomas.[4,5,8,11,12] Moreover, recently published gene expression microarray studies defined a characteristic 'molecular apocrine' gene expression profile found in apocrine carcinomas. These studies showed apocrine tumors to be different from common luminal and basal cell breast carcinoma subtypes.[13–16] This molecular apocrine group was characterized by increased AR signaling along with increased human epidermal growth factor receptor 2 (*HER-2*)*/neu* gene signaling.[13,16] A study using an apocrine cell line model also demonstrated the existence of a functionally significant cross-talk between AR and *HER-2/neu* pathways through ERK1/2 in ER-negative breast carcinomas.[17] This cross-talk affects cell proliferation and apoptosis and could have a significant therapeutic impact.[17] Although apocrine carcinoma exhibits distinctive histopatological and molecular features, the lack of standardized diagnostic criteria has produced controversial and heterogeneous results in the scientific literature in terms of its immunohistochemical profile and molecular classification.[2,18–20]

The erbB (HER) family is comprised of four homologous transmembrane receptors involved in growth factor cellular signaling.[21] Epidermal growth factor receptor (*EGFR*) (or *HER-1*) and *HER-2/neu* genes are of particular importance in breast cancer pathogenesis as their activation and coexpression are associated with an aggressive clinical course and a poor outcome.[22] Both proteins can be targeted by specific therapeutic modalities. However, these tyrosine kinase receptors have not been systematically studied in invasive apocrine carcinomas of the breast.

We studied EGFR and HER-2/neu in apocrine breast carcinomas meeting strict morphological and immunophenotypic criteria with regard to both protein expression and gene copy number. We identified significant differences between pure apocrine carcinoma (apocrine morphology and a characteristic AR+/ER−/PR− steroid receptor profile) and apocrine-like breast carcinomas (apocrine morphology without characteristic apocrine steroid receptor profile), which could have important diagnostic and therapeutic implications.

Materials and methods

Specimens

The formalin-fixed paraffin-embedded tumor samples were obtained from 55 female patients with invasive apocrine carcinomas (52 surgical and 3 core biopsy specimens). Mean age of patients was 62 years (range: 32–92 years). The cases were retrieved from the files of Creighton University Medical Center (Omaha, NE, USA), Kansas University Medical Center (Kansas City, KS, USA), Thomas Jefferson University Hospital (Philadelphia, PA, USA), The University of Texas Medical Branch (Galveston, TX, USA) and Clinical Center of the University of Sarajevo (Bosnia and Herzegovina). Routinely stained hematoxylin and eosin tumor sections were re-examined (ZG and SV) and the diagnoses were confirmed. Institutional review board of the Creighton University approved the study.

Immunohistochemistry

Immunohistochemical assays for ER-alpha (ER-α; clone 6F11, Ventana Medical Systems, Tucson, AZ, USA), PR (clone 16, Ventana Medical Systems), AR (Clone AR441, DakoCytomation, Carpinteria, CA, USA), EGFR (DAKO EGFR PharmDX diagnostic kit; DakoCytomation) and Her-2/neu (Clone CB11, Ventana Medical Systems) expression were performed on the formalin-fixed paraffin-embedded sections using the commercially available detection kits and automated staining procedures.

The tumor was regarded as positive for ER and PR if $>5\%$ of the cells showed nuclear staining, whereas a 10% cutoff was applied for AR staining.[8,23]

Her-2/neu protein expression results were scored according to the American Society of Clinical Oncology/College of American Pathologists Guideline Recommendations.[24] Briefly, cases showing no membrane immunostaining or membrane immunostaining in $<10\%$ tumor cells were scored 0+; cases with weak and incomplete membrane staining in $>10\%$ of tumor cells were scored 1+; cases with complete membrane staining that was either non-uniform or weak in intensity but with obvious circumferential distribution in $>10\%$ of cells were scored 2+; and cases with strong membrane staining in $>30\%$ tumor cells were scored 3+.[24]

EGFR scoring was carried out according to the manufacturer's (Dako) recommendation: only membranous staining is considered as a specific positive result; weak (1+) intensity is defined as faint and incomplete membrane positivity; moderate (2+) intensity and strong (3+) staining are both varying degrees of circumferential staining of membranes. The tumor was considered positive if a proportion of stained cells exceeded 1% at any intensity.

Automated Cell Imaging System (ChromaVision Medical Systems, San Juan Capistrano, CA, USA) was used for measuring the percentage of cells with the nuclear staining for ER, PR and AR, and the extent and intensity of membranous staining of EGFR and Her-2/neu. Pathologists reviewed the images and selected tumor-rich areas of the sections for the analysis.

FISH Analysis

Fluorescent *in situ* hybridization (FISH) was performed to evaluate copy number at *EGFR* and *HER-2/neu* loci. Chromosome enumeration probes CEP7 and CEP17 were used as positive controls and

indicators of chromosome ploidy (Abbott Molecular, Des Plaines, IL, USA). Probe signals were enumerated in predominant tumor cell populations. At least 30 nuclei were scored per sample. A ratio of *HER-2/CEP17* >2.2 was defined as gene amplification; a ratio 1.8–2.1 was interpreted as borderline, and a ratio <1.8 was defined as negative. The same criteria were used for interpretation of EGFR/CEP7 ratios. Equivocal FISH results (ratio of 1.8–2.2) were considered as negative for *HER-2/neu* and *EGFR* gene amplification, respectively.[24] Polysomy 7 and 17 were defined as three or more *CEP* signals per cell.[21,25,26] Stromal cells and normal breast epithelial cells served as an internal control.

SNP Array Karyotyping

SNP array karyotyping was performed on selected cases. Following tumor enrichment through manual microdissection, DNA was obtained from 10-μm paraffin sections according to a previously described protocol for de-paraffinization and DNA extraction.[27] Samples were processed with the 250K Nsp Assay Kits (Affymetrix, Santa Clara, CA, USA). Briefly, 1 μg of gDNA was digested with *Nsp* restriction enzyme, ligated to the adaptors and amplified by PCR using a universal primer. After purification of PCR products with SNP Clean magnetic beads (Agencourt Biosciences, Beverly MA, USA), amplicons were quantified, fragmented, labeled and hybridized to 250K *Nsp* arrays. After washing and staining, the arrays were scanned to generate CEL files for downstream analysis.

Data acquired from the Affymetrix GeneChip Operating System v4.0 (GCOS) was analyzed using Affymetrix Gene-Chip Genotyping Analysis Software (GTYPE) 4.1. Copy number analysis was performed with Copy Number Analyzer for Affymetrix Gene-Chip arrays (CNAG 3.0), as described before.[28]

Statistical Analysis

Where appropriate, χ^2-test/Fisher's exact test or nonparametric tests (Mann–Whitney *U*-test) were used for comparisons of the groups. Spearman's correlation rank was applied for the correlation between the variables. All statistical analysis was carried out using the Statistical Package for the Social Sciences version 17.0 (SPSS, Chicago, IL, USA). *P*-values of <0.05 were considered significant.

Results

Classification and Steroid Receptor Profile of Apocrine Carcinomas

Morphologically, all 55 cases fulfilled the criteria for apocrine carcinoma and were characterized by large cells with prominent eosinophilic, flocculent cytoplasm, sharp cell borders and large nuclei with prominent macronucleoli (Figures 1a and b). Of these, 38 cases (69%) also fulfilled immunophenotypic diagnostic requirements for pure apocrine carcinoma: ER and PR negative, AR positive (Figures 1c and e, Table 1). The 17 remaining cases (31%) were then termed 'apocrine-like' carcinomas because they lacked the specific apocrine immunophenotypic profile (Figures 1d and f). These were further subcharacterized as apocrine-like carcinomas with ER+/AR− immunophenotype (three cases), apocrine-like carcinomas with ER−/AR− immunophenotype (four cases) and apocrine-like carcinomas with ER+/AR+ immunophenotype (10 cases) (Table 1).

The mean tumor AR positivity was significantly higher in the pure apocrine carcinoma subgroup in comparison with the apocrine-like carcinoma AR+/ER+ subgroup (76 *vs* 59%, $P=0.037$). Pure apocrine carcinomas exhibited a diffuse and strong nuclear staining of AR (16 of 30 or 53% of pure apocrine carcinomas had a 100% cells expressing AR). In contrast, none of the 17 apocrine-like carcinoma cases exhibited such complete AR expression.

HER-2/neu Expression in Apocrine Carcinomas

Her-2/neu protein overexpression (score 3+) was observed in 54% of the cases in the entire cohort without significant difference between the pure apocrine carcinoma and apocrine-like carcinoma groups (57 *vs* 47%, $P=0.81$) (Figure 1g).

HER-2/neu gene amplification was detected in 28 of 54 tested cases (52%) without significant differences between the pure apocrine carcinoma and the apocrine-like carcinoma group (54 *vs* 46%, $P=0.42$) (Figure 2a). The average *HER-2/neu* gene signal number per cell ranged from 1.67 to 50 (mean: 9.57). *HER-2/neu* FISH results were concordant with *Her-2/neu* immunohistochemistry results in 49 of 53 available cases (92%). Four positive immunohistochemistry Her-2/neu results (score 3+) were discordant with *HER-2* FISH results (negative for *HER-2/neu* gene amplification). Three of eight cases (38%) with equivocal immunohistochemistry (score 2+) had *HER-2/neu* gene amplification.

Figure 1 (**a** and **b**) Hematoxylin and eosin -stained sections of two cases of breast carcinomas with apocrine features: pure apocrine carcinoma (**a**) and apocrine-like carcinoma (**b**) (×40 magnification). (**c** and **d**) Immunohistochemistry showing negative estrogen receptor expression in a case of pure apocrine carcinoma with a positive staining of normal epithelium (**c**), and strongly positive expression in an apocrine-like breast carcinoma (**d**) (×10 magnification). (**e** and **f**) Immunohistochemistry showing diffusely positive androgen receptor expression in a case of a pure apocrine carcinoma (**e**), and negative expression in an apocrine-like carcinoma (**f**) (×20 magnification). (**g** and **h**) Immunohistochemistry showing strong membrane expression of EGFR protein in a case of pure apocrine carcinoma (**g**), and 3+ membrane expression of Her-2/neu protein in a case of apocrine-like breast carcinoma (**h**) (×20 magnification).

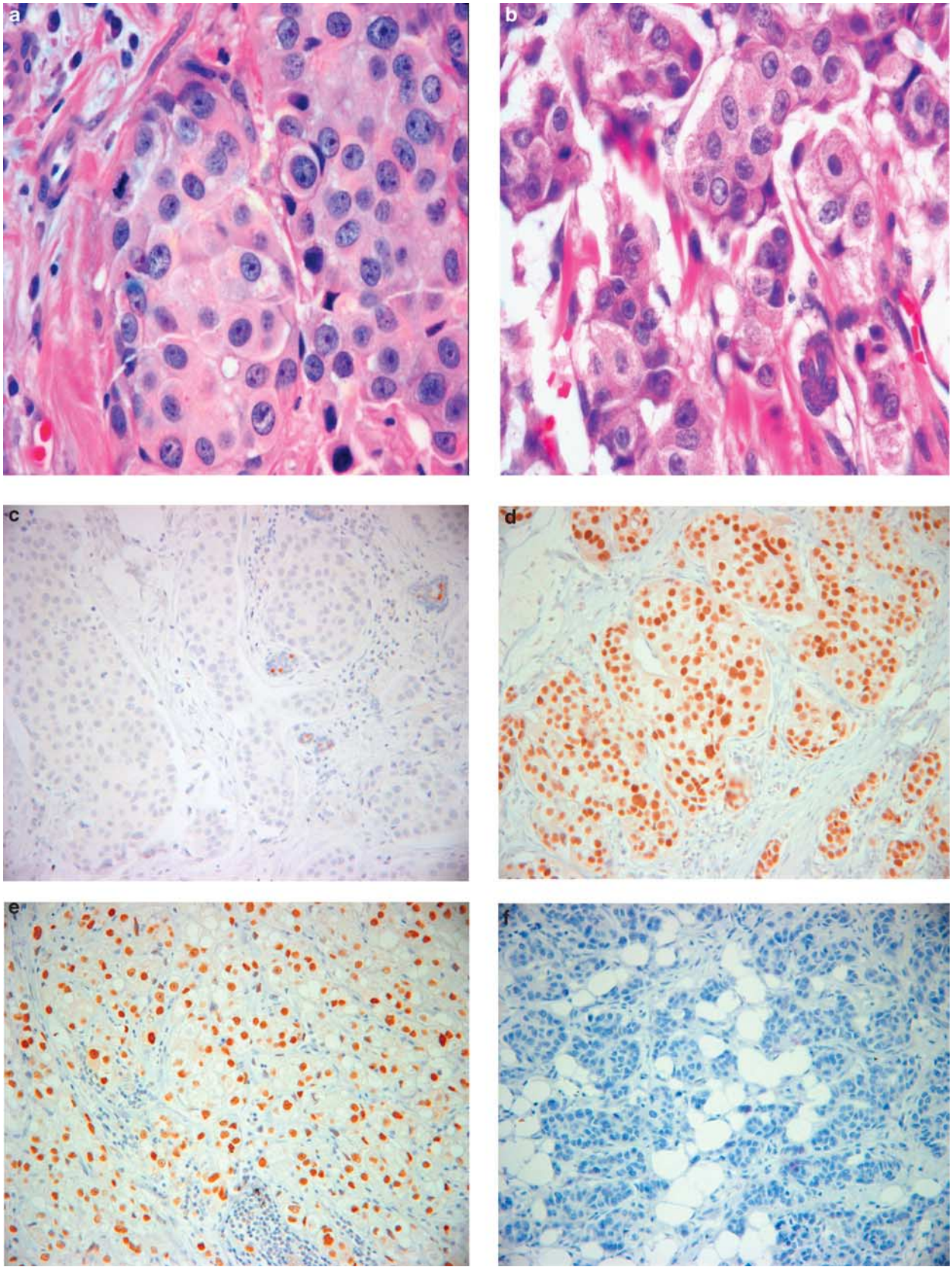
a
b
c
d
e
f

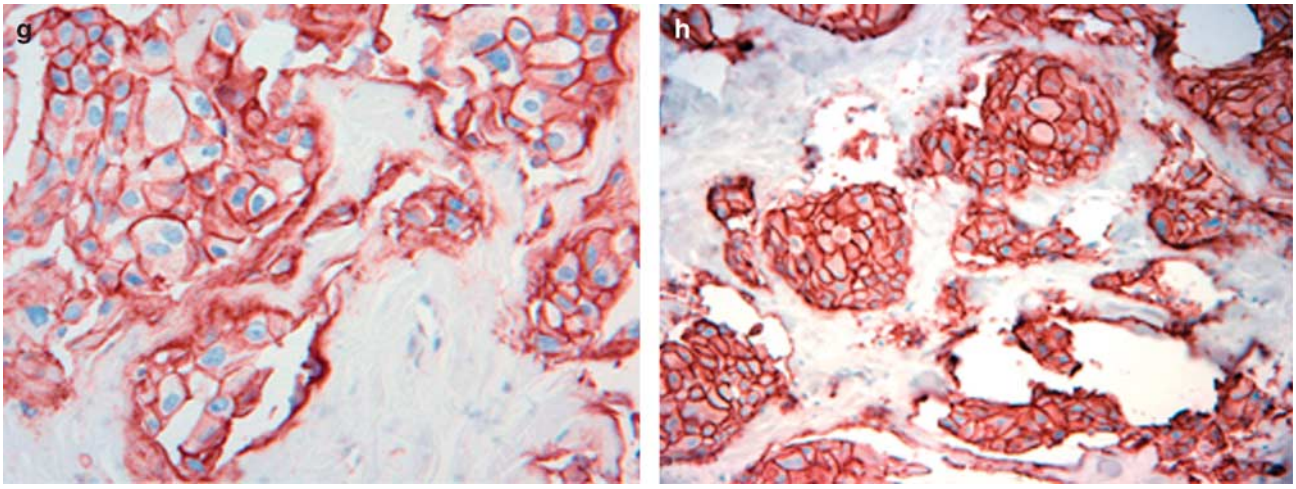

Figure 1 Continued.

Table 1 Status of EGFR and Her-2/neu protein expression and gene amplification in pure apocrine carcinomas and subgroups of apocrine-like carcinomas

Category	*Androgen r eceptor (AR)*[a]	*Her-2/neu*[b]	*HER-2/neu (FISH)*[c]	*EGFR*[d]	*EGFR (FISH)*[c]
Pure apocrine carcinomas	38/38 (100%) Mean: 76 Range: 10–100	21/37 (57%)	20/37 (54%)	29/38 (76%)	2/35 (6%)
Apocrine-like carcinomas (ER+, AR+)	10/10 (100%) Mean: 59 Range: 15–90	2/10 (20%)	4/10 (40%)	3/10 (30%)	1/7 (14%)
Apocrine-like carcinomas (ER+, AR−)	0/3 (0%)	3/3 (100%)	3/3 (100%)	0/3 (0%)	0/1 (0%)
Apocrine-like carcinomas (ER−, AR−)	0/4 (0%)	3/4 (75%)	1/4 (25%)	2/4 (50%)	0/4 (0%)

[a]Positivity defined if >10% cells exhibited nuclear staining.
[b]Defined by the 3+ score by immunohistochemistry.
[c]Defined by the gene to centromere ratio >2.2.
[d]Scores 1 to 3+ by immunohistochemistry.

Six samples had fewer *HER-2/neu* signals per cell than signals for chromosome 17 centromere (ratio: 0.72–0.99). One of these cases had a Her-2/neu protein overexpression.

Polysomy of chromosome 17 (defined as three or more copies of CEP17 signals per nucleus) was observed in 10 pure apocrine carcinomas (32%) and 8 apocrine-like carcinomas (50%). Polysomy 17 was seen without *HER-2/neu* gene amplification in 8 cases (Figure 2c) and with *HER-2/neu* gene amplification in 10 cases. The polysomy 17 rate was low: mean 3.55 CEP17 signals; (range: 3.0–6.0). Two pure apocrine carcinomas and three apocrine-like carcinomas (5 of 8, 63%) with polysomy 17 alone had Her-2/neu protein expression scores of 2 to 3+ by immunohistochemistry.

EGFR Expression in Apocrine Carcinomas

In all, 34 out of 55 (62%) cases expressed EGFR protein (scores 1 to 3+). A significantly higher proportion of pure apocrine carcinomas was positive for EGFR protein in comparison with the apocrine-like carcinoma subgroups (76 *vs* 29%, $P=0.006$) (Figure 1h). A diffuse (>50% of positive cells) and strong (intensity scores 2 to 3+) EGFR expression was seen in 20 of 29 (69%) of the pure apocrine carcinoma-positive cases and in 5 out of 5 (100%) of the apocrine-like carcinoma-positive cases.

EGFR gene amplification was a rare event present only in three (two pure apocrine and one apocrine-like tumors) of 44 studied cases (7%) (Figure 2b). All three cases exhibited EGFR protein overexpression. The average *EGFR* gene signal number per cell ranged from 1.6 to 20 (mean: 5.76).

Polysomy of chromosome 7 (defined as three or more copies of CEP7 signals per nucleus) was detected in 20 of 33 pure apocrine carcinomas (61%) and in 3 of 11 apocrine-like carcinomas (27%) either alone (21 cases) (Figure 2d) or in association with the *EGFR* gene amplification (two cases). Polysomy 7 was more frequently observed in the pure apocrine carcinoma subgroup compared with

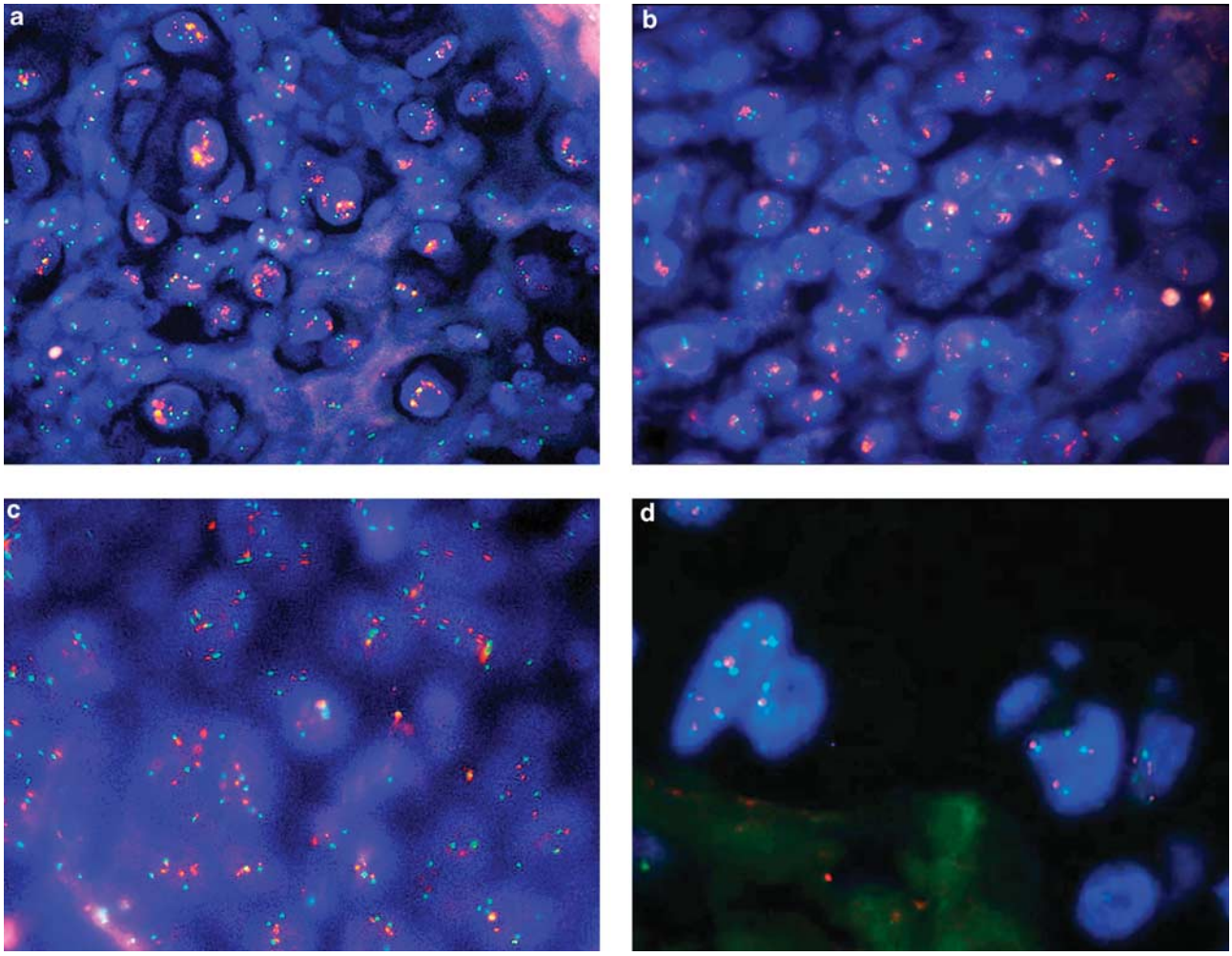

Figure 2 Pure apocrine carcinomas showing *HER-2/neu* gene amplification (**a**), *EGFR* gene amplification (**b**), polysomy 17 (CEP17) without *HER-2/neu* gene amplification in a case of an apocrine-like carcinoma (average: 6.06 signals per cell) (**c**) and polysomy 7 (CEP7) without *EGFR* gene amplification (average: 3.62 signals per cell) (**d**).

the apocrine-like carcinoma subgroup ($P = 0.083$). Overall, the level of polysomy 7 was low (mean: 4.09, range: 3.0–7.06). A weak positive correlation between polysomy 7 and the EGFR protein expression was also present ($P = 0.025$, $r = 0.326$).

Chromosomal Analysis Using Conventional Cytogenetics and SNP Array Assay

Corroborative genetic evidence for FISH results was obtained in three cases, which were further studied by conventional cytogenetics and SNP arrays. One case of pure apocrine carcinoma (displaying polysomy 7 (4.37 *CEP7* copies on average) and *HER-2/neu* gene amplification) was analyzed by conventional cytogenetic analysis (see Acknowledgement) and showed complex cytogenetic alterations (Figure 3) described as: 65–69,XXX, + i(1)(q10), −2,−3,add(3)(p12),add(6) (q27), + 7,−8,−10,−11,add (11)(p15),add(11)(q23),−12,−13,add(14)(p11.2),−15, +16,−17,−18,−19,add(19)(q13.4),−520,−21,−22,

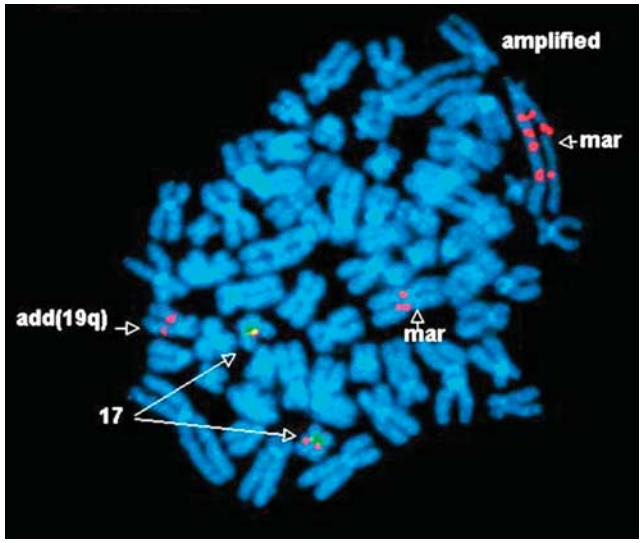

Figure 3 Metaphase FISH analysis of the apocrine carcinoma showing amplification of the *HER-2/neu* gene (red). One of the larger marker chromosomes contains homogeneously staining region (hsr) of *HER-2/neu* gene amplification.

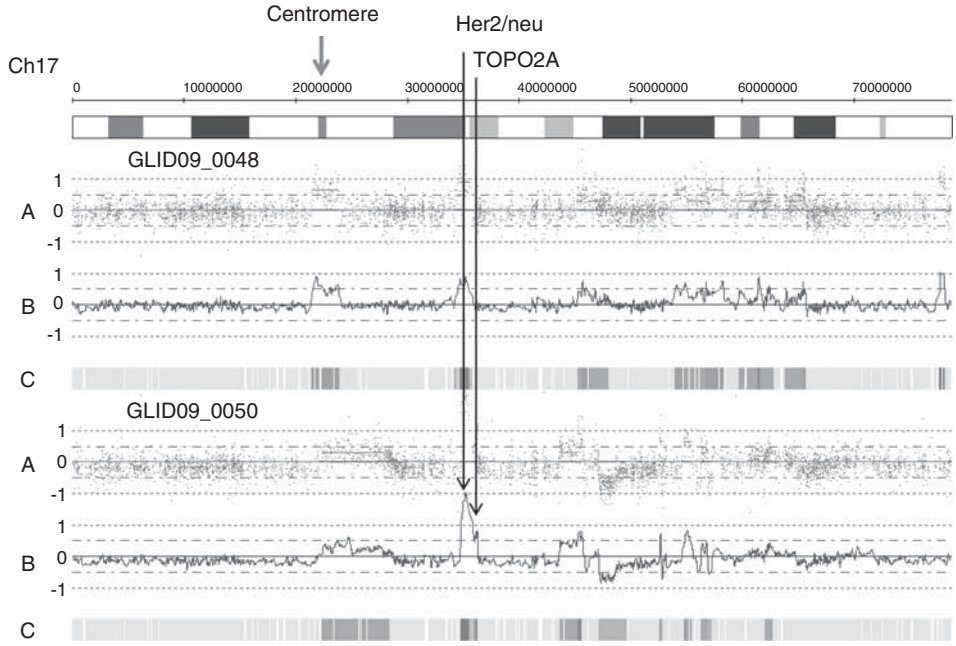

Figure 4 SNP array karyotypes of chromosome 17 for two samples with amplification of *HER-2/neu*. The first one (Sample GLID09_0048) had amplification of both *CEP17* and *HER-2/neu* amplification without polysomy 17, whereas the second one (Sample GLID09_0050) had coamplification of *HER-2/neu* and *TOP2A* along with a gain of *CEP17*. Plots are as follows: (A) the raw log 2 ratio of tumor/normal for each probe on the array; (B) smoothing average over 10 probes; and (C) Hidden Markov Model of copy number with aqua = 1, yellow = 2, pink = 3, pink-red = 4, red-pink = 5 and red > 5.

+mar1, + mar2, + mar3, + mar4, + mar5, + 5-8mar[5]/130–138, idemx2[2]/46,XX[13]. Another two cases (one pure apocrine carcinoma and one apocrine-like carcinoma, both with *HER-2/neu* gene amplification) were studied by SNP arrays, which confirmed FISH results and further revealed amplification of *CEP17* without polysomy 17 in the first one, whereas the second one (Sample GLID09_0050) had coamplification of *HER-2/neu* and *TOP2A* along with a gain of *CEP17* (Figure 4).

Molecular Subclassification of Carcinomas with Apocrine Morphology

We found a statistically significant inverse correlation between EGFR and Her-2/neu expression in the pure apocrine carcinoma subgroup ($P = 0.006$, $r = -0.499$). Therefore, 20 of 37 (54%) pure apocrine carcinoma cases can be classified as HER-2-overexpressing, whereas the remaining 17 cases (46%) as triple-negative breast carcinomas. In all, 16 out of 17 triple-negative pure apocrine carcinomas (94%) overexpressed EGFR and would accordingly be classified as basal-like breast carcinomas[29] (Table 2). None of the pure apocrine carcinomas fulfilled the criteria for luminal tumors.[29–31]

In contrast, a large proportion of apocrine-like carcinomas belonged to the luminal group (13 of 17 cases, 76%). Only three cases (18%) could be classified as triple-negative breast carcinomas and one case only as HER-2-overexpressing breast carcinoma.

Table 2 Molecular subclassification of apocrine carcinoma subtypes

Apocrine carcinoma subtype	*Molecular phenotype*
Pure apocrine carcinoma	HER-2 (20/37, 54%)[a] Triple negative (17/37, 46%) Basal-like breast carcinoma[b] (16/17, 94%)
Apocrine-like carcinoma	Luminal (13/17, 76%) Triple negative (3/17, 18%) Basal-like breast carcinoma[b] (2/3, 67%) HER-2 (1/17, 6%)

[a]*HER-2/neu* gene amplification was used as a criterion.
[b]On the basis of EGFR protein expression (Nielsen *et al*[29]).

Discussion

The diagnosis of apocrine carcinoma of the breast has been controversial because of the lack of strict diagnostic criteria. With the increasing use of immunohistochemistry, apocrine breast cancer differentiation has shown a consistent pattern of steroid receptor expression irrespective of grade[8] and this method should be applied for unequivocal

definition of this special carcinoma type. With such consistency, additional correlations between the histological phenotype and biological potential become more meaningful.

In this study, we applied strict morphological and immunohistochemical criteria to correctly classify and characterize apocrine carcinoma of the breast. Consequently, our results clearly separated breast tumors with apocrine cytomorphology into two different groups: the pure apocrine carcinomas with consistent lack of ER and overexpression of AR, and morphologically apocrine-like carcinomas that did not exhibit the protein expression profile associated with the true apocrine phenotype.[4,5,13,32] Similarly, Celis *et al*[8] using another set of morphological and immunohistochemical criteria for classification of apocrine carcinoma defined and confirmed the existence of a distinct apocrine carcinoma group with a consistent steroid receptor profile (ER−, AR+). Together, these results strongly support the recent advances in molecular classification of breast carcinoma that have revealed the existence of a specific 'molecular apocrine' gene expression profile among ER-negative breast carcinomas characterized primarily by increased AR signaling, along with a common Her-2/neu gene amplification.[13] The pure apocrine carcinoma subgroup from our study seems to be equivalent to the 'molecular apocrine' group from Farmers' study although that cohort was not entirely compatible with pure apocrine carcinomas.[13] Our findings showing coexpression of AR and Her-2/neu proteins in pure apocrine carcinomas also support results of other studies that highlighted a functional cross-talk and association between AR and *HER-2/neu* in a subset of breast carcinomas and breast carcinoma cell lines.[17,33]

Pure apocrine carcinomas were further characterized by nearly mutually exclusive expression of Her-2/neu and EGFR proteins. Thus, a majority of HER-2-negative cases (that is, triple-negative apocrine carcinomas) overexpressed EGFR and accordingly could be classified as basal-like breast carcinomas.[29–31] On the other hand, HER-2-overexpressing pure apocrine carcinomas were mostly negative for EGFR protein expression.

The apocrine-like carcinomas were much more heterogeneous with various combinations of steroid receptor expression including AR. Apocrine-like carcinomas are characterized by a common ER expression and *HER-2/neu* gene amplification but significantly less common EGFR overexpression, thus mainly belonging to the luminal phenotypes (A and B) according to the molecular classification of breast carcinomas.[30,31] It is noteworthy that of the remaining four ER-negative apocrine-like carcinomas, only one case had *HER-2/neu* gene amplification.

Our results suggest that a strict definition of pure apocrine carcinomas could clarify some of the previous contradictions in the classification of apocrine carcinoma (variable and heterogeneous gene expression profiles of morphologically defined apocrine tumors) leading some investigators to challenge its existence.[18]

Overexpression of Her-2/neu protein has been reported in up to 25% of invasive breast carcinomas and has been associated with a worse clinical outcome.[34] In most cases, this can be attributed to amplification of the *HER-2/neu* gene located on the long arm of chromosome 17 (17q12).[35] Our study revealed *HER-2/neu* gene amplification in ~52% of the cases, similar to the rate of *HER-2/neu* gene amplification in invasive apocrine carcinomas of the breast observed in two previously published small cohorts (44 and 50%, Moinfar *et al*[12] and Varga *et al*,[36] respectively). The pure apocrine carcinoma subgroup exhibited slightly higher rate of *HER-2/neu* gene amplification in comparison with the apocrine-like carcinoma subgroup, but the difference was not statistically significant. This is in line with previous studies, which demonstrated a strong association between *HER-2/neu* status and apocrine differentiation.[13,37] Although we found a high degree of concordance between immunohistochemistry and FISH results, four cases were negative for *HER-2/neu* gene amplification despite high protein expression on immunohistochemistry, which was previously explained by various preanalytical and analytical factors including tissue fixation, a choice of the anti-Her-2/neu antibody and scoring system.[37,38]

Aneusomy 17, including polysomy 17, has been a common observation in breast carcinomas,[39,40] although the definition of polysomy 17 is not universally defined.[24] Therefore, we followed the arbitrary cutoff of three or more copies of CEP17 applied in previous publications.[22,25,26] Our FISH analysis revealed polysomy 17 in a proportion of apocrine carcinomas, either as the sole finding or in combination with *HER-2/neu* gene amplification. *CEP17* polysomy without concomitant *HER-2/neu* gene amplification was seen in eight cases of which five had Her-2/neu protein overexpression (scores 2+ and 3+). Several investigators previously considered polysomy 17 a potential cause of equivocal HER-2/neu results by FISH or immunohistochemistry.[25] However, Vanden Bempt *et al*[22] found neither increased Her-2/neu protein nor increased *HER-2 mRNA* in polysomy 17 cases and concluded that the tumors displaying unamplified polysomy 17 probably represented more Her-2/neu-negative than Her-2/neu-positive breast tumors. Some investigators recently questioned the interpretation of the *CEP17* copy number as a reliable predictor of the entire chromosome 17 polysomy,[41] and our whole genome analysis using SNP arrays in two cases also supports this observation.

EGFR is a 170-kDa transmembrane glycoprotein encoded by the *HER-1* protooncogene, located at 7p11.2-p12.[42] High expression of EGFR in a variety of epithelial tumors has led to the development of a number of drugs specifically targeting the EGFR that are now in use for treatment of advanced colorectal carcinoma, non-small cell lung carcinoma, head and

neck squamous cell carcinoma and pancreatic carcinoma.[43] EGFR protein expression has also been a common finding in breast carcinoma, particularly in a subgroup of triple-negative, basal-like breast carcinomas (>50%) leading some investigators to use it as a surrogate marker for a basal-like breast carcinoma.[29] However, *EGFR* gene alterations (activating mutations and gene amplification) tend to be a rare event in breast carcinoma and were found in <8% of the cases.[44,45] In this study, we demonstrated EGFR protein expression in 62% of the cases. The expression pattern was predominantly strong (scores 2 to 3+) and diffuse (>50% of positive cells) in both subgroups and was not accompanied by the *EGFR* gene amplification, similar to the results of a study by Park *et al.*[45] Polysomy of chromosome 7 (*CEP7*), which we found associated with the pure apocrine carcinoma subgroup, is a novel finding, not previously associated with apocrine breast cancer.[46–49] It also correlated and might be responsible for the EGFR protein overexpression in the pure apocrine carcinoma.

In summary, our study indicates that breast carcinomas with apocrine differentiation are heterogeneous in molecular terms. The combination of morphological and immunohistochemical criteria are essential for the proper identification of pure apocrine carcinomas. When strictly defined, these carcinomas express either Her-2/neu or EGFR in a nearly exclusive manner, resulting in their classification as either HER-2-overexpressing or triple-negative types of breast carcinomas. In contrast, apocrine-like carcinomas predominantly belong to the luminal molecular phenotype (both A and B). Our findings also demonstrate that *EGFR* and *HER-2/neu* have important roles in the pathogenesis of apocrine carcinomas and these findings may have significant therapeutic implications.

Acknowledgements

The conventional cytogenetic study was performed at the Human Genetics Laboratory, Munroe Meyer Institute, University of Nebraska Medical Center, Omaha, NE, USA; we thank Dr Warren Sanger, Dr Julia Bridge and Ms Marilu Nelson for the excellent report and providing us with the Figure 3. We are also indebted to Kay M Krogman, Department of Pathology, Creighton University School of Medicine, for technical assistance. Dr Semir Vranic was a research fellow at the Creighton University Medical Center, Omaha, NE, USA, and had been supported by the UICC American Cancer Society Beginning Investigators Fellowship (ACSBI) award (ACS/08/004) funded by the American Cancer Society. The preliminary results of the study were presented at the 96th Annual Meeting of the United States and Canadian Academy of Pathology, San Diego, CA, USA, 2007.

Disclosure/conflict of interest

The authors declare no conflict of interest.

References

1 O'Malley FP, Bane A. An update on apocrine lesions of the breast. Histopathology 2008;52:3–10.
2 Celis JE, Gromova I, Gromov P, *et al.* Molecular pathology of breast apocrine carcinomas: a protein expression signature specific for benign apocrine metaplasia. FEBS Lett 2006;580:2935–2944.
3 Tavassoli FA, Devilee P, (eds). World Health Organization Classificaiton of Tumours. Pathology and Genetics of Tumours of the Breast and Female Genital Organs. IARC Press: Lyon, 2003.
4 Gatalica Z. Immunohistochemical analysis of apocrine breast lesions. Consistent over-expression of androgen receptor accompanied by the loss of estrogen and progesterone receptors in apocrine metaplasia and apocrine carcinoma *in situ*. Pathol Res Pract 1997; 193:753–758.
5 Tavassoli FA, Purcell CA, Bratthauer GL, *et al.* Androgen receptor expression along with loss of bcl-2, ER, and PR expression in benign and malignant apocrine lesions of the breast: implications for therapy. Breast J 1996;2:261–269.
6 Leal C, Henrique R, Monteiro P, *et al.* Apocrine ductal carcinoma *in situ* of the breast: histologic classification and expression of biologic markers. Hum Pathol 2001;32:487–493.
7 Masood S, Rosa M. The challenge of apocrine proliferations of the breast: a morphologic approach. Pathol Res Pract 2009;205:155–164.
8 Celis JE, Cabezon T, Moreira JM, *et al.* Molecular characterization of apocrine carcinoma of the breast: Validation of an apocrine protein signature in a well-defined cohort. Mol Oncol 2009;3:220–237.
9 Nicolás Díaz-Chico B, Germán Rodríguez F, González A, *et al.* Androgens and androgen receptors in breast cancer. J Steroid Biochem Mol Biol 2007;105:1–15.
10 Isola JJ. Immunohistochemical demonstration of androgen receptor in breast cancer and its relationship to other prognostic factors. J Pathol 1993;170:31–35.
11 Bratthauer GL, Lininger RA, Man YH, *et al.* Androgen and estrogen receptor mRNA status in apocrine carcinomas. Diagn Mol Pathol 2002;11:113–118.
12 Moinfar F, Okcu M, Tsybrovskyy O, *et al.* Androgen receptors frequently are expressed in breast carcinomas. Cancer 2003;98:703–711.
13 Farmer P, Bonnefoi H, Becette V, *et al.* Identification of molecular apocrine breast tumours by microarray analysis. Oncogene 2005;24:4660–4671.
14 Doane AS, Danso M, Lal P, *et al.* An estrogen receptor-negative breast cancer subset characterized by a hormonally regulated transcriptional program and response to androgen. Oncogene 2006;25:3994–4008.
15 Kreike B, van Kouwenhove M, Horlings H, *et al.* Gene expression profiling and histopathological characterization of triple-negative/basal-like breast carcinomas. Breast Cancer Res 2007;9:404.
16 Sanga S, Broom BM, Cristini V, *et al.* Gene expression meta-analysis supports existence of molecular apocrine breast cancer with a role for androgen receptor and implies interactions with ErbB family. BM Med Genomics 2009;2:59.

17 Naderi A, Hughes-Davies L. A functionally significant cross-talk between androgen receptor and erbB2 pathways in estrogen receptor negative breast cancer. Neoplasia 2008;10:542–548.
18 Weigelt B, Horlings HM, Kreike B, *et al.* Refinement of breast cancer classification by molecular characterization of histological special types. J Pathol 2008;216: 141–150.
19 Kaya H, Bozkurt SU, Erbarut I, *et al.* Apocrine carcinomas of the breast in Turkish women: hormone receptors, c-erbB-2 and p53 immunoexpression. Pathol Res Pract 2008;204:367–371.
20 Matsuo K, Fukutomi T, Hasegawa T, *et al.* Histological and immunohistochemical analysis of apocrine breast carcinoma. Breast Cancer 2002;9:43–49.
21 Chan SK, Hill ME, Gullick WJ. The role of the epidermal growth factor receptor in breast cancer. J Mammary Gland Biol Neoplasia 2006;11:3–11.
22 Vanden Bempt I, Van Loo P, Drijkoningen M, *et al.* Polysomy 17 in breast cancer: clinicopathologic significance and impact on HER-2 testing. J Clin Oncol 2008;26:4869–4874.
23 Honma N, Sakamoto G, Akiyama F, *et al.* Breast carcinoma in women over the age of 85: distinct histological pattern an androgen, oestrogen, and progesterone receptor status. Histopathology 2003; 42:120–127.
24 Wolff AC, Hammond ME, Schwartz JN, *et al.* American Society of Clinical Oncology/College of American Pathologists guideline recommendations for human epidermal growth factor receptor 2 testing in breast cancer. J Clin Oncol 2007;25:118–145.
25 Krishnamurti U, Hammers JL, Atem FD, *et al.* Poor prognostic significance of unamplified chromosome 17 polysomy in invasive breast carcinoma. Mod Pathol 2009;22:1044–1048.
26 Varshney D, Zhou YY, Geller SA, *et al.* Determination of HER-2 status and chromosome 17 polysomy in breast carcinomas comparing HercepTest and PathVysion FISH assay. Am J Clin Pathol 2004;121:70–77.
27 Lyons-Weiler M, Hagenkord J, Sciulli CM, *et al.* Optimization of the Affymetrix GeneChip mapping 10 K 2.0 assay for routine clinical use on formalin fixed paraffin embedded tissues. Diagn Mol Pathol 2008; 17:3–13.
28 Monzon FA, Hagenkord J, Lyons-Weiler M, *et al.* Whole genome SNP arrays as a potential diagnostic tool for the detection of characteristic chromosomal aberrations in renal epithelial tumors. Mod Pathol 2008;21:599–608.
29 Nielsen TO, Hsu FD, Jensen K, *et al.* Immunohistochemical and clinical characterization of the basal-like subtype of invasive breast carcinoma. Clin Cancer Res 2004;10:5367–5374.
30 Sørlie T, Perou CM, Tibshirani R, *et al.* Gene expression patterns of breast carcinomas distinguish tumor subclasses with clinical implications. Proc Natl Acad Sci USA 2001;98:10869–10874.
31 Perou CM, Sørlie T, Eisen MB, *et al.* Molecular portraits of human breast tumours. Nature 2000;406:747–752.
32 Moe RE, Anderson BO. Androgens and androgen receptors: a clinically neglected sector in breast cancer biology. J Surg Oncol 2007;95:437–439.
33 Agoff SN, Swanson PE, Linden H, *et al.* Androgen receptor expression in estrogen receptor-negative breast cancer. Immunohistochemical, clinical, and prognostic associations. Am J Clin Pathol 2003; 120:725–731.
34 Slamon D, Clark G, Wong S, *et al.* Human breast cancer: correlation of relapse and survival with amplification of the HER-2/neu oncogene. Science 1987;235:177–182.
35 Sauter G, Lee J, Bartlett JM, *et al.* Guidelines for human epidermal growth factor receptor 2 testing: biologic and methodologic considerations. J Clin Oncol 2009;27:1323–1333.
36 Varga Z, Zhao J, Öhlschlegel C, *et al.* Preferential HER-2/neu overexpression and/or amplification in aggressive histological subtypes of invasive breast cancer. Histopathology 2004;44:332–338.
37 Bhargava R, Striebel J, Beriwal S, *et al.* Prevalence, morphologic features and proliferation indices of breast carcinoma molecular classes using immunohistochemical surrogate markers. Int J Clin Exp Pathol 2009;2:444–455.
38 Gown AM, Goldstein LC, Barry TS, *et al.* High concordance between immunohistochemistry and fluorescence *in situ* hybridization testing for HER2 status in breast cancer requires a normalized IHC scoring system. Mod Pathol 2008;21:1271–1277.
39 Watters AD, Going JJ, Cooke TG, *et al.* Chromosome 17 aneusomy is associated with poor prognostic factors in invasive breast carcinoma. Breast Cancer Res Treat 2003;77:109–114.
40 Wang S, Saboorian MH, Frenkel EP, *et al.* Aneusomy 17 in breast cancer: Its role in HER-2/neu protein expression and implication for clinical assessment of HER-2/neu status. Mod Pathol 2002;15:137–145.
41 Yeh IT, Martin MA, Robetorye RS, *et al.* Clinical validation of an array CGH test for HER2 status in breast cancer reveals that polysomy 17 is a rare event. Mod Pathol 2009;22:1169–1175.
42 Hynes NE, Lane HA. ERBB receptors and cancer: the complexity of targeted inhibitors. Nature Rev Cancer 2005;5:341–354.
43 Laurent-Puig P, Lievre A, Blons H. Mutations and response to epidermal growth factor receptor inhibitors. Clin Cancer Res 2009;15:1133–1139.
44 Bhargava R, Gerald WL, Li AR, *et al.* EGFR gene amplification in breast cancer: correlation with epidermal growth factor receptor mRNA and protein expression and HER-2 status and absence of EGFR-activating mutations. Mod Pathol 2005;18:1027–1033.
45 Park K, Han S, Shin E, *et al.* EGFR gene and protein expression in breast cancers. Euro J Surg Oncol 2007;33:956–960.
46 Corzo C, Tusquets I, Salido M, *et al.* Characterization of HER1 (c-erbB1) status in locally advanced breast cancer using fluorescence *in situ* hybridization and immunohistochemistry. Tumour Biol 2005;26:25–30.
47 Kapranos N, Kounelis S, Karantasis H, *et al.* Numerical aberrations of chromosomes 1 and 7 by fluorescent *in situ* hybridization and DNA ploidy analysis in breast cancer. Breast J 2005;11:448–453.
48 Sauer T, Beraki K, Jebsen PW, *et al.* Numerical abnormalities of chromosome 7 in interphase cell nuclei of breast carcinoma have no impact on immunohistochemically determined EGFR status. APMIS 1999;107:211–216.
49 Gwin K, Lezon-Geyda K, Harris L, *et al.* Chromosome 7 aneusomy in metaplastic breast carcinomas with chondroid, squamous, and spindle-cell differentiation. Int J Surg Pathol 2009; doi:10.1177/1066896909334127.