Baština Akademije nauka i umjetnosti Bosne i Hercegovine

Zbornik radova "Međunarodni naučni simpozij FETALNA MEDICINA: OD LEONARDA DA VINCIJA DO DANAS"

Mesihović Dinarević, Senka

2015

Akademija nauka i umjetnosti Bosne i Hercegovine

https://bastina.anubih.ba/items/8f3700c3-bf6b-4ef7-b1a2-46fa77969d19

Preuzeto s Baštine Akademije nauka i umjetnosti Bosne i Hercegovine

https://bastina.anubih.ba/

DOI: 10.5644/PI2015-159.03

SCREENING TESTS FOR FETAL CHROMOSOMAL AND STRUCTURAL ABNORMALITIES

Nataša Tul[5]

Department of Perinatology, Divison of Obstetrics and Gynecology
University medical center Ljubljana, Slovenia

Abstract

Fetal chromosomal and structural abnormalities are one of major causes of perinatal mortality and morbidity. Screening for fetal chromosomal and structural abnormalities is an important part of prenatal care today in the parts of the world where economical situation permit it.

Today, first trimester biochemical and ultrasound screening is "gold standard" in prenatal care in many countries in Europe and other parts of the world. If done in a standardized way, it permits high detection of chromosomal and structural fetal anomalies between 11-14 gestational weeks. Pre and post-test counseling must be available for all pregnant women.

The aims of second trimester scans, which are performed between 18 and 24 week of gestation, are to determine fetal biometry and anatomy, to detect structural abnormalities and (re)assess risk for chromosomal abnormalities by checking for soft markers and to asses risk for preterm delivery by measuring cervix of the uterus and for preecplampsia by assessment of uterine arteries Doppler.

Key words: screening test, abnormalities

Introduction

Fetal chromosomal and structural abnormalities are one of major causes of perinatal mortality and morbidity. Screening for fetal chromosomal and structural abnormalities is an important part of prenatal care today in the parts of the world where economical situation permit it.

The main tool for detection of fetal abnormalities is ultrasound (US) examination. According to current recommendations in Slovenia, we routinely offer to all pregnant women two US examinations – at the first prenatal

[5] Nataša Tul-Mandić, PhD, Department of Perinatology, Divison of Obstetrics and Gynecology, University medical center Ljubljana, Šlajmerjeva 3, SI – 1000 Ljubljana; e-mail: natasa.tul@kclj.si

visit in the mid-trimester, but majority of women have also scan at 11-14 weeks (so called "nuchal scan"). The last two, are the most important scans for screening and detecting fetal chromosomal and structural abnormalities.

Early first trimester scan

At the first prenatal visit, this is in majority of cases before 10th gestational week, US is done to diagnose:

- pregnancy location (intrauterine / extrauterine / unknown location)
- viability (presence of heart activity),
- number of embryos,
- chorionicity in cases of multiple pregnancies (number of gestational sacs, number of yolk sacs),
- duration of the pregnancy (dating). Gestational age is calculated from the first day of last menstrual period (LMP). Measuring embryo or fetus with US for estimation of duration of gestation is the most accurate before 14 week. Until 12-13 weeks, measuring crown-rump length (CRL) is very accurate. Changing estimated day of delivery is recommended only if US estimation is more than 7 days different that estimation by last menstrual period or in the cases of unknown LMP.
- assess organs in the maternal pelvis, mainly uterus and ovaries, to seek for abnormal masses.

All this data, together with detailed maternal general and obstetrical anamnesis, are very important for planning pregnancy care and further US examinations. Early scan in usually performed by transvaginal examination.

First trimester scan (11-14 weeks)

Main goals of scan at 11-14 weeks are to assess:

- number of fetuses,
- viability,
- chorionicity (number of placentas, lambda or tau/T sign (Figure 1). Chorionicity must be determined by 16 gestational week, later is less accurate),
- biometry (CRL, biparietal diameter, head and abdomen circumference, femur length for confirmation of the duration of pregnancy or re-dating in cases where US was not done before and estimation by US is more than 7 days different that estimation by LMP),
- assessment of basic fetal anatomy,
- assessment of risk for chromosomal abnormalities, mainly for trisomy 21 (T21).

By careful anatomic assessment, number of important major fetal abnormalities can be diagnosed at or after 11 weeks of gestation: acrania and anencephalia, holoprosencephaly, omphalocele, gastroschis, hydrops fetalis, cystic hygroma, gross limb defects and others. Suspicion of spina bifida can be raised by assessing intracranial translucency and of many other abnormalities by assessing anatomic land-marks and measuring fetus (ed diaphragmatic hernia, major heart and skeletal abnormalities, etc).

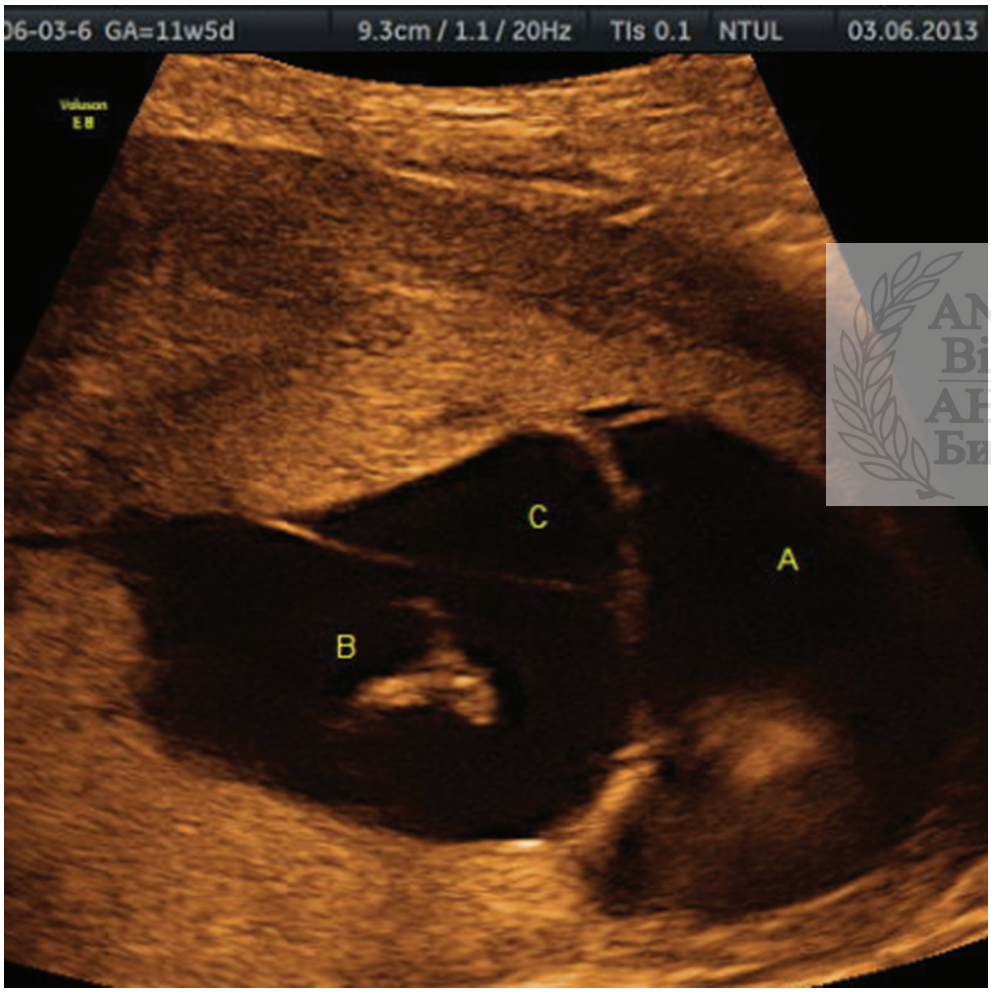

Figure 1: Ultrasound picture of trigemini at 11 weeeks and 5 days. This is a dichorionic triamniotic pregnancy. Membrane between fetus B and C is thin, we can se T sign – this are monochorionic twins. Membrane between fetus A and other two fetuses is thick, we can see λ sign, dichorionic pregnancy.

Screening for trisomy 21 and other chromosomal abnormalities

First prenatal diagnosis of trisomy 21 (T21) was done in 1968 by amniocentesis. Even today, diagnosis of chromosomal abnormalities can be made only by an invasive test, the most are chorionic villi sampling and amniocentesis. All the other tests are screening tests.

Prenatal screening for mainly T21 (but also other chromosomal abnormalities) was introduced in developed world in late 70-ies and 80-ies years of the XX century. It was based on maternal age.

At the same time, in UK, screening with α-feto-protein (AFP) for neural tube defects was introduced. This was the first population screening for fetal structural abnormalities. The discovery that APF is low in women caring fetuses with chromosomal abnormalities, lead to development of second trimester biochemical screening for chromosomal abnormalities in 2nd trimester at the end of 80-ies. Screening for structural abnormalities with 2nd trimester US examination started to be routine practice at that time. Few years later, first trimester biochemical screening for chromosomal abnormalities was introduced as very effective method, especially in combination with nuchal translucency (NT) (Table 1). With technological improvement and clinical knowledge, first trimester US examination became very efficient screening not only for chromosomal, but also for structural abnormalities.

Today, first trimester biochemical and US screening is "gold standard" in prenatal care in many countries in Europe and other parts of the world. If done in a standardized way, it permits high detection of chromosomal and structural fetal anomalies between 11-14 gestational weeks. Pre and post-test counseling must be available for all pregnant women.

Nuchal translucency (NT) is a structure behind the fetal neck (in the nuchal region) (Figure 2). Accurate measurements according to well defined standards available from Fetal Medicine Foundation (https://fetalmedicine.org/the-11-13-weeks-scan) provide an efficient screening and individual risk assessment for chromosomal abnormalities and can be a marker also for other genetic and structural fetal abnormalities (eg heart defects). It is very important to strictly follow recommendations from FMF to achieve good results.

In combination with other biochemical (free hCG, PAPP-A) and biophysical (nasal bone (Figure 2), ductus venosus and tricuspid valve assessment) markers, the detection of T21 can be > 90% for a low screen positive rate (3%).

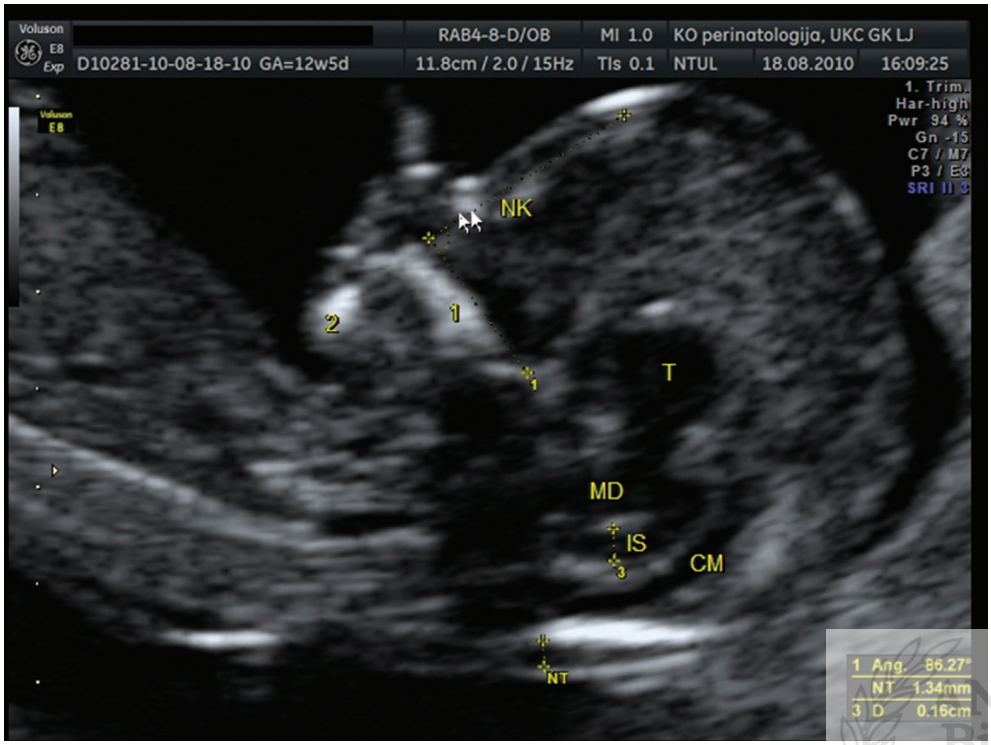

Figure 2: Sagital view of fetal head at 12 weeks. Assessment of 3 markers for chromosomal abnormalities (NT, NK, facial angle) and a marker for spina bifida (IS) is possible on this view. NK – nasal bone, marked with 2 arrows, 1 – upper jaw, 2 – lower jaw, NT – nuchal translucency, T – thalamus, MD – brainstem, IS – intracranial translucency = 4th ventricle, CM – cisterna magana. Facial angle is marked by small dots.

Table 1: Detection rate of trisomy 21 (T21) for different screening tests at 5% of screen positive rate: NT – nuchal translucency, hCG – free human chorionic gonadotrophin, PAPP-A – pregnancy associated plasma protein A.

Screening test	Detection rate of T21
Maternal age	30%
Maternal age + quadruple test in 2nd trimester	75%
Maternal age + NT	70-80%
Maternal age + NT + βhCG + PAPP-A	85-90%
Maternal age + NT + nasal bone	90%
Maternal age + NT + nasal bone + βhCG + PAPP-A	97%

In the last years, screening for most common chromosomal abnormalities with cell free fetal DNA (cffDNA) has been offered to many pregnant women. It is very efficient test, but again – pre and post-test counseling must

be done by highly educated personal and ultrasound examination should be done in all cases priors to test. Detailed ultrasound examination should be done to detect cases of structural, chromosomal or genetic abnormalities which cannot be detected by cffDNA, cases of multiple pregnancies, to asses risk for preterm delivery, preecplampsia. False positive results are very rare (< 0.5%), but must be confirmed by diagnostic test.

Second trimester scan

In general, second trimester scan is a scan at 14-28 weeks, but usually we mean 18-24 week scan. Main goals of scan at 18-24 weeks are to assess:

- number of fetuses (if not done before),
- viability,
- biometry (biparietal diameter, head and abdomen circumference, femur length),
- amniotic fluid assessment,
- placental position and appearance,
- assessment of fetal anatomy and soft markers for chromosomal abnormalities, mainly for T21.

We recommend also to measure cervical length (as a screening for preterm delivery) and to assess flow in uterine arteries by Doppler (screening for preeclampsia and growth restriction). At the end of the scan, all the standard structures must be visible (check lists are available). Absence of normally present structures or presence of an additional structure, abnormal biometry, abnormal amount of amniotic fluid, abnormal fetal movements rise a suspicion of abnormal development and must be evaluated in details.

References

1. https://fetalmedicine.org
2. www.openultrasound.com
3. Bromley B, Shipp TD, Lyons J, Navathe RS, Groszmann Y, Benacerraf BR. Detection of fetal structural anomalies in a basic first-trimester screening program for aneuploidy. J Ultrasound Med. 2014 Oct;33(10):1737-45
4. Nicolaides KH. Turning the pyramid of prenatal care. Fetal Diagn Ther. 2011;29(3):183-96
5. Salomon LJ, Alfirevic Z, Bilardo CM, Chalouhi GE, Ghi T, Kagan KO, Lau TK, Papageorghiou AT, Raine-Fenning NJ, Stirnemann J, Suresh S, Tabor A, Timor-Tritsch IE, Toi A, Yeo G. ISUOG practice guidelines: performance of first-trimester fetal ultrasound scan. Ultrasound Obstet Gynecol. 2013 Jan;41(1):102-13.
6. Salomon LJ, Alfirevic Z, Audibert F, Kagan KO, Yeo G, Raine-Fenning N; ISUOG Clinical Standards Committee. ISUOG consensus statement on the impact of non-invasive prenatal testing (NIPT) on prenatal ultrasound practice. Ultrasound Obstet Gynecol. 2014 Jul;44(1):122-3.

7. Salomon LJ, Alfirevic Z, Berghella V, Bilardo C, Hernandez-Andrade E, Johnsen SL, Kalache K, Leung KY, Malinger G, Munoz H, Prefumo F, Toi A, Lee W; ISUOG Clinical Standards Committee. Practice guidelines for performance of the routine mid-trimester fetal ultrasound scan. Ultrasound Obstet Gynecol. 2011 Jan;37(1):116-26.
8. International Society of Ultrasound in Obstetrics and Gynecology, Carvalho JS, Allan LD, Chaoui R, Copel JA, DeVore GR, Hecher K, Lee W, Munoz H, Paladini D, Tutschek B, Yagel S. ISUOG Practice Guidelines (updated): sonographic screening examination of the fetal heart. Ultrasound Obstet Gynecol. 2013 Mar;41(3):348-59.
9. Pergament E, Cuckle H, Zimmermann B, Banjevic M, Sigurjonsson S, Ryan A, Hall MP, Dodd M, Lacroute P, Stosic M, Chopra N, Hunkapiller N, Prosen DE, McAdoo S, Demko Z, Siddiqui A, Hill M, Rabinowitz M. Single-nucleotide polymorphism-based noninvasive prenatal screening in a high-risk and low-risk cohort. Obstet Gynecol. 2014 Aug;124(2 Pt 1):210-8.

Skrining testovi za fetalne hromozomske i strukturne abnormalnosti

Nataša Tul[6]

Univerzitetni klinični center Ljubljana. Ginekološka klinika.
Klinični oddelek za perinatologijo, Ljubljana, Slovenia

ANU BiH АНУ БиХ

Sažetak

Fetalne hromozomske i strukturne abnormalnosti su jedan od glavnih uzroka perinatalne smrtnosti i morbiditeta. Screening fetalnih hromozomskih i strukturnih abnormalnosti je važan dio prenatalne brige danas, u dijelovima svijeta gdje ekonomska situacija to dozvoljava.

Danas je biohemijski i ultrazvučni screening u prvom trimestru „zlatni standard“ u prenatalnoj njezi u mnogim zemljama Europe i drugim dijelovima svijeta. Ako se radi na standardiziran način, rezultira velikim brojem detektiranih kromosomskih i strukturnih fetalnih anomalija između 11. i 14. gestacijske nedjelje. Svim trudnicama mora se omogućiti savjetovanje prije i poslije testa.

Ciljevi skeniranja drugog trimestra, koje se obavljaju između 18. i 24. tjedna gestacije, jesu da se utvrdi fetalna biometrija i anatomija, odrede strukturne abnormalnosti i (ponovna) procjena rizika za hromosomne abnormalnosti provjerom soft markera te evaluacija rizika za prevremeni porođaj mjerenjem grlića maternice i preeklampsiju evaluacijom Dopplera uternih arterija.

Ključne riječi: screening test, abnormalnost

[6] Doc. dr. Nataša Tul-Mandić, dr. med., Univerzitetni klinični center Ljubljana, Ginekološka klinika, Klinični oddelek za perinatologijo, Šlajmerjeva 3, SI – 1000 Ljubljana; e-mail: natasa.tul@kclj.si