Baština Akademije nauka i umjetnosti Bosne i Hercegovine

Perspectives in Paediatric Cardiology: Perspektive u pedjatrijskoj kardiologiji

Mesihović Dinarević, Senka

2012

Akademija nauka i umjetnosti Bosne i Hercegovine

https://bastina.anubih.ba/items/ff7d5ad2-af81-4f1b-8490-552285003fe6

Preuzeto s Baštine Akademije nauka i umjetnosti Bosne i Hercegovine

https://bastina.anubih.ba/

Arterial Switch Operation for TGA with Coronary Artery Anomaly

Asc.Prof.Yusuf K. Yalcinbas
Prof. Dr. Tayyar Sarioglu

Acibadem Bakirkoy Hospital
Cardiovascular Surgery Department
Acıbadem University
Istanbul- Turkey

ACIBADEM



Arterial Switch
TGA & Coronary Patterns

First Neonetal Arterial Switch in
Turkey
October 1990
T.Sarıoglu,T.Paker,O.Bayındır, A.Sarıoglu



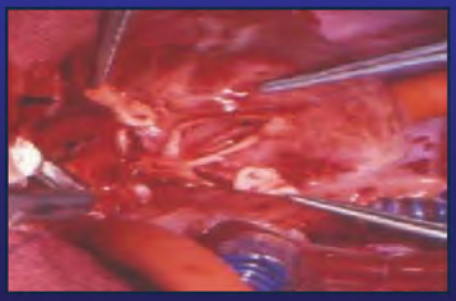

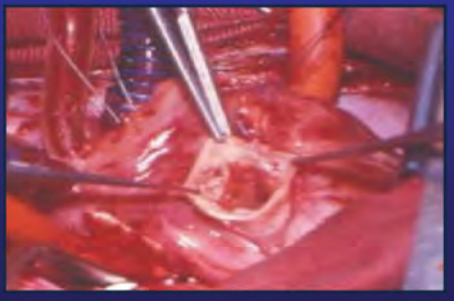

Arterial Switch

TGA & Coronary Patterns

Influences of coronary patterns on coronary translocation:

- Injury
- Torsion-Kinking
- Stretching
- Compression

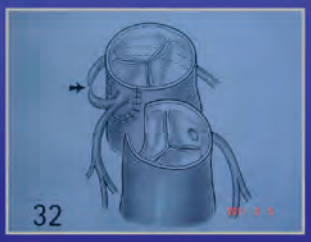

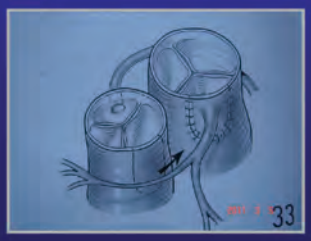

3

Arterial Switch

TGA & Coronary Patterns

Coronary pattern & possible risks ...

- Inverted coronary artery
- Intramural coronary artery
- Single left (LCA+RCA)
- Single right (RCA+LCA)

* Kirklin JW, Clinical outcomes after ASO Procedural & Institutional risk factors (513 neonates,CHSS). Circulation 1992
* Daebritz, Anatomical risk factors after ASO (312 patients, Aechen,Germany). Ann Thorac Surg., 2000
* Pasquali, Coronary artery pattern and outcome of ASO (Meta analysis of 9 studies, Duke University). Circulation 2002

4

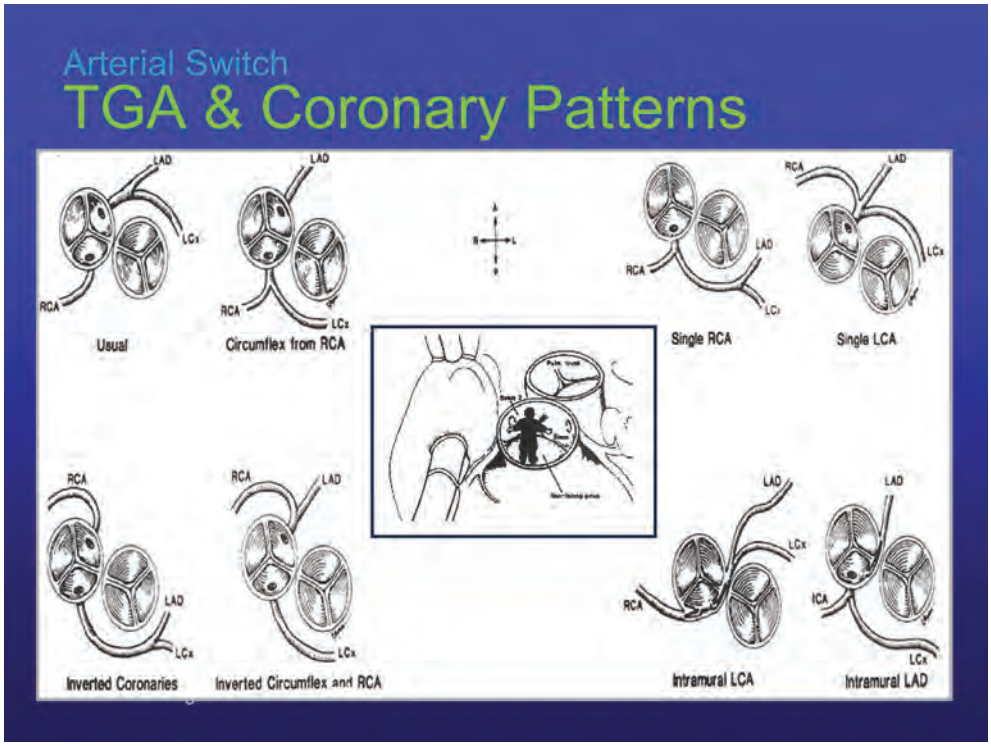
Arterial Switch
TGA & Coronary Patterns
LAD
LCx
RCA
Usual
Circumflex from RCA
Single RCA
Single LCA
Inverted Coronaries
Inverted Circumflex and RCA
Intramural LCA
Intramural LAD

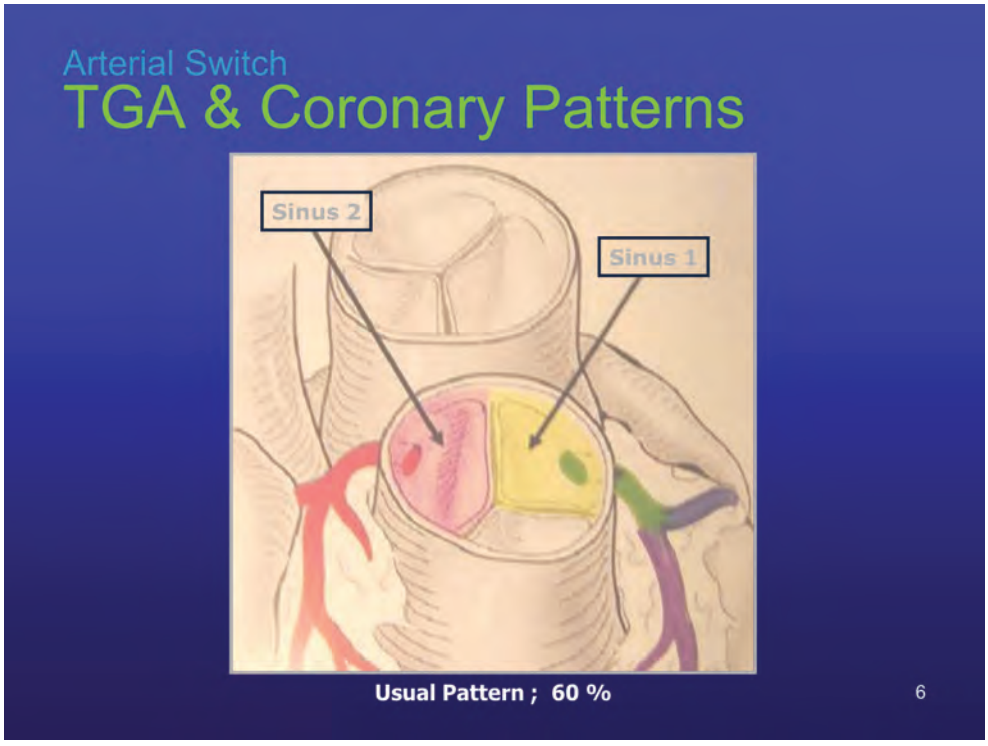
Arterial Switch
TGA & Coronary Patterns
Sinus 2
Sinus 1
Usual Pattern ; 60 %
6

Arterial Switch

TGA & Coronary Patterns

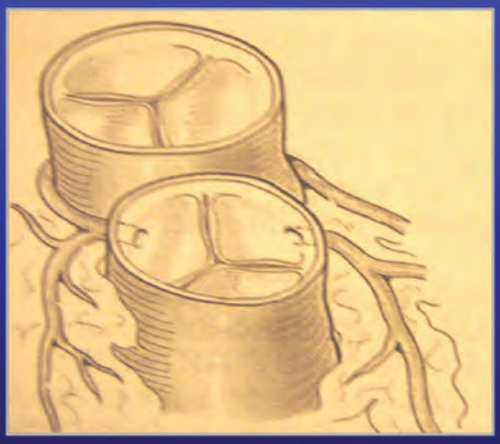

RCA+ CX from sinus-2 & LAD from sinus-1 (Posterior looping); 20 %

7

Arterial Switch

TGA & Coronary Patterns

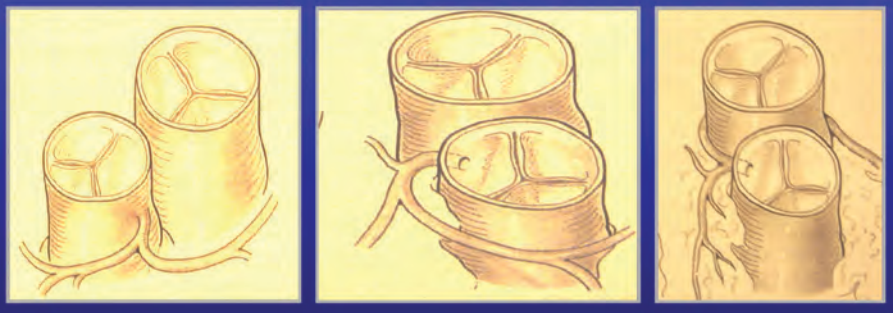

Single coronary (anterior & posterior looping) 5-6 %

8

Arterial Switch
TGA & Coronary Patterns

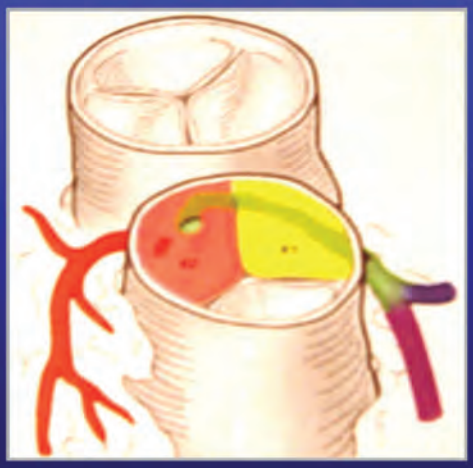

Single origin from sinus-2 (RCA+LCA, intramural course); 5 %

9

Arterial Switch
TGA & Coronary Patterns



Intramural course; 5 %

10

Arterial Switch
TGA & Coronary Patterns

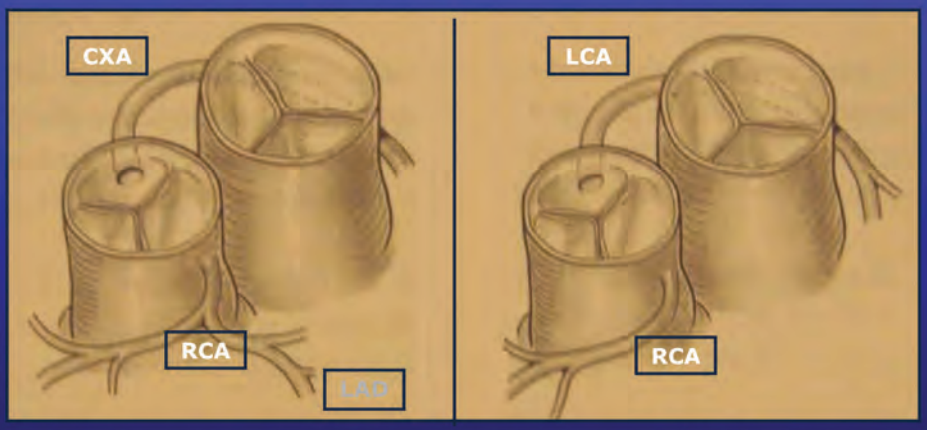

CXA from sinus-2, RCA+LCA from sinus-1

RCA from sinus-1, LCA from sinus-2

Inverted coronary pattern 8 %

11

Arterial Switch
TGA & Coronary Anomalies

Nomenculture	Sinus 1	Sinus 2	n	%
Usual	LAD, Cx	R	289	61
Circumflex from RCA	LAD	CxR	103	22
Single RCA		LADCxR	21	4
With additional small LAD from sinus 1			2	0,4
Single LCA	RLADCx		10	2
Inverted origins	R	LADCx	13	3
Inverted RCA/Cx	RLAD	Cx	19	4
Intramural LCA		LADCxR	9	2
Intramural LAD		LADCxR	3	0,6
Intramural RCA	LADCxR		1	0,2

CA in 470 patients undergoing ASO at Children's Hospital Boston (1983-1992)

12

Arterial Switch
TGA & Coronary Anomalies

TGA,VSD







13

Arterial Switch Repair
TGA & Coronary Pattern

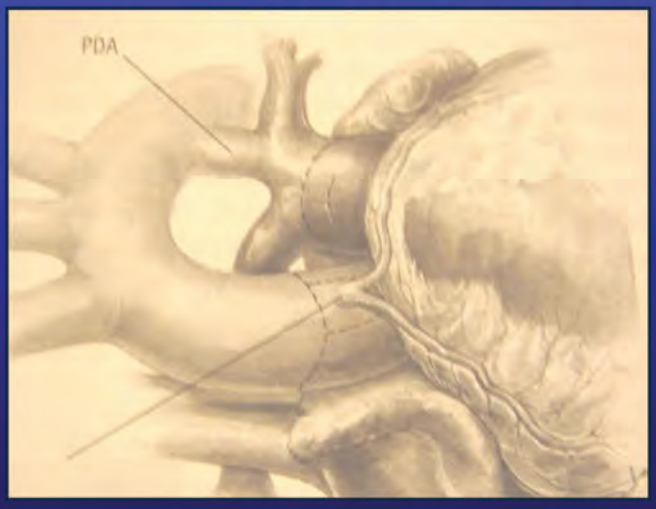





Single origin and translocation methods

14

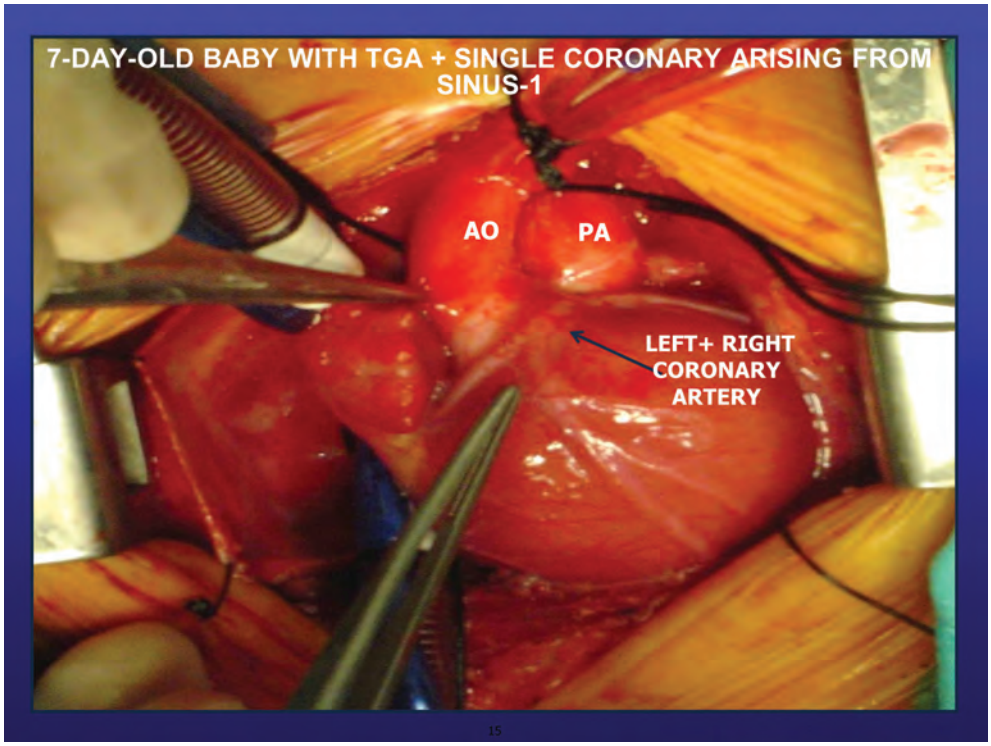
7-DAY-OLD BABY WITH TGA + SINGLE CORONARY ARISING FROM SINUS-1
AO
PA
LEFT+ RIGHT CORONARY ARTERY
15

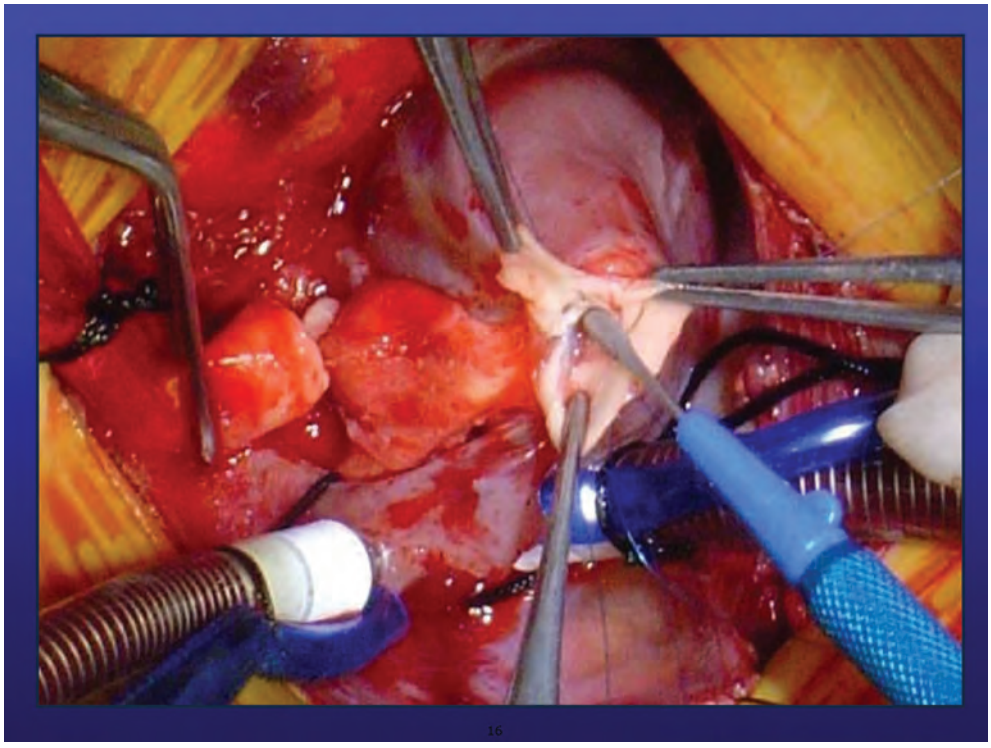
16

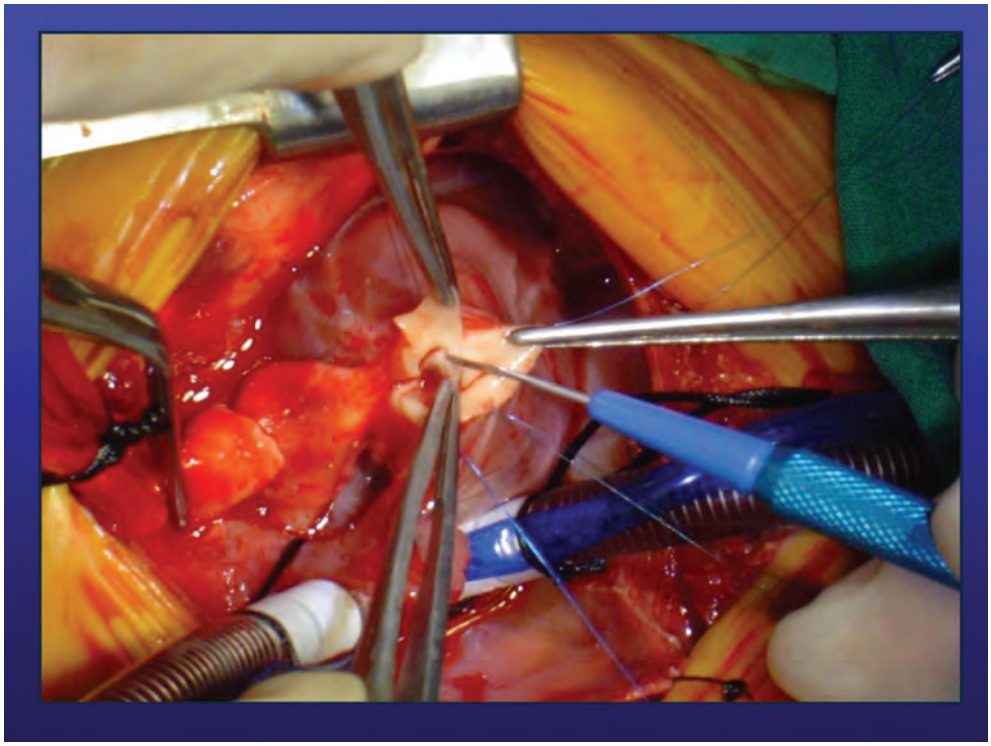

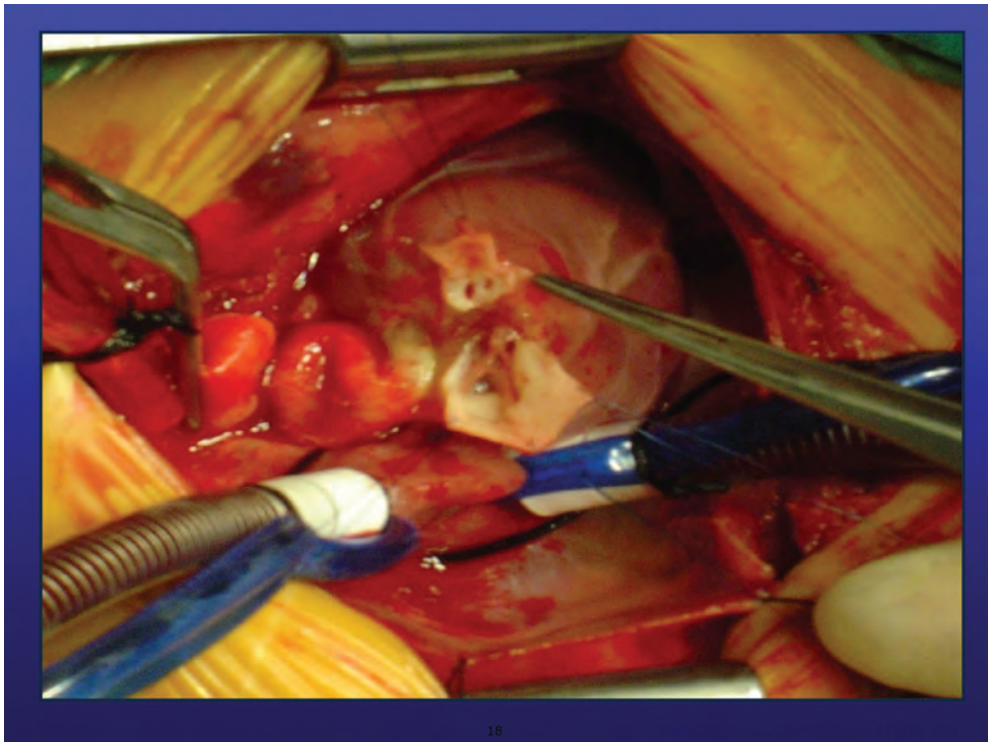

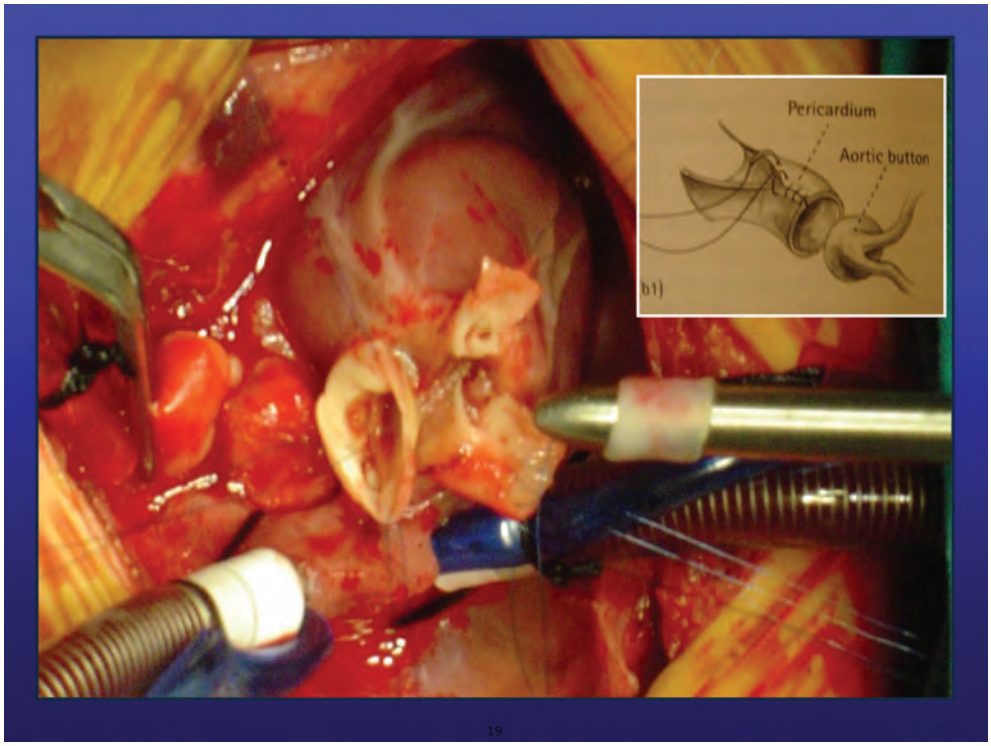
Pericardium
Aortic button
b1)
19

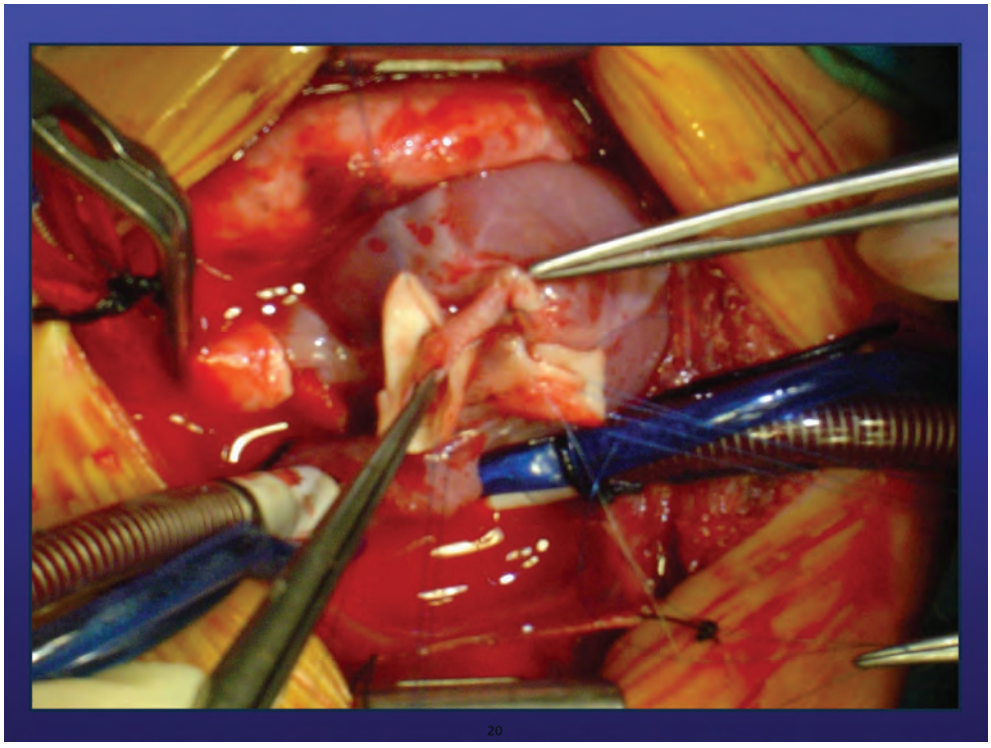
20

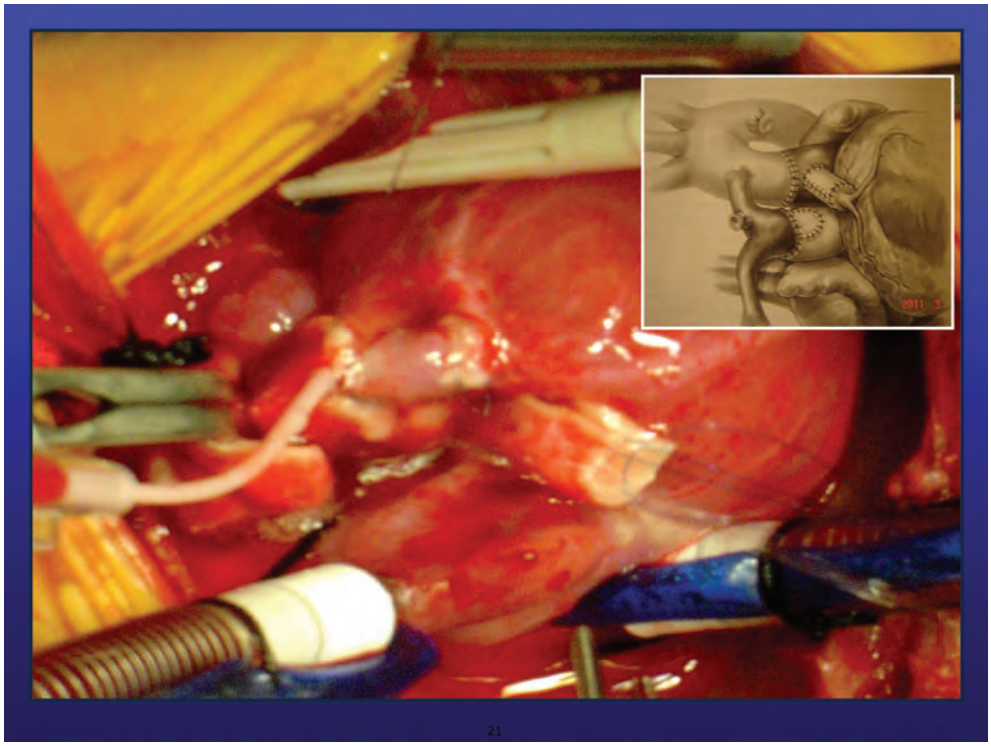

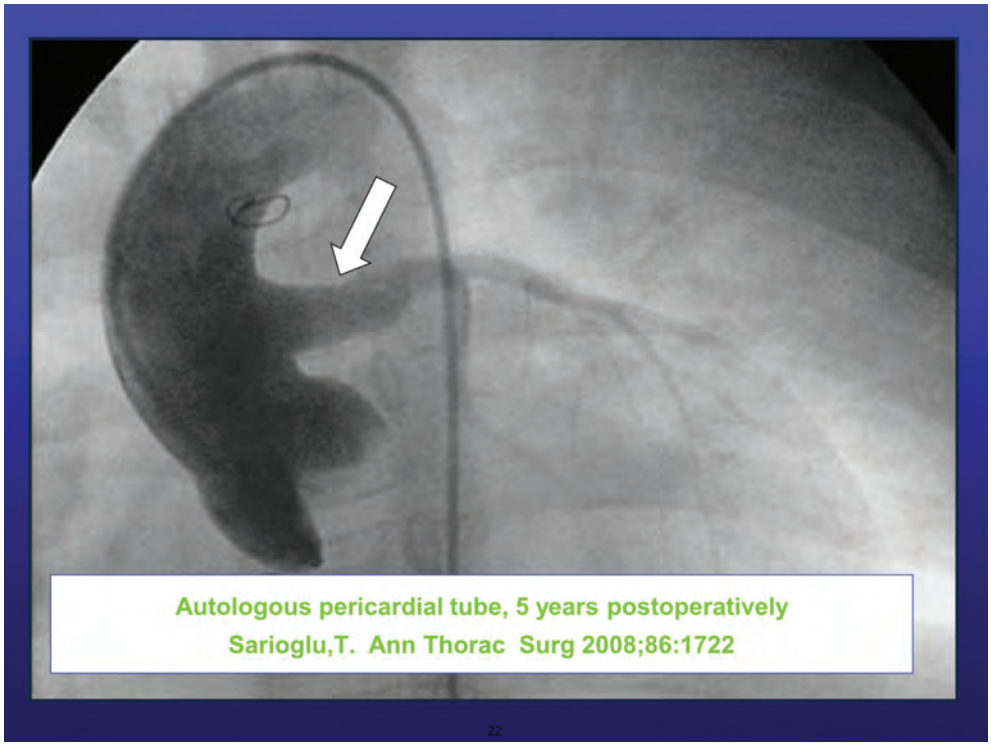
Autologous pericardial tube, 5 years postoperatively
Sarioglu,T. Ann Thorac Surg 2008;86:1722

Arterial Switch
TGA & Coronary Patterns

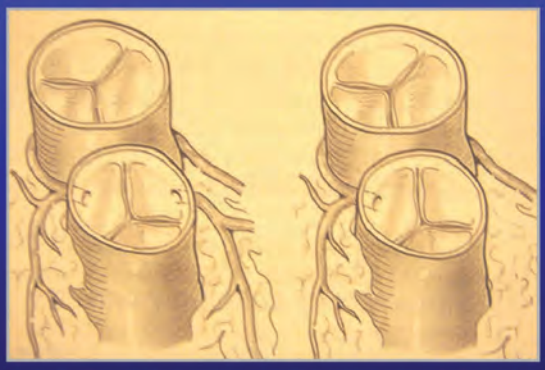

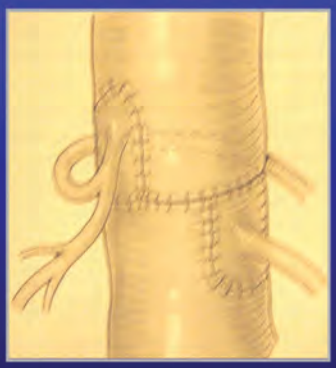

RCA+ CX from sinus-2 & LAD from sinus-1 (Posterior looping); 20 %

23

Arterial Switch
TGA & Coronary Patterns



Single coronary from sinus-2

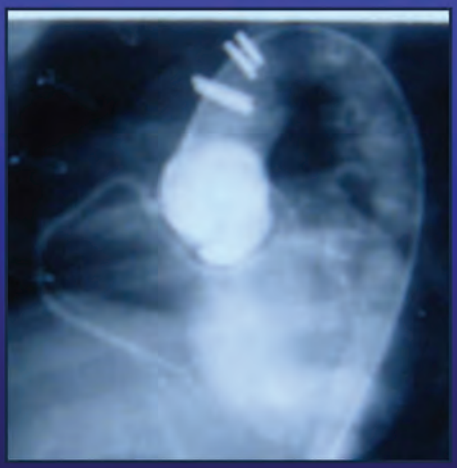

Coronary angio 1 year postoperatively

24

Arterial Switch

TGA & Coronary Patterns







Intramural course; 5 %

25

Arterial Switch

TGA, Intramural LAD from Sinus 2

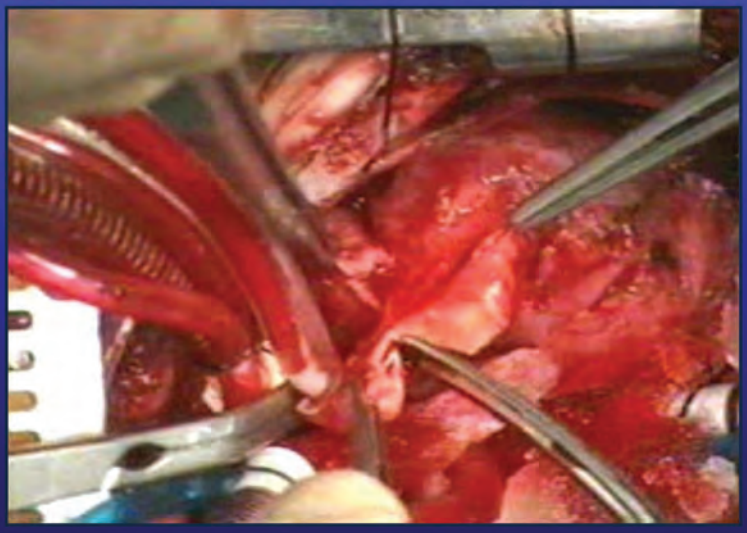

26

Arterial Switch

TGA, Intramural LAD from Sinus 2

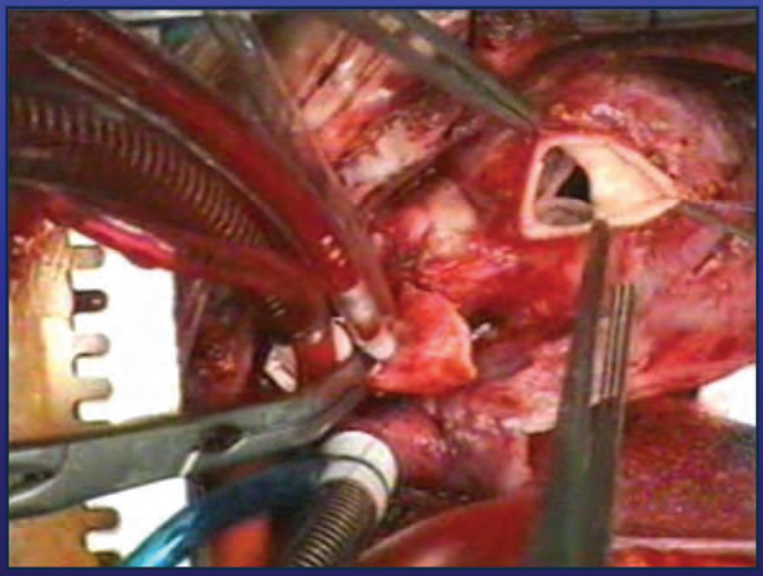

27

Arterial Switch

TGA, Intramural LAD from Sinus 2

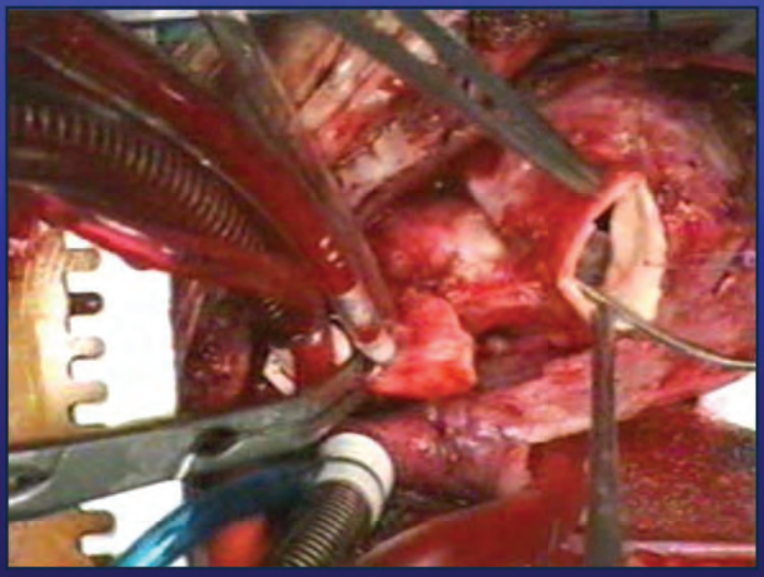

28

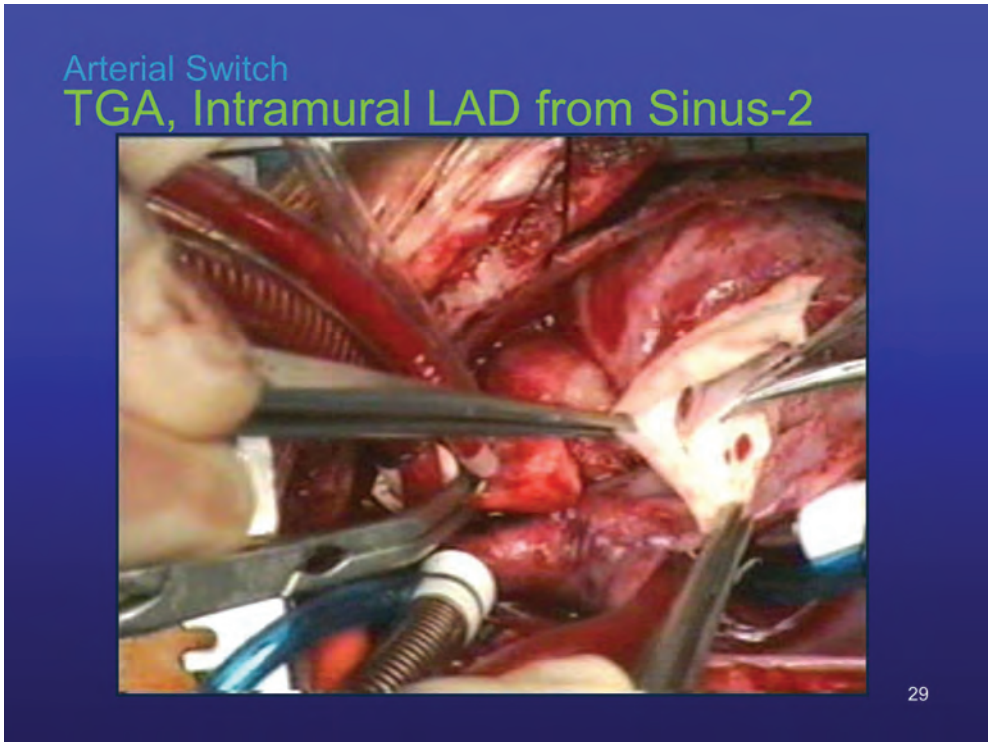
Arterial Switch
TGA, Intramural LAD from Sinus-2
29

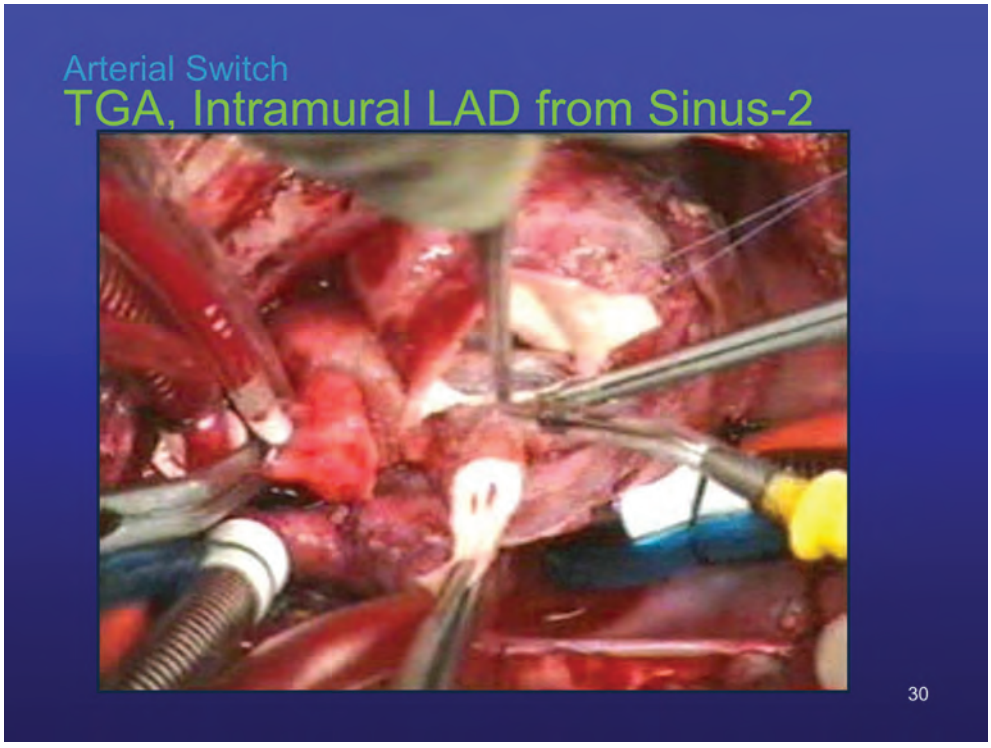
Arterial Switch
TGA, Intramural LAD from Sinus-2
30

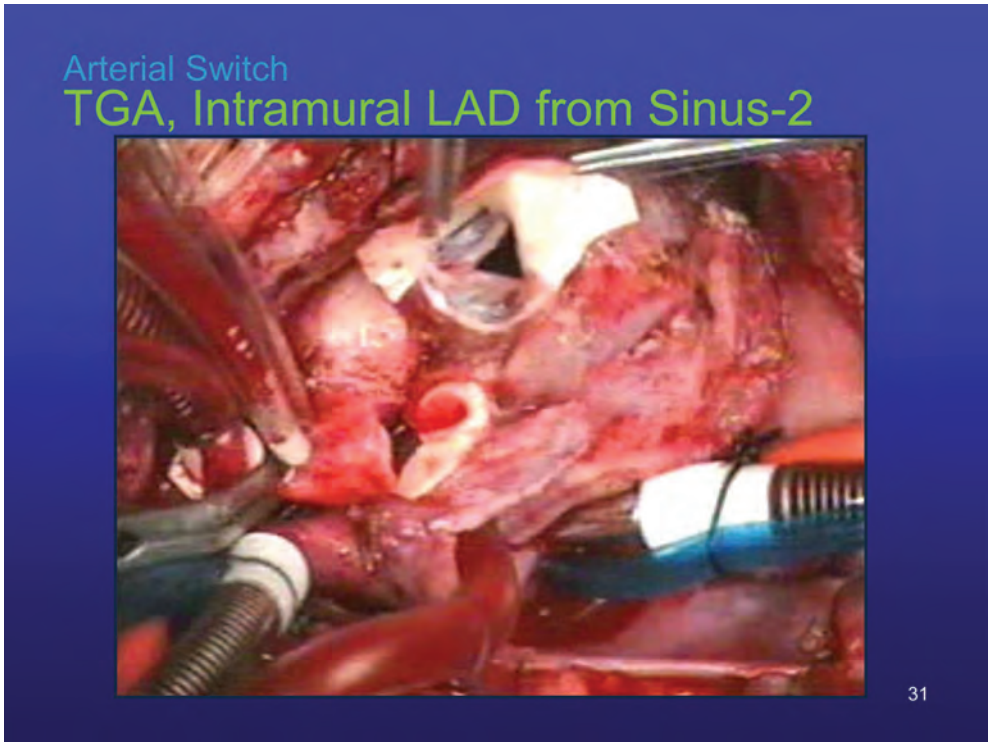
Arterial Switch
TGA, Intramural LAD from Sinus-2
31

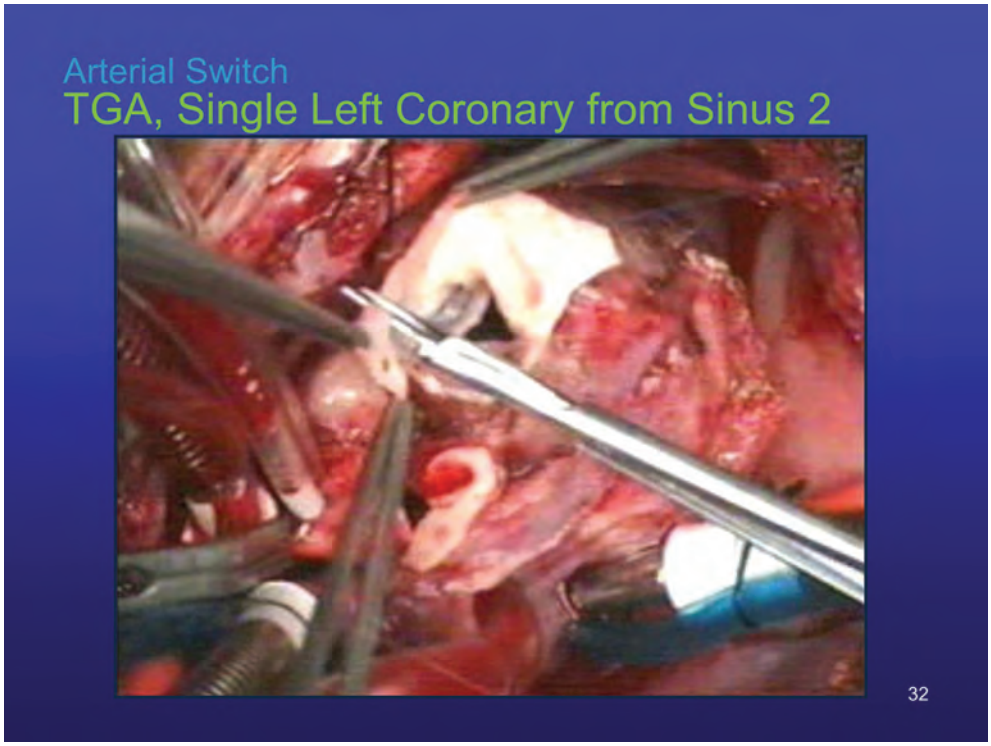
Arterial Switch
TGA, Single Left Coronary from Sinus 2
32

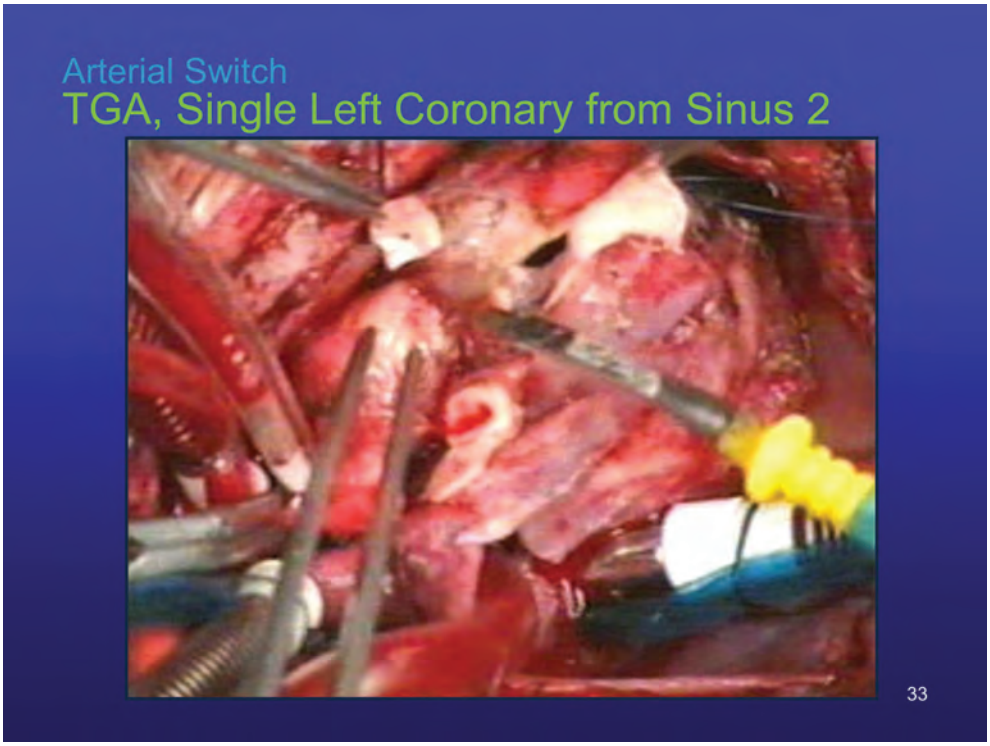
Arterial Switch
TGA, Single Left Coronary from Sinus 2
33

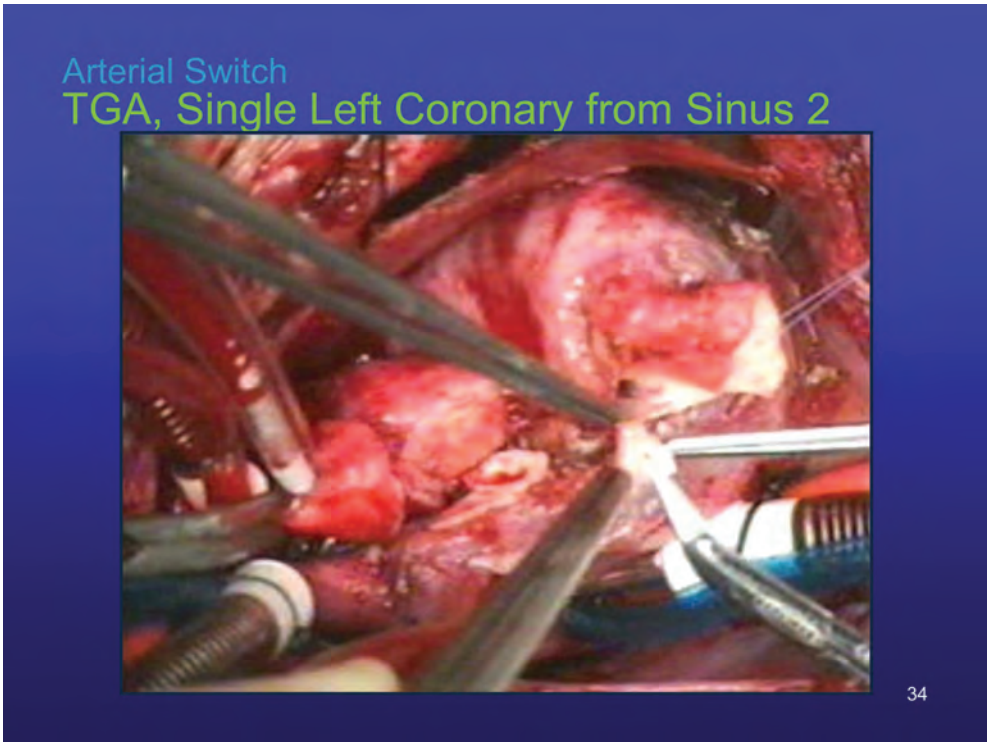
Arterial Switch
TGA, Single Left Coronary from Sinus 2
34

Arterial Switch
TGA, Single Left Coronary from Sinus 2

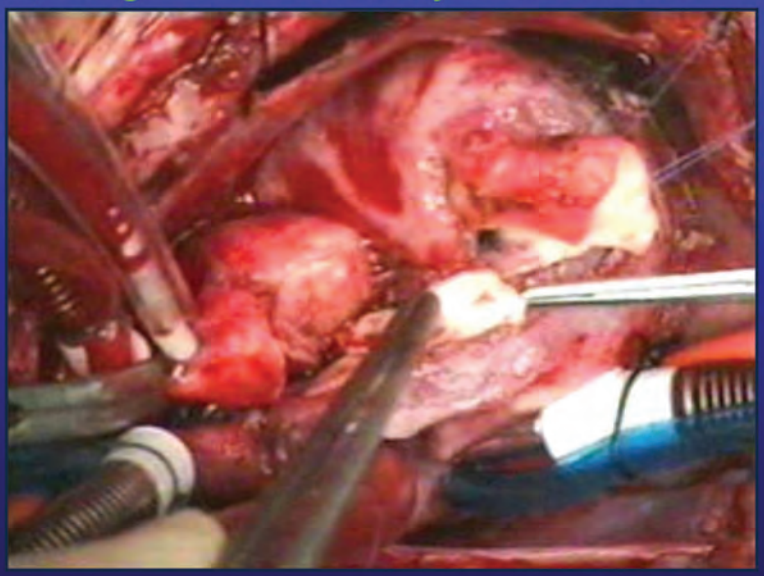

35

Arterial Switch
TGA, Single Left Coronary from Sinus 2

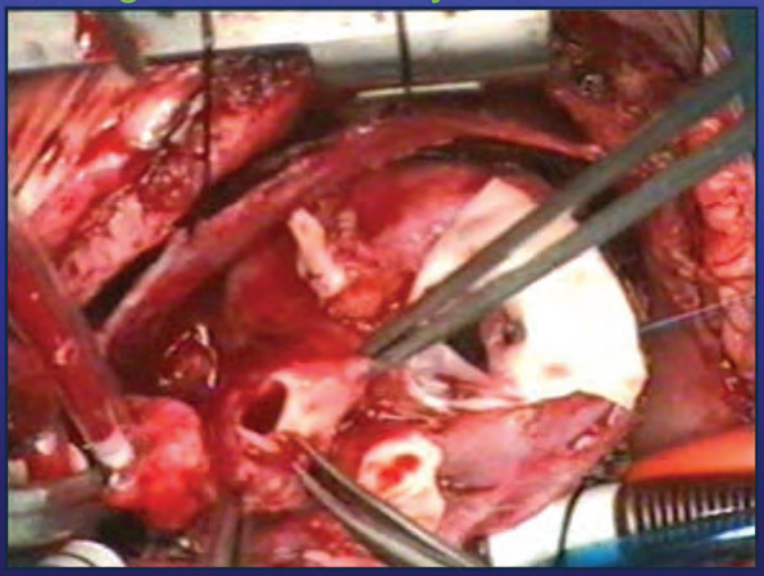

36

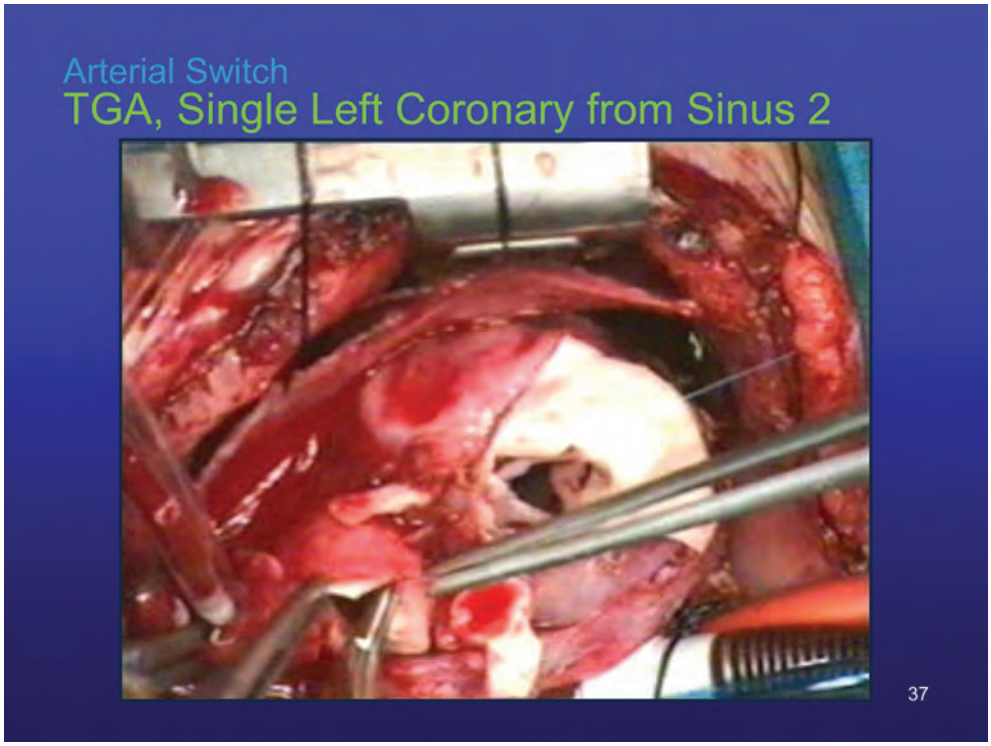
Arterial Switch
TGA, Single Left Coronary from Sinus 2
37

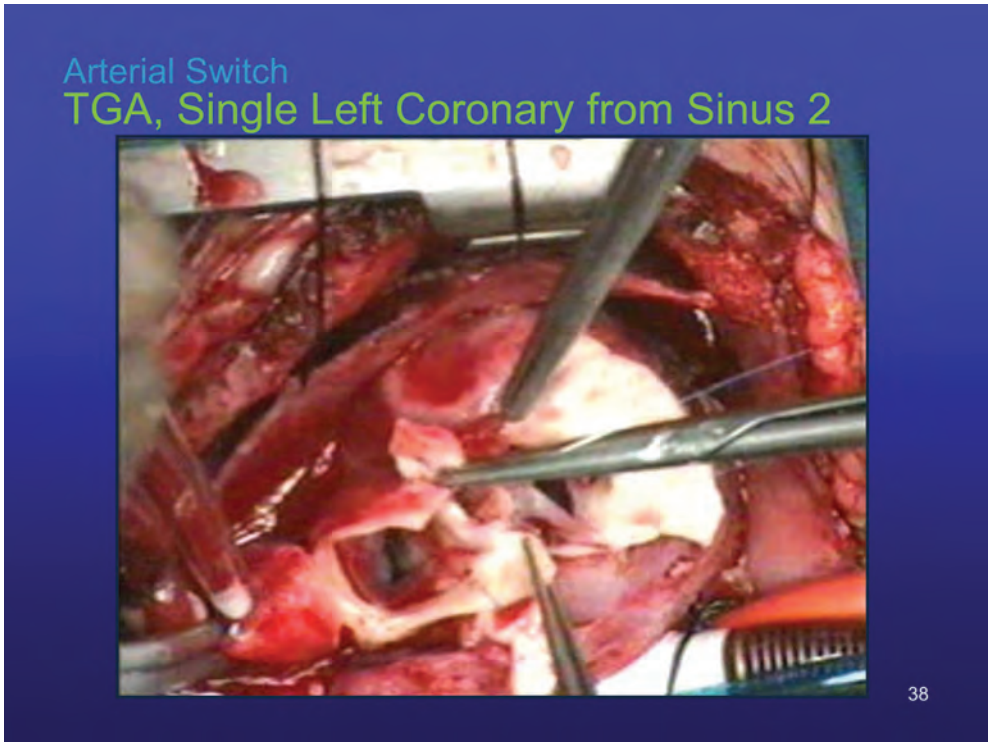
Arterial Switch
TGA, Single Left Coronary from Sinus 2
38

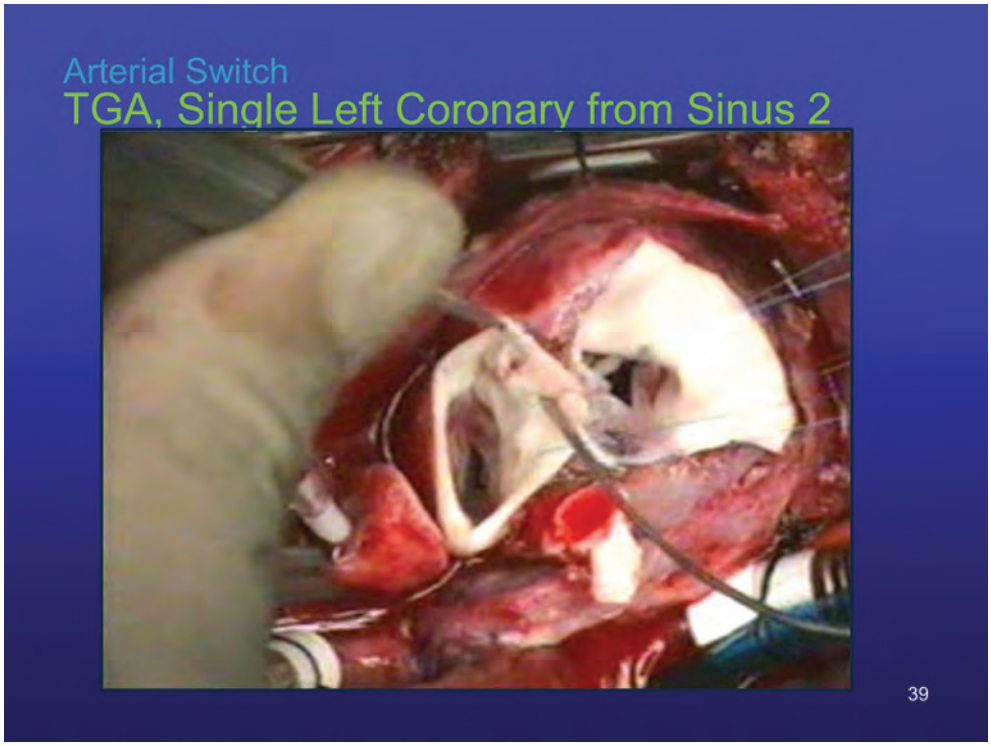
Arterial Switch
TGA, Single Left Coronary from Sinus 2
39

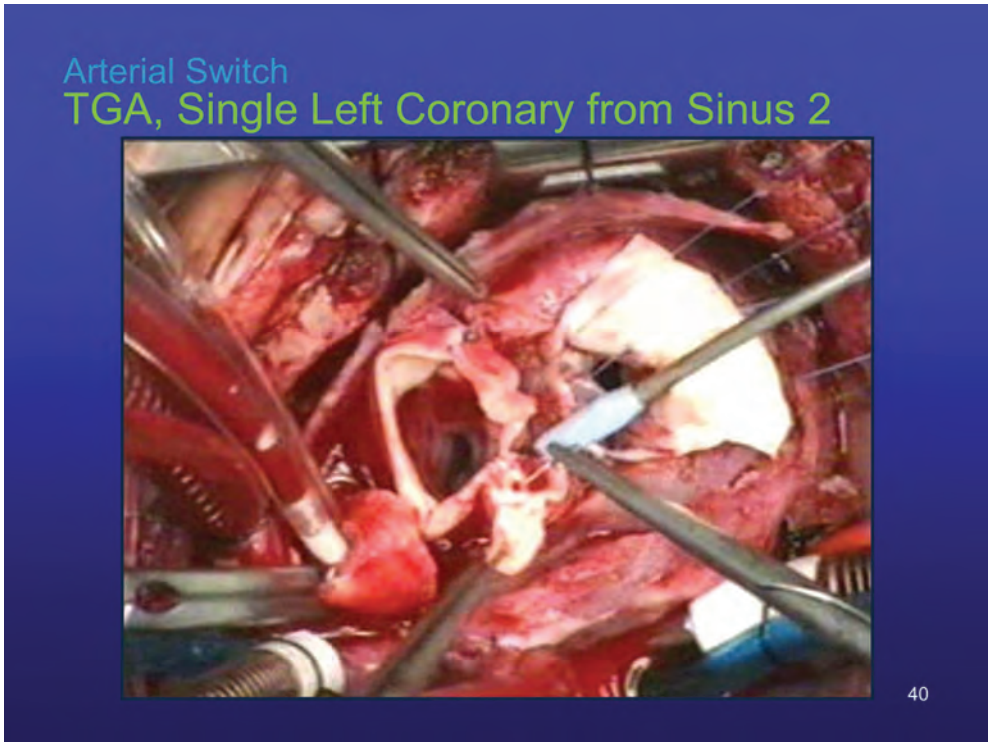
Arterial Switch
TGA, Single Left Coronary from Sinus 2
40

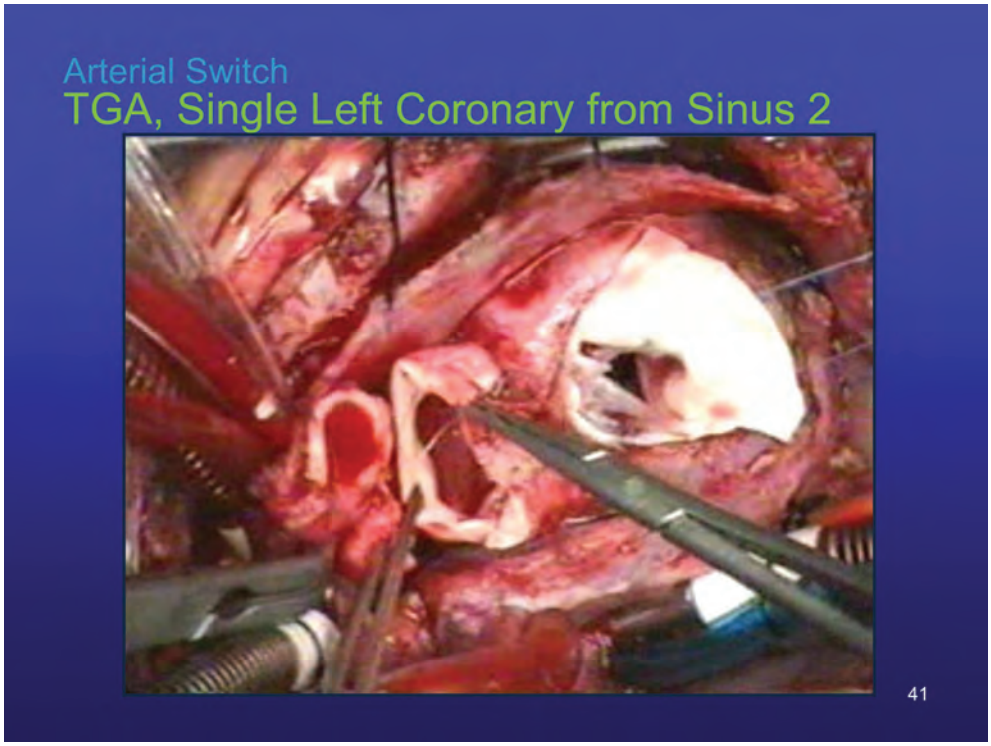
Arterial Switch
TGA, Single Left Coronary from Sinus 2
41

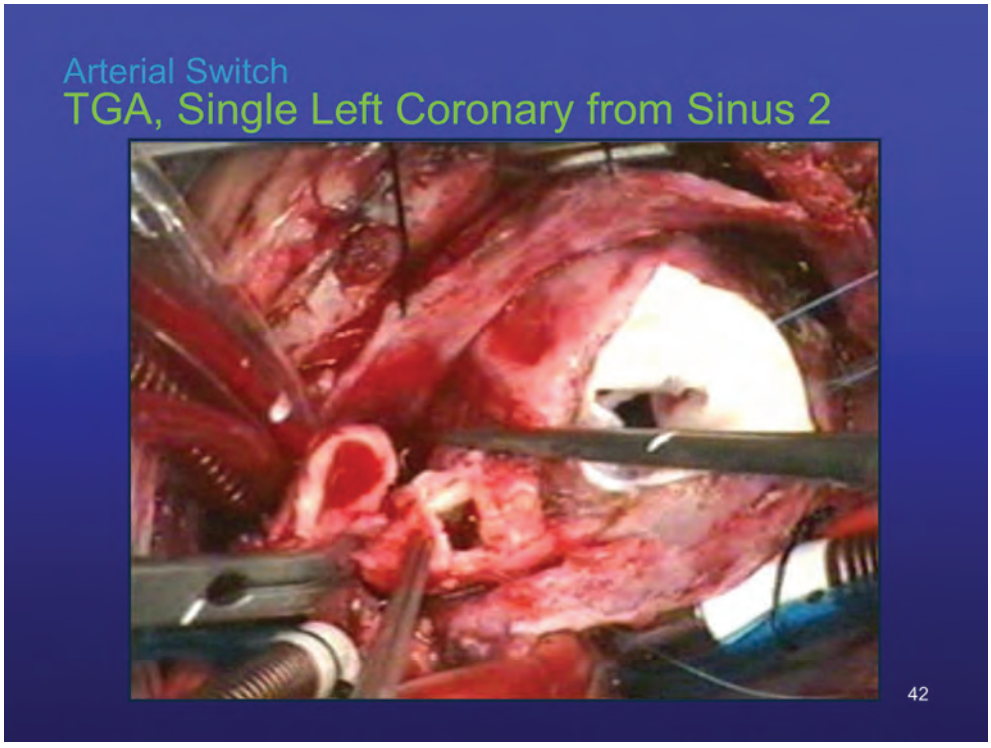
Arterial Switch
TGA, Single Left Coronary from Sinus 2
42

Arterial Switch
TGA, Single Left Coronary from Sinus 2

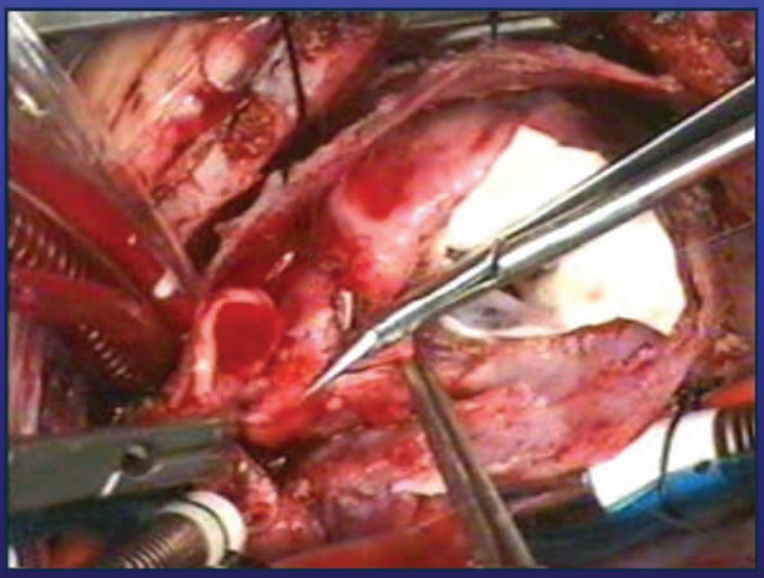

43

Arterial Switch
TGA, Single Left Coronary from Sinus 2

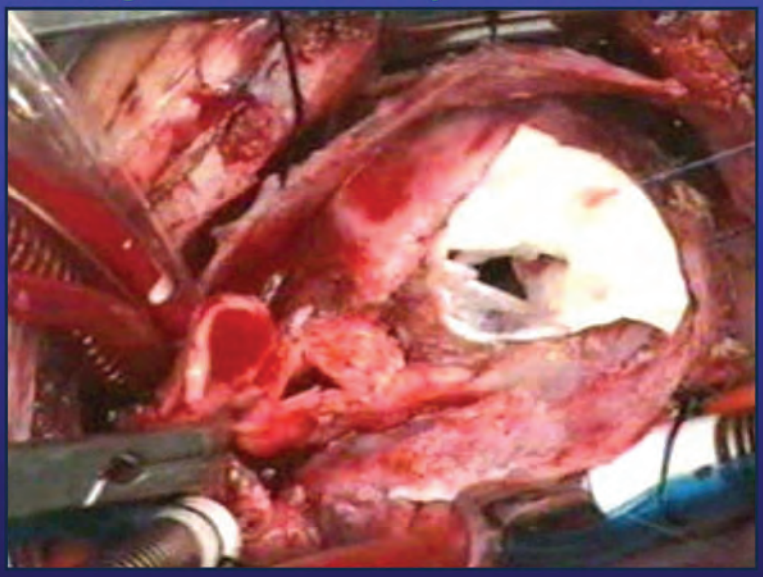

44

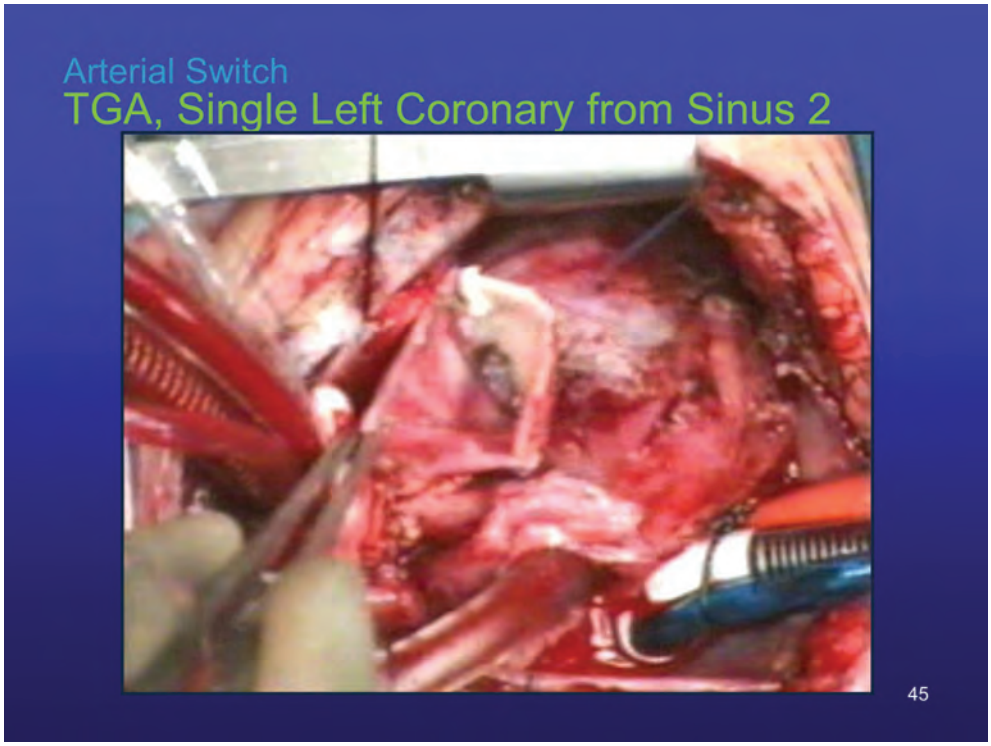
Arterial Switch
TGA, Single Left Coronary from Sinus 2
45

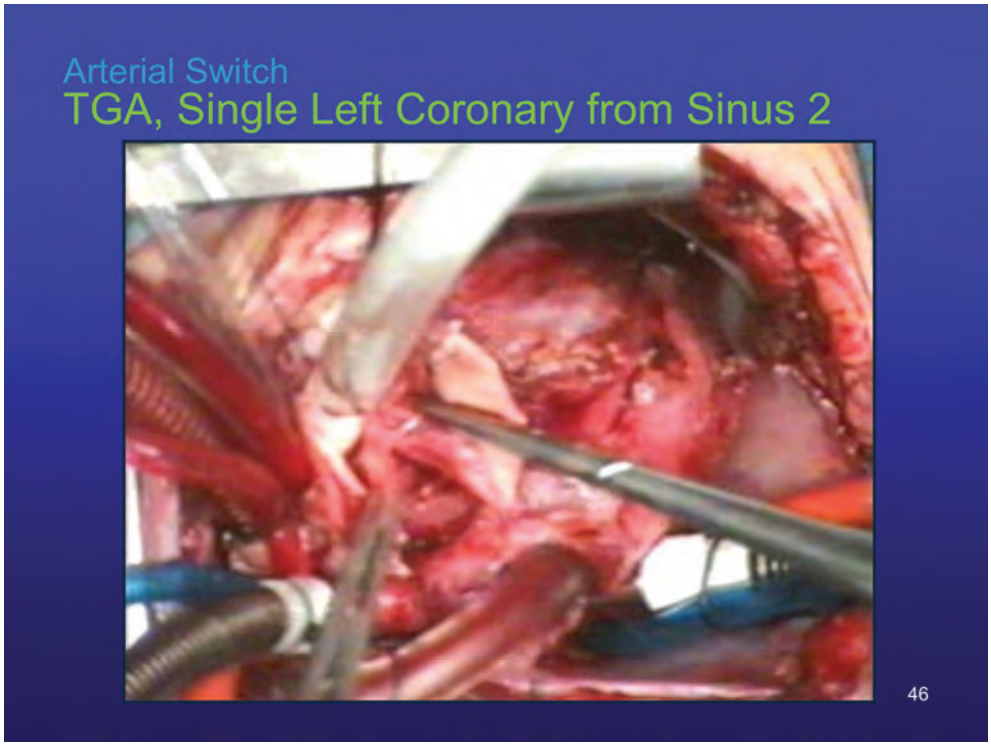
Arterial Switch
TGA, Single Left Coronary from Sinus 2
46

Arterial Switch
TGA, Single Left Coronary from Sinus 2

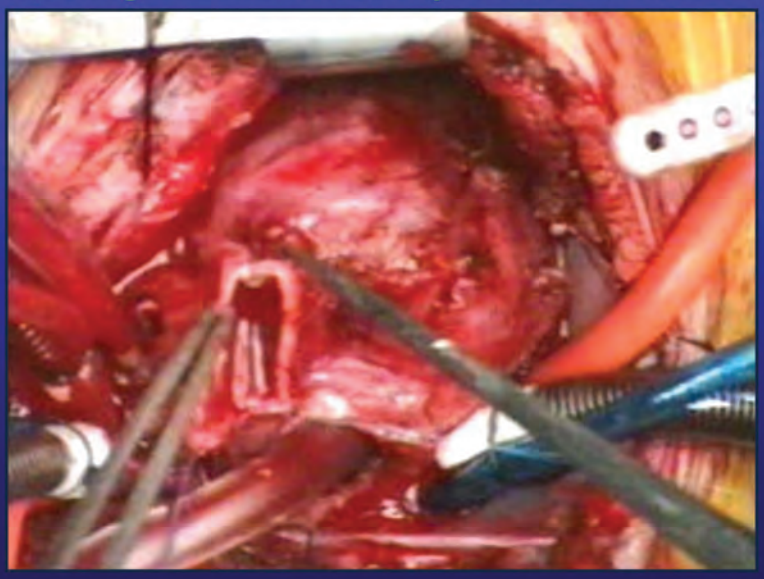

47

Arterial Switch
TGA, Single Left Coronary from Sinus 2

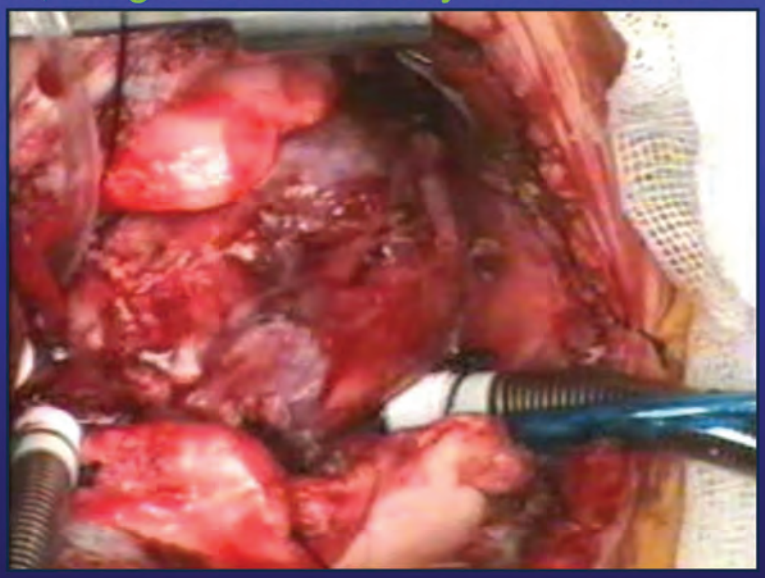

48

Arterial Switch

TGA, Single Left Coronary from Sinus 2



49

Arterial Switch

Results for single coronary artery (1983-2000)

- Analysis of 844 patients, (USA/Boston Children's Hospital)
- 53 had single coronary pattern; (6,3%)
- 7 with single coronary pattern died; (13%)
- Since 1991; 7 patients (13%) was required revision of coronary translocation due to myocardial ischemia
- Single ostium from sinus-2 & side by side GA estimated to have significant risk of mortality; (6-8 fold)

Jonas RA., Transposition of the great arteries, 2004

50

Arterial Switch
Coronary artery pattern & Mortality-Morbidity

- **Intramural coronary arteries & Outcome of ASO :**
  - ✓ 919 neonates (1987-2008 France/H.Necker)
  - ✓ 48 (5%) had intramural coronary pattern
  - ✓ mortality in intramural group; (28%, 13 pts)
  - ✓ mortality in nonintramural group; (4%)

Vouhe PR, Eur J Thorac Surg, 2010

Conclusion: Intramural coronary pattern remains associated with high risk of morbidity and mortality, even in the current era...

Arterial Switch
TGA & Coronary patterns

6 month old baby, TGA+VSD+Single left from sinus-1, LIMA to RCA

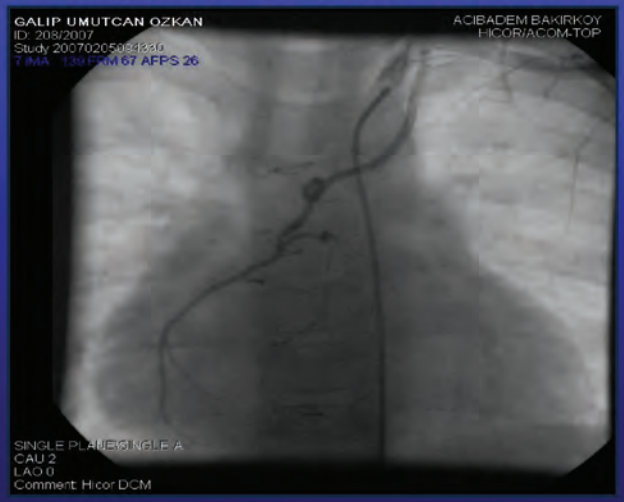

Angiography,12th year postoperatively

52

Arterial Switch

TGA & Coronary patterns

Coronary Artery Pattern and Outcome of Arterial Switch Operation for Transposition of the Great Arteries

Duke University,Durham,USA

A Meta-Analysis

Sara K. Pasquali, MD; Vic Hasselblad, PhD; Jennifer S. Li, MD; David F. Kong, MD; Stephen P. Sanders, MD

Background—Prior studies of coronary pattern and outcome after arterial switch operation (ASO) for transposition of the great arteries (TGA) have been hindered by limited statistical power. This meta-analysis assesses the effect of coronary anatomy on post-ASO mortality, both overall and adjusted for time.

Methods and Results—A literature search revealed 9 independent series that reported post-ASO mortality by coronary pattern in a total of 1942 patients. Odds ratios comparing all-cause mortality in patients with usual versus variant coronary patterns were calculated and combined by use of an empirical Bayesian model. Single coronary patterns, both of which loop around the great vessels, were associated with significant mortality (OR 2.9, 95% CI 1.3 to 6.8), whereas looping patterns that arose from 2 separate ostia were not (OR 1.2, 95% CI 0.8 to 1.9). This latter group includes patients with the most common variant, circumflex from right coronary artery. Patients with an intramural coronary artery had the greatest mortality (OR 6.5, 95% CI 2.9 to 14.2). Overall, patients with any variant coronary pattern had nearly twice the mortality seen in those with the usual pattern (OR 1.7, 95% CI 1.3 to 2.4). Single ostium patterns and intramural coronary arteries remained associated with significant added mortality after adjustment for time-trend effects.

Conclusions—Over the past 2 decades, patients with common coronary variants have undergone ASO without added mortality compared with those with the usual coronary pattern. Those with intramural or single coronary arteries have significant added mortality that has persisted over time. (*Circulation*. 2002;106:2575-2580.)

Arterial Switch

Coronary artery pattern & late outcome

- Late coronary insufficiency & reintervention: 3%
- Clinically silent coronary obstruction: 6-8%
- Late pulmonary pulmonary stenosis: 10-20%
  - ✓ Inverted coronary artery
  - ✓ Posterior LCA
  - ✓ Intramural CA

* Late reoperation after neonatal ASO.. Eur J Thorac Surg. 2008;34:32-36
* Predictors of outcome of ASO.. Ann Thorac Surg. 2008;85:1698-1703
* Late complications following the arterial switch operation WJPCHS 2011;2:37-42

54

Arterial Switch Repair
TGA+VSD & Coronary anomaly; Late PS

Single left from sinus 1



Supraannular PS, annular hypoplasia, LPA stenosis

55

Arterial Switch
Freedom from reoperation

- 1200 patients (mean fu:4,9 y)*. Survival (10-15y); 88%
- Free of reintervention (10 – 15 y); 82%
  - ✓ PS : 3,9 % AI : 3,2 %
  - ✓ Coronary lesions; 8 % (278 angio)
- 514 neonatal**
  - ✓ RVOT obstruction; 62 (83 % free / 10 y)
  - ✓ LVOT obstruction; 6 (98 % free / 10 y)

Planche C, Circulation 2001 ; 104 : 1121

Williams WG, J Thorac Cardiovasc Surg 1997; 114 : 975

56

Arterial Switch Repair
Coronary pattern & outcome (n:238 pts)* June,2010

Pattern	n; (%)	Mortality; (%)
Usual pattern	**169 (71)**	**15 (9)**
Unsusual pattern	**69 (29)**	
Cx from RCA	**41 (17)**	**2 (4.8)**
Intramural	**9** (4)	2
Inverted	**6** (2.5) (R:2, L:4)	1
Single left	**8** (3.4)	1
Single right	**5** (2.1)	1

*** Istanbul University, Memorial Hospital, Acıbadem Hospital (1990-2010)**

57

Conclusion

- ✓ Coronary anatomy and translocation of coronary arteries are among the major factors that influence the outcome of arterial switch operations for transposition of great arteries
- ✓ Intramural course, single coronary and inverted patterns are particularly important
- ✓ Meticulous preparation of the coronary button and proper translocation are critical steps for intramural coronary arteries
- ✓ Higher implantation and pericardial patch/tube augmentation are useful methods for single coronary and inverted coronary anomaly patterns

58


Arterial Switch
All Our Efforts are for the Best Possible Outcomes for Children
59