



Baština Akademije nauka i umjetnosti Bosne i Hercegovine

RADOVI XCIV, knj. 34.

Konjhodžić, Faruk

2005

Akademija nauka i umjetnosti Bosne i Hercegovine

<https://bastina.anubih.ba/items/3365c570-c36a-46d8-b90b-aff13049b94a>

Preuzeto s Baštine Akademije nauka i umjetnosti Bosne i Hercegovine

<https://bastina.anubih.ba/>



AKADEMIJA NAUKA I UMJETNOSTI BOSNE I HERCEGOVINE
АКАДЕМИЈА НАУКА И УМЈЕТНОСТИ БОСНЕ И ХЕРЦЕГОВИНЕ
ACADEMY OF SCIENCES AND ARTS OF BOSNIA AND HERZEGOVINA

WORKS

VOLUME XCIV

Department of Medical Sciences

Volume 34

Centre of Medical Research

Volume 4

Editorial Board

Jela Grujic-Vasić, Ladislav Ožegović,
Slobodan Loga, Berislav Topić

Editor

Faruk Konjhodžić

correspondent member of the ANUBiH

SARAJEVO 2005

ROKITANSKY SYNDROME

Srećko Šimić, Nedžad Nakaš

Department of Obstetrics and Gynaecology General Hospital "Sarajevo"

Abstract: Mayer-Rokitansky syndrome belongs to the group of heterogenous disorders of female urogenital organs. The main component of this syndrome is vaginal aplasia or vaginal agenesis followed by rudimented uterus. For this occasion we have chosen this syndrome between a large group of malformations of women's urogenital tract considering that this year whole world is celebrating two hundred years since the birth of Carl Freiherr Von Rokitansky. We are showing this syndrome and following modified David's operation of neovagina formation

Key words: Mayer-Rokitansky syndrome, vaginal aplasia, neovagina

ROKITANSKY, CARL, FREIHERR VON the founder of the Vienna school of pathological anatomy, pathologist, philosopher and politician, born on the 19th of February 1804 at Koniggratz in Bohemia. He studied medicine at Prague and at Vienna, graduating at the latter place in 1828. Soon afterwards he became the assistant to Johann Wagner, the professor of pathological anatomy, and succeeded him in 1834 as prosector, being at the same time made extraordinary professor, ten years later (1844) he reached the rank of full professor. To his duties as a teacher he added in 1847 the onerous office of medico-legal anatomist to the city, and from 1863 he filled an influential office in the ministry of education and public worship, wherein he had to advise on all routine matters of medical teaching, including patronage. A seat in the upper house of the Reichsrath rewarded his public labours in 1867, and on his retirement from all his offices in 1874 he was made a commander of the Order of Leopold. He joined the Imperial Academy of Sciences as a member in 1848, and became its president in 1869. He was president also of the medical society of the Austrian capital and an honorary member of many foreign societies. On his retirement at the age of seventy his colleagues celebrated the occasion by a function in the aula of the university, where his bust was unveiled.



Malformations of women's urogenital tract are quite common with incidence of 1-3%. These malformations are compatible with life but consequences of them are usually infertility or primary sterility.

Between a large group of these malformations we have chosen this syndrome considering that whole world this year is celebrating two hundred years since birth (1804 AD) of Carl Freiherr Von Rokitansky

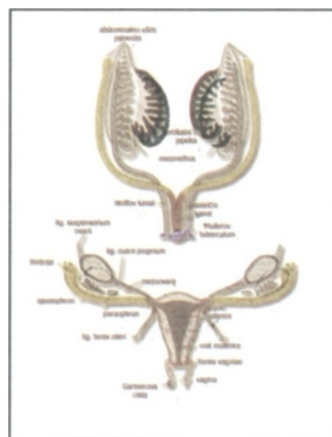
Rokitansky syndrome or Mayer-Rokitansky syndrome (MRS) is quite rare abnormality of female urogenital tract with estimated incidence of 1:4,000-5,000 live female births. Basically it is characterised by normal external genitalia, an absent vagina, absent or rudimentary uterus, and normal fallopian tubes and ovaries. Although its etiology is not still clear there is no doubt that it is a result of some embryological defect, probably the disturbances in fusion of the Wolffian and Müllerian ducts. Embryologists define the MRS as a spectrum of Müllerian anomalies, including vaginal agenesis with or without renal anomalies, in genotypic and phenotypic female subjects with normal endocrine status.

Main characteristics of syndrome are:

- vaginal aplasia
- uterine aplasia or rudimented uterus
- amenorrhoea
- Morphological and functional development of ovaries with normal ovarian cycles and normal blood levels of estrogen and progesterone which means normal secondary sex characteristics.



This syndrome was first described by Mayer in 1829. He described partial and complete duplications of vagina in 4 stillborns associated with multiple skeletal, cardiac, facial and urological abnormalities. Rokitansky in 1838 described 19 adult autopsy cases of uterovaginal agenesis including 3 cases in which unilateral renal agenesis was noted. In 1910 Küstner described several cases with similar genital anatomy and observed that skeletal and renal anomalies were common. It is now



generally accepted to name this syndrome as Mayer-Rokitansky syndrome, although there are still lots of authors who include the other names in it.

The addition of names of other authors who have contributed to knowledge and the range of accompanying anomalies to this eponymous title is excessively cumbersome and to be discouraged.

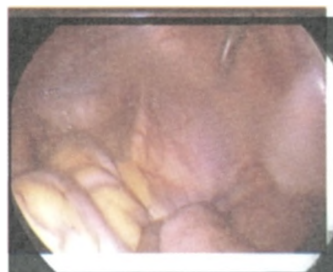Embryologically, normal development of Müllerian duct depends on previous normal development of Wolffian duct. A defect of the Wolffian duct foreshadows a defect at similar level in the Müllerian duct. However, although the Wolffian duct may be normal, the Müllerian duct that develops later may be intrinsically defective. It may be lacking totally, or may arrest at some point of its intrinsic development, migration, fusion or canalisation, therefore resulting in a wide spectrum of reproductive tract anomalies including imperforate hymen, vaginal septa, vaginal atresia, or complete Müllerian aplasia.

The Müllerian duct (MD, ductus tamesonephricus) develops independent of the coelomic epithellium above the mesonephros. This part of the duct gives rise to the infundibulum of the uterine tube with its fimbriated ostium abdominale.

The part of the duct which lies along the mesonephros as far as its caudal pole makes a contribution to the ampula and less often the isthmus. In the area of mesonephros the MD fuses with the Wolffian duct (WD, ductus mesonephricus). The WD gives rise to ampula and the isthmus. Below the caudal pole of the mesonephros, as well as beyond the attachment point of the inguinal ligament of the mesonephros, the later round ligament of the uterus, the MD develops as an outgrowth of the WD and no longer as an independent structure. The Mayer-Rokitansky syndrome is, in its formal genesis, a non-fusion of the MD with WD. This explains the fact that in classic cases of MRS, the Fallopian tube with a very small part of the cornu uteri extends only as far as the connection with the round ligament of uterus.



The urologic components of this syndrome that are eventually present belong to disturbances of Wolffian structures, namely because of complete lack of a Wolffian duct, or because of inhibition, debilitation or duplication of the ureteral bud. Therefore we can find a broad spectrum



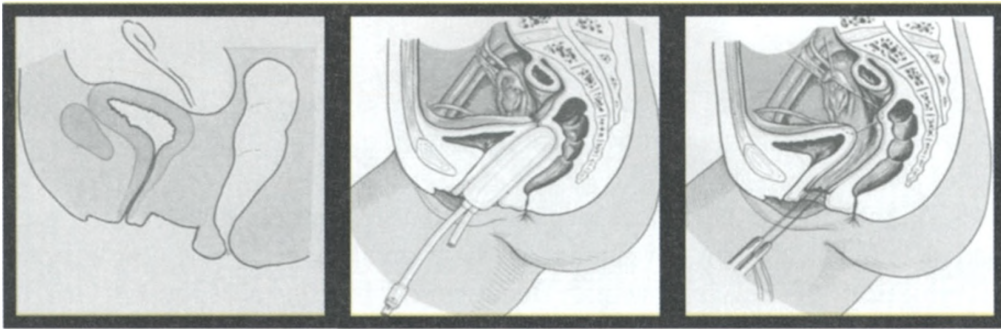
of symmetric and asymmetric urological anomalies such as absent kidney, pelvic kidney, absent or duplicated ureters, blocks and stenoses in urinary system, vesicoureteral reflux etc. On this picture we have showing a case of pelvic kidney that we found during explorative laparoscopy.

This syndrome does not appear to be genetic in origin, and possibility of genetic transmission seems unlikely. There are some hypotheses about the etiology of this syndrome based on potential deficiency of gestagen and/or estrogen receptors, mainly in explaining various forms of rudimentary vagina.

Syndrome is usually diagnosed during puberty when it is showed as amenorrhoea or hymenal atresia. After the cognition of vaginal and uterine aplasia, issues about further possibilities of sexual life and fertility give rise, mainly in women with stabile relationships, especially if married. For this occasion we are showing modification version of David's neovagina operation. Due to forty-five years of clinical and surgical experience during which it has been diagnosed thirty seven of the cases of this syndrome and operated twenty three of them. We have chosen David-s neovaginal surgical procedure using pelvic peritoneum as a epithelial coverage for tunnelisated neovaginal canal because this operation in our experience was the most successful one.

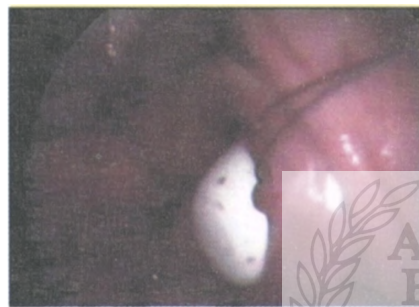Before the operation our technicians create a plastic mold of typical phallic dimensions that is going to be inserted in future vagina. The mold is properly sterilizations, and prepared for the operation. The patient undergone general anesthesia and in dorsal lithotomy position urinary permanent (Foley) catether was inserted . At the same time the rest of the surgery team performed the standard procedure for laparoscopic surgery. Under laparoscopic guidance we observed rudimentary uterus, and two healthy, and functionally active ovaries with signs of ovulation on the right ovary.

Carefully we place the large bore 18-gauge needle trough the urethrovesicorectal space till the reached. Following the needle we peritoneum that was visualised laparoscopically was dissect the space



bilaterally, taking permanent care to avoid injuries of adjacent organs.

The peritoneum under the rudiment of uterus is opened, clamped and fixated with four resorbable surgical sutures. The canal of neovagina is dilatated with at first one and later by two fingers, and after all it was tunelised by mold. The sutures are clamped and pulled



through the neovaginal canal by surgical instruments. The mold is inserted into neovagina by traction of the peritoneum and by pressure to mold itself. The peritoneum above the mold and under the uterine rudiment is obliterated by resorbable surgical sutures, resulting in closure of peritoneal cavity. The peritoneum pulled trough neovaginal canal is fixated to vestibular mucosa of initial incision. The mold is fixated to vaginal vestibule, and left *in situ* for 10 days. Postoperative course was normal. The patient is dismissed at 15 postoperative day and advice to insert and pull out the mold several times daily. She is encouraged to start her sex life as soon as she finds it acceptable.

Patient returns three months later on a control visit. Neovagina is usually without stenoses. She usually describes her initial sexual experiences as satisfactory. The troubles that appeared were connected with her infertility. A few years ago that was big problem because there were no IVF facilities but now this is not the case. There are a few possibilities as IVF and surrogate mothers etc.

Discussion

The diagnosis of MRS can be made summarising the results of physical examination, and of different other diagnostic procedures.

Each patient that experiences primary amenorrhoea connected with some kind of vaginal abnormality should do hormonal analyses and sonographic examination of pelvic organs. Because of high incidence of urinary abnormalities associated with each patient should do urologic examination, especially IVP and cystoscopy. If there are possibilities chromosome evaluation and buccal smear should be obtained, to exclude rare syndrome of testicular feminisation.

The high-resolution transabdominal real-time ultrasonography provides additional possibility to visualise precise details of pelvic anatomy, including visualisation of Müllerian structures, kidneys, bladder, septa in internal genital organs, ovarian cysts etc. Ultrasound is especially useful to visualise distended obstructed segments of the genital or urinary tract. For the diagnosis of MRC clinical experience showed that transabdominal sonography rarely provides adequate images that could be of practical use. The trans-rectal ultrasonography provides much better images that correspond perfectly with the real anatomic situation. Today it is used not only as a diagnostic procedure, but also as a part of intraoperative equipment that is helping the surgeon to have a better visualisation of surgical route.

Magnetic resonance imaging is now gaining wide acceptance in imaging congenital abnormalities of genital tract. It is especially useful in paediatric gynaecology for evaluation of paediatric uterovaginal abnormalities, but it is still not widely accessible, nor included in routine preoperative evaluations.

From the time of Mayer and Rokitansky till today the therapy of MRS is evolving, and changing its route. There is a wide spectrum of different surgical and non-surgical methods to solve this problem, and none of it yet did not show itself as perfect.

Non-surgical methods as Frank's mold therapy, "Interfemoral intercourse" or bicycle seat stool-therapy could be applied to women with high self-confidence who have stable emotional relations with their partners and strong feelings of self-acceptance, or do not want any surgical correction

The rate of such patients is to our experience not too high. The results of these “pressure” methods are doubtful.

Surgical procedures applied to MRS are different. All of them have the same goal- to create a new vagina in urethroretrovesical space, on its physiological site. All of them have the same difficulties too: how to prevent closure and stenoses of this artificial vagina that is lacking in its original musculature, tonus, innervation and vascularisation, how to ensure adequate lubrication for the intercourse and to prevent dyspareunia.

The aim of vaginoplasty should be creation without excessive morbidity of a neovagina that will be satisfying in appearance, function and feeling. The multitude of methods described in literature indicates the fact that an ideal approach has not yet been found. We conclude that beside non-surgical, the peritoneum pull-through technique, and perhaps skin grafts are the methods of choice. In cases where immediate vaginal reconstruction after oncological surgery is indicated, myocutaneous flaps are preferred. Only in cases in which other methods have failed should recto-sigmoid transplantation be considered.

After the successful neovaginal formation there is still a question of female infertility that is the reason of many marital crushes. Such issues can be solved by IVF and ET procedures with gestational carriers. The specific medical and legal issues involved in facilitating genetic offspring in these instances must be considered. These include the initial matching of the genetic parents with the gestational carrier, cycle synchronisation for in vitro fertilization and embryo transfer, anatomic difficulties of oocyte retrieval, birth certificate documentation, and current legal status of gestational carrier.

Abstrakt:

Mayer-Rokitansky sindrom pripada grupi heterogenih poremećaja ženskog urogenitalnog trakta. Glavna komponentna sindroma je vaginalna aplazija ili ageneza koju prati postojanje rudimentirane materice. Za ovu priliku mi smo odabrali ovaj sindrom iz velike grupe malformacija urogenitalno trakta imajući u vidu da ove godine cijeli svijet slavi dvije stotine godina od rođenja Carl Freiherr Von Rokitansky-a. Ovdje ćemo prikazati ovaj sindrom te modifikovanu Davidovu operaciju formiranja neovagine.

Literature

C. A. J. Mayer: Über Verdoppelungen des Uterus und ihre Arten, nebst Bemerkungen über Harenscharte und Wolfsrachen. *Journal der Chirurgie und Augen-Heilkunde*, Berlin, 1829, 13: 525-564.

K. F. von Rokitansky: Über die sogenannten Verdoppelungen des Uterus. *Medizinische Jahrbücher des kaiserl. königl. österreichischen Staates*, Wien, 1838, 26: 39-77.

H. Küster: Uterus bipartitus solidus rudimentarius cum vagina solida. *Zeitschrift für Geburtshilfe und Gynäkologie*, Stuttgart, 1910, 67: 692-718.

G. A. Hauser, M. Keller, T. Koller, et al: Das Rokitansky-Küster-Syndrom. Uterus bipartus solidus rudimentarius cum vagina solida. *Gynaecologia*, Basel, 1961, 151: 111-112.

G. A. Hauser, W. E. Schreiner: Das Mayer-Rokitansky-Küster-Syndrom. *Schweizerische medizinische Wochenschrift*, Basel, 1961, 91: 383-384.

