Baština Akademije nauka i umjetnosti Bosne i Hercegovine

Perspectives in Paediatric Cardiology: Perspektive u pedjatrijskoj kardiologiji

Mesihović Dinarević, Senka

2012

Akademija nauka i umjetnosti Bosne i Hercegovine

https://bastina.anubih.ba/items/ff7d5ad2-af81-4f1b-8490-552285003fe6

Preuzeto s Baštine Akademije nauka i umjetnosti Bosne i Hercegovine

https://bastina.anubih.ba/

NUCLEAR MEDICINE IN PAEDIATRIC CARDIOLOGY

Elma Kučukalić-Selimović

Abstract

Nuclear medicine offers several methods applicable to the diagnosis and assessment of paediatric cardiovascular disorders which include: single photon emission computed tomography (SPECT), positron emission tomography (PET), first-pass radionuclide angiocardiography, radionuclide ventriculography (gated blood pool scan) and venography.

Myocardial perfusion SPECT is the most frequently utilized technique in myocardial imaging in paediatric patients, useful in the assessment of disorders of coronary perfusion such as: Kawasaki disease, transposition of the great arteries following arterial switch operation, cardiac transplantation, cardiomyopathy and anomalous left coronary artery. Radiopharmaceuticals for myocardial perfusion SPECT, PET perfusion and metabolic tracers are addressed in the paper.

Several nuclear medicine methods for the assessment of ventricular function in children are available. These include electrocardiogram (ECG)-gated myocardial-perfusion SPECT, gated metabolic PET (18F-FDG), gated blood-pool scintigraphy, and first-pass radionuclide angiography. Radionuclide assessments of ventricular function include right and left ejection fractions, detection of wall-motion abnormalities, ventricular volume, cardiac output, and regurgitant fraction. Clinical applications of radionuclide studies to assess ventricular function have been applied to several diseases including cardiomyopathies, atrial and ventricular septal defects and certain congenital heart diseases, before and after catheter intervention or corrective surgery. First-pass radionuclide angiocardiography is a rapid and non-invasive method that is useful in the diagnosis and measurement of left-to-right shunts and for assessing the magnitude of the shunt in patients before and after repair.

Dramatic improvements in nuclear medicine techniques provided an important role in the diagnostic and functional armamentarium of the paediatric cardiologist.

Keywords: paediatric cardiology, nuclear medicine, myocardial perfusion, SPECT, left-to-right shunt

Introduction

The application of radionuclides to study the cardiovascular system was first investigated by Blumgart and Yens and Blumgart and Weiss in 1927 [1]. These investigators used radium C and a primitive radiation detector to study blood flow velocity.

In 1948 and 1949, Prinzmetal et al. [2] described radiocardiograms of three patients with congenital heart disease using iodine-131 (131I), sodium iodine, and a Geiger-Mueller counter.

Congenital heart disease affects 0.8 per 100 live births. Nuclear medicine techniques play an important role in the diagnostic and functional armamentarium of the paediatric cardiologist. In the past three decades, tremendous advances in imaging techniques such as echocardiography, computed tomography (CT), magnetic resonance imaging (MRI), and angiography have helped in the evaluation of anatomy and the understanding of physiology in children with heart disease in ways not possible before.

Furthermore, with dramatic improvements in technology (radio-pharmaceuticals and imaging instrumentation), nuclear medicine offers several methods applicable to the diagnosis and assessment of paediatric cardiovascular disorders. These include:

– single photon emission computed tomography (SPECT),
– positron emission tomography (PET),
– first-pass radionuclide angiocardiography,
– radionuclide ventriculography (gated blood pool scan), and
– venography.

1. Myocardial Imaging

Radionuclide imaging of the myocardium can be carried out with SPECT or PET, which can image myocardial perfusion, metabolism, neuronal innervation, and inflammation/infection. Myocardial perfusion using SPECT is the most frequently utilized technique in paediatric practice.

Myocardial perfusion SPECT is useful in the assessment of disorders of coronary perfusion such as:

– Kawasaki disease,
– transposition of the great arteries following arterial switch operation,
– cardiac transplantation,
– cardiomyopathy,
– chest pain and trauma,
– anomalous left coronary artery arising from the pulmonary artery.

Other less frequent indications include hyperlipidemia, supravalvular aortic stenosis, syncope, coarctation of the aorta, and pulmonary atresia with intact ventricular septum.

1.1. Kawasaki disease

Kawasaki disease is an acute, self-limited vasculitis of unknown aetiology that occurs predominantly in infants and young children of all races. The disease is characterized by fever, bilateral nonexudative conjunctivitis, erythema of the lips and oral

mucosa, changes in the extremities, rash, and cervical lymphadenopathy. Coronary artery aneurysms or ectasia develop in 15% to 25% of untreated children with the disease and may lead to ischemic heart disease, myocardial infarction, or even sudden death [3, 4]. Myocardial perfusion SPECT has been widely used in the assessment of these patients. The presence of aneurysm may or may not be correlated with abnormalities in regional myocardial perfusion (Figure 1). Perfusion SPECT, with exercise or pharmacologic stress, may demonstrate regional myocardial perfusion impairment or improvement in perfusion after medical therapy [5] (Figure 2).

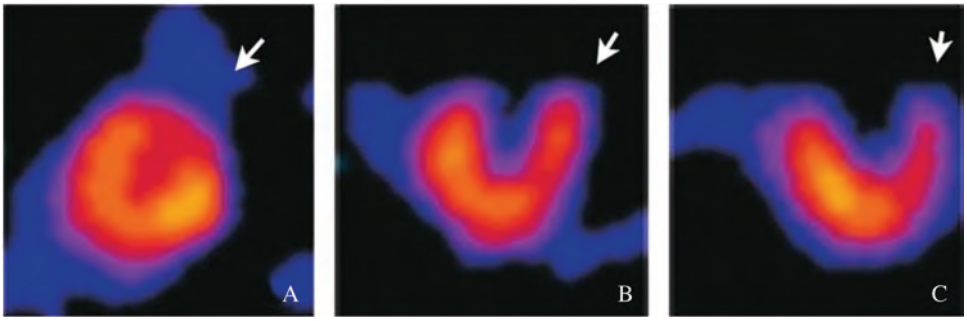

Figure 1. A 6-year-old boy with Kawasaki disease and severe aneurysms in the left anterior descending and the right coronary arteries. Short axis (A), horizontal long axis (B), and vertical long axis (C) slices reveal a perfusion defect in the anterior wall of the left ventricle (arrows) (S.T. Treves. Pediatric Nuclear Medicine/PET, 3ed ed. Secaucus, NJ: Springer Verlag, 2007).

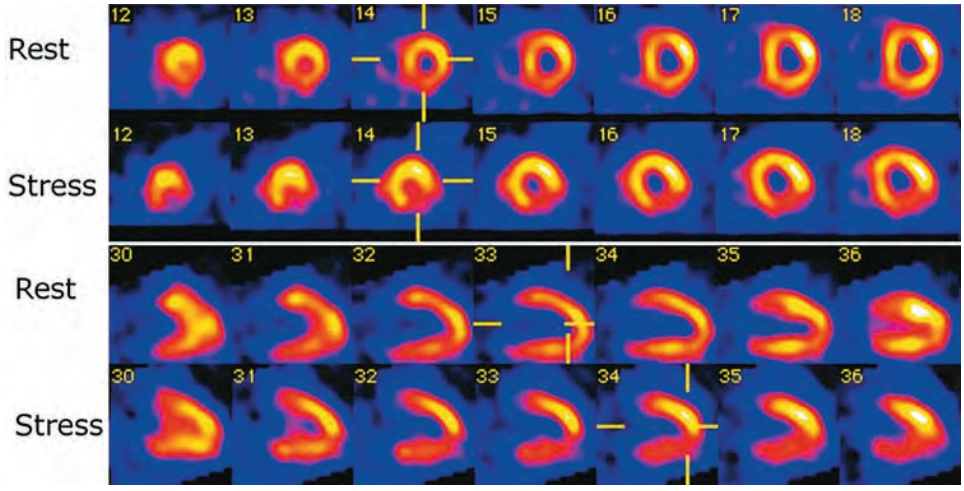

Figure 2. Patient with Kawasaki disease with severe ischemia of the inferior wall of the left ventricle, most pronounced during stress (S.T. Treves. Pediatric Nuclear Medicine/PET, 3ed ed. Secaucus, NJ: Springer Verlag, 2007).

1.2. Transposition of the Great Arteries: Arterial Switch Operation

In dextrotransposition of the great arteries (d-TGA), the aorta arises anterior from the anatomic right ventricle and the pulmonary artery arises from the anatomic left ventricle. This defect accounts for 5% to 7% of all congenital cardiac malformations [6]. Current medical and surgical treatment – arterial switch operation (ASO) – provides greater than 95% early and midterm survival. The short- and long-term success of this operative approach depends principally on the continued patency and adequate functioning of the coronary arteries [7, 8]. Abnormalities of myocardial perfusion in children after the ASO at rest and with the physiologic stress of exercise have been documented in nearly all patients using technetium-99m hexakis (2-methoxyisobutylisonitrile) sestamibi (99mTc-MIBI) myocardial perfusion SPECT (Figure 3).

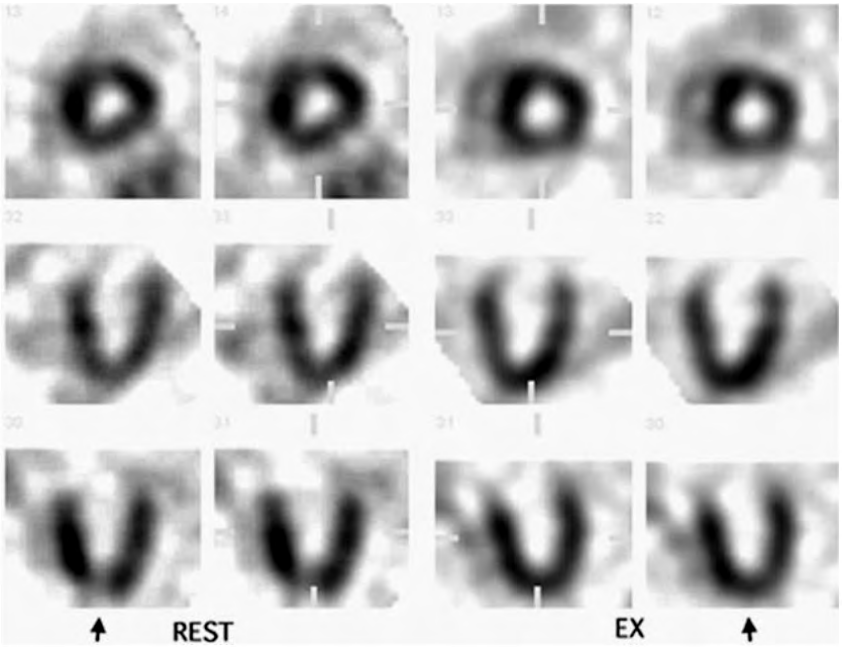

Figure 3. Arterial switch operation for transposition of the great arteries. At rest, there is an apparent apical defect that is not present at exercise (arrows) (S.T. Treves. Pediatric Nuclear Medicine/PET, 3ed ed. Secaucus, NJ: Springer Verlag, 2007).

1.3. Cardiac Transplantation

Paediatric cardiac transplantation is treatment option for neonates, infants, and children with end-stage cardiomyopathy or congenital heart disease not amenable to conventional surgical repair or palliation. Accelerated coronary vasculopathy which

involves some form of vascular immunologic injury has become the major cause of late morbidity and mortality following transplantation [9, 10].

Myocardial perfusion SPECT has been used to evaluate these patients on a regular basis and helps in the diagnosis of coronary artery disease and myocardial viability. In cases showing perfusion defects, fluorine-18 fluorodeoxyglucose (18F- FDG)-PET can determine myocardial viability [11]. Example of 99mTc-MIBI SPECT in patients following heart transplant is shown in Figure 4.

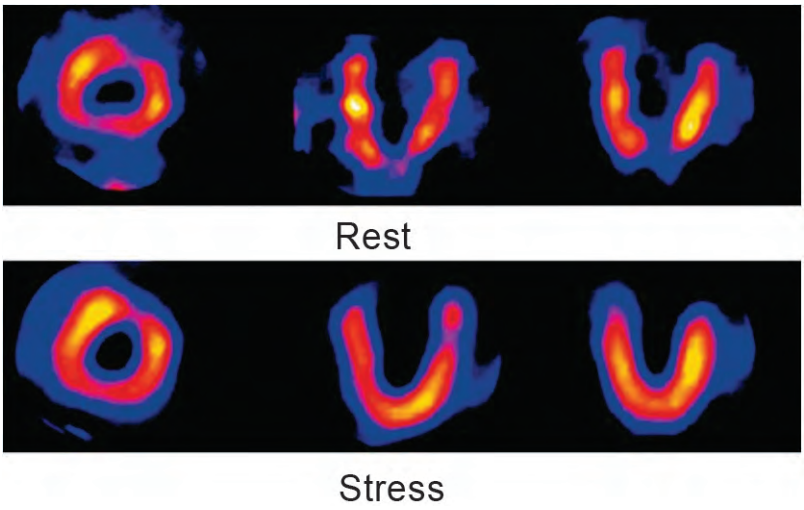

Figure 4. Cardiac transplant. Images at rest reveal irregular distribution of myocardial perfusion. This pattern changes during stress. The defect in the anterior wall remains, while the apical defect improves with stress (S.T. Treves. Pediatric Nuclear Medicine/PET, 3ed ed. Secaucus, NJ: Springer Verlag, 2007).

1.4. Anomalous Left Coronary Artery

Anomalous origin of the left coronary artery from the pulmonary artery (ALCAPA) results in severe myocardial dysfunction and ischemia during early infancy [12, 13]. Following birth, the left ventricle becomes perfused with desaturated blood at pressures that rapidly fall below systemic pressures. Classic findings include infarction of the anterolateral left ventricular free wall followed by mitral valve incompetence secondary to an infarcted anterior papillary muscle. This leads to symptomatic congestive heart failure in the first year of life. Myocardial perfusion scintigraphy may be helpful for assessing the severity of hypoperfusion and for the serial evaluation during recovery of function following repair [14] (Figure 5).

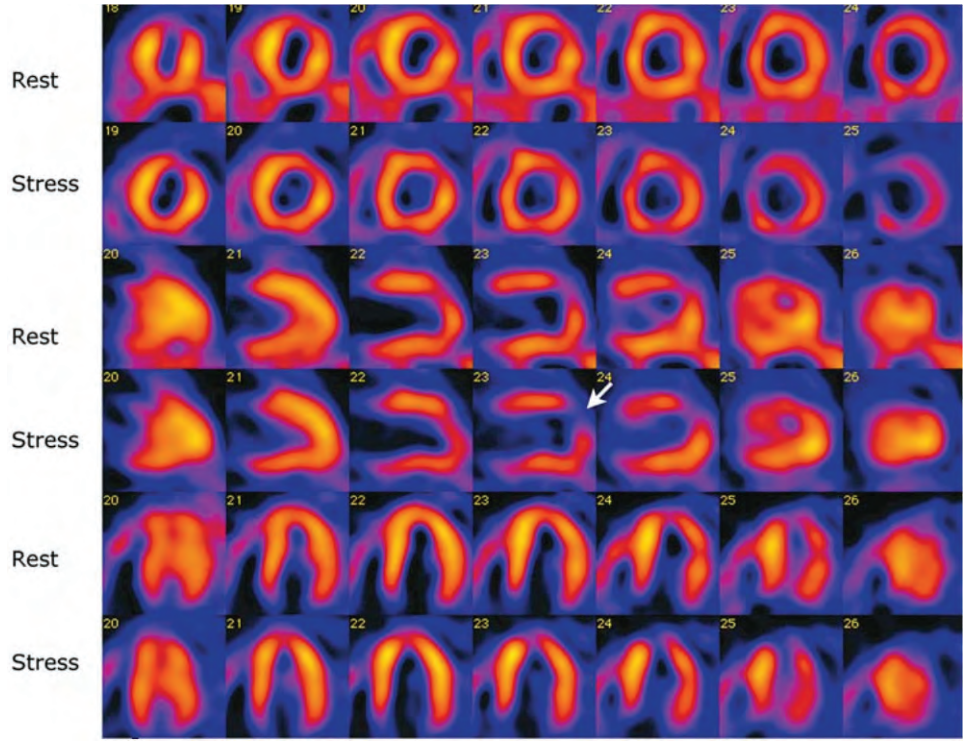

Figure 5. A 5-year-old boy with anomalous coronary artery departing from the pulmonary artery. A perfusion defect gets worse with stress (arrow) (S.T. Treves. Pediatric Nuclear Medicine/PET, 3ed ed. Secaucus, NJ: Springer Verlag, 2007).

1.5. Cardiomyopathy

Depending on the type and severity of the cardiomyopathy, myocardial perfusion SPECT can diagnose myocardial dilatation, myocardial thinning, focal ischemia, or infarction as well as myocardial contractility and wall motion abnormalities (Figure 6).

1.6. Chest pain

Chest pain is a common complaint in children. Cardiac causes of chest pain account for a small minority of potential etiologies including idiopathic (12% to 85%), musculoskeletal (15% to 31%), pulmonary (12% to 21%), psychiatric (5% to 17%), gastrointestinal (4% to 7%), other (4% to 21%), and cardiac (4% to 6%) [15].

Cardiac related causes of chest pain include anatomic lesions (such as aortic stenosis, anomalous coronary artery from the pulmonary artery, and coarctation), acquired lesions (cardiomyopathies, Kawasaki disease, dissecting aortic aneurysm) and tachyarrhythmias. Chest pain is not a frequent referral diagnosis for myocardial perfusion SPECT. However, it has been observed that this method is helpful to rule out cardiac ischemia as a cause of chest pain [11].

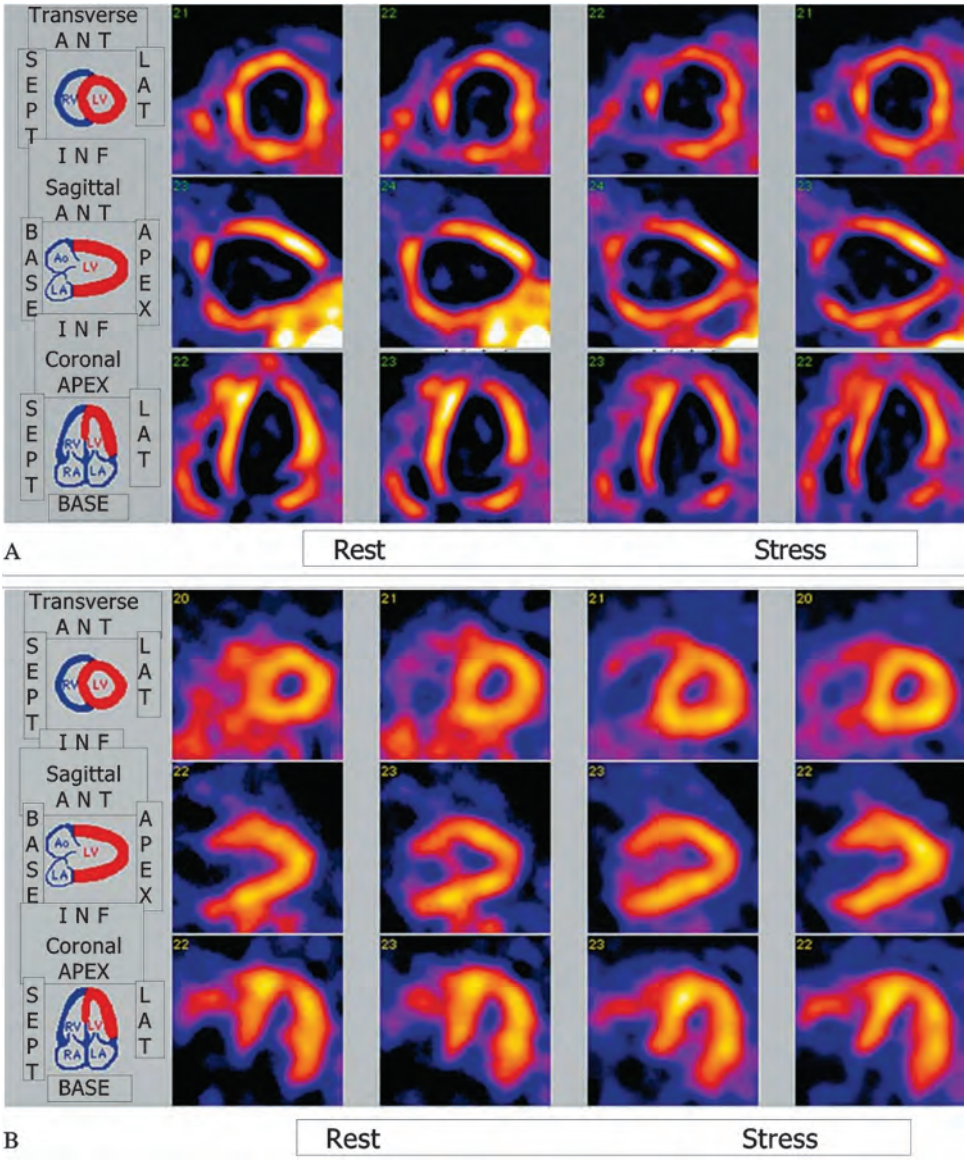

Figure 6. Patient with severe dilated cardiomyopathy. B: Same patient following successful cardiac transplantation (S.T. Treves. Pediatric Nuclear Medicine/PET, 3ed ed. Secaucus, NJ: Springer Verlag, 2007).

1.7. Right Ventricular Hypertrophy and Hypertension

In normal individuals, the right-ventricular myocardium has lower tracer uptake compared to the left ventricle, and therefore may not be clearly visible on myocardial perfusion SPECT. The right-ventricular wall can be seen in the normal individual

if the injection is made during or just after exercise. Increased 99mTc- MIBI and 201Tl uptake in the right ventricular myocardium at rest is seen in patients with right ventricular hypertrophy (Figure 7) [16, 17].

Visualization of the right ventricle on myocardial perfusion scintigraphy occurs in patients with congenital heart disease, such as tetralogy of Fallot (pre- and postoperatively), transposition of the great arteries (following Senning or Mustard's repair when the right ventricle is at systemic pressure), or after an ASO (with residual supravalvular pulmonary stenosis and secondary right ventricular hypertrophy) [11].

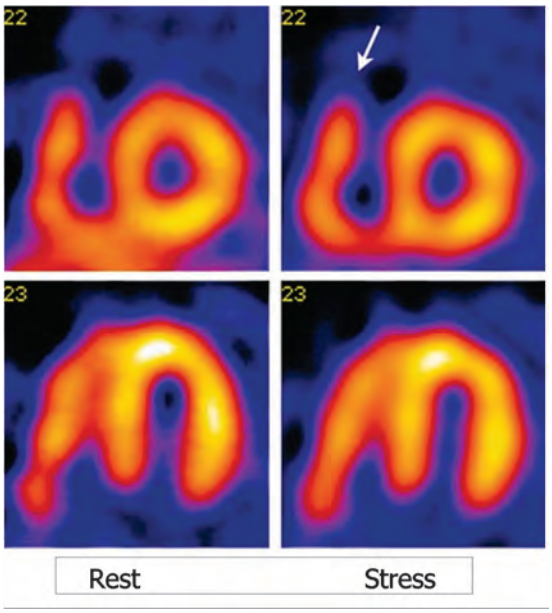

Figure 7. An 11-year-old girl with truncus arteriosus. The 99mTc-MIBI SPECT reveals increased right ventricular tracer uptake due to hypertrophy (arrow) (S.T. Treves. Pediatric Nuclear Medicine/PET, 3ed ed. Secaucus, NJ: Springer Verlag, 2007).

2. Radiopharmaceuticals for Myocardial Perfusion Single Photon Emission Computed Tomography

Myocardial SPECT in children can be carried out using one of the following agents:

– 99mTc-MIBI,
– 99mTc-tetrofosmin or
– thallium-201 (201TI)

Technetium-99m-MIBI is a cationic complex that accumulates in the myocardium according to regional myocardial perfusion. After intravenous administration, this agent is distributed throughout the body and concentrates in several organs including

the thyroid, myocardium, kidneys, and striated muscle. The agent clears rapidly from the blood with a fast initial component and with a half-time of 4.3 minutes. There is less, approximately 8%, of the administered tracer activity in blood by 5 minutes, and less than 1% of the tracer is protein-bound in the plasma. The major route of elimination of 99mTc-MIBI is the hepatobiliary system. The biologic half-lives of 99mTc-MIBI in myocardium and liver are 6 hours and 30 minutes, respectively. At rest, approximately 1.5% of the injected dose is taken up in the myocardium. Once 99mTc-MIBI is taken up by the myocardium, it remains fixed there and it shows no redistribution over time.

With 99mTc-MIBI, both resting and exercise stress evaluations can be performed; physiologic stress evaluations may be performed in patients old enough to cooperate with exercise testing (usually 7 years or older), and the pharmacologic stress can be used in all age groups [11].

Technetium-99m-Tetrofosmin is taken up in the myocardium to a maximum of 1.2% of the injected dose at 5 minutes and 1% at 2 hours, respectively. Activity in the blood, liver, and lungs is less than 5% of the administered activity at 10 minutes and less than 2% at 30 minutes. Tracer activity is eliminated in the urine (approximately 40%) and in the faeces (26%) within 48 hours [11].

Thallium-201 is considered a potassium analogue [18]. Clearance of potassium from the myocardium is faster than that of thallium, however after intravenous injection, the blood disappearance half-time of 201TI is less than 1 minute. The peak myocardial uptake, about 3% to 4% of the injected dose, occurs at approximately 10 minutes. At this time, the distribution of radiothallium in the heart appears to correlate with myocardial perfusion [19]. Thallium-201 is not fixed to the myocardium; it redistributes with time, exercise, drugs, and ischemia.

3. Positron Emission Tomography Perfusion Tracers

Rubidium-82 (82Rb), nitrogen-13 (13N), ammonia, and oxygen-15 (15O) water can be used to assess myocardial perfusion with PET [11].

Rubidium-82 is a generator-produced radionuclide with a half-life of 75 seconds. The parent radioisotope is strontium-82 with a physical half-life of 25.5 days. The generator eluant is injected intravenously into the patient as a continuous infusion. It is extracted rapidly in the myocardium depending on the flow. The short half-life of 82Rb permits studies to be performed in rapid succession [11].

Positron Emission Tomography Metabolic Tracers

Fluorine-18-fluoro-2-deoxyglucose (18F-FDG) is a glucose analogue. Fluorine-18 has a physical half-life of 111 minutes. Fluoro-2-deoxyglucose PET images regional myocardial glucose metabolism. Blood disappearance of 18F-FDG is rapid. Most of the activity leaves within 1 minute after intravenous injection, most of the remainder

leaves within 10 minutes, and a small fraction of the tracer remains in the blood pool in 90 minutes. Imaging can begin within a few minutes following tracer injection [11].

4. Assessment of Ventricular Function

Several nuclear medicine methods for the assessment of ventricular function in children are available. These include:

– electrocardiogram (ECG)-gated myocardial-perfusion SPECT,
– gated metabolic PET (18F-FDG),
– gated blood-pool scintigraphy,
– first-pass radionuclide angiography.

Radionuclide assessments of ventricular function include right and left ejection fractions, detection of wall-motion abnormalities, ventricular volume, cardiac output, and regurgitant fraction. Clinical applications of radionuclide studies to assess ventricular function have been applied to Kawasaki disease, anomalous origin of the coronary artery, cardiomyopathies, cardiac transplants, atrial and ventricular septal defects, cystic fibrosis, cardiac tumours, and certain congenital heart diseases, before and after catheter intervention or corrective surgery. Gated cardiac studies permit an evaluation of both global and regional ventricular function. Generally, no patient preparation is needed for this study, but patients under 3 years of age may require sedation in order to keep them still for the 20 to 30 minutes required for the recording [11].

4.1. Left-to-Right Shunts with first-pass radionuclide angiocardiography

First-pass radionuclide angiocardiography is a rapid, accurate, and non-invasive method that is useful in the diagnosis and measurement of left-to-right shunts in certain congenital lesions, including the following:

– Atrial septal defect
– Ventricular septal defect
– Truncus arteriosus
– Patent ductus arteriosus
– Complete atrioventricular canal
– Aortopulmonary collaterals

This method is useful for assessing the magnitude of the shunt in patients before and after repair.

Technetium-99m as pertechnetate is the most commonly used radiopharmaceutical for first-pass radionuclide angiocardiography. For the evaluation of left-to-right shunts, the technique of injection is of utmost importance in order to obtain a good-quality angiogram with high temporal resolution. Qualitative and quantitative analyses of angiocardiography are best done when the radiotracer is delivered as a single, small, rapid intravenous bolus injection, a point that cannot be overemphasized.

The majority of patients do not need sedation for this short procedure. If sedation is needed, it should be prescribed for each patient individually. Prior to positioning the patient under the gamma camera for the angiocardiogram, an intravenous needle or a short IV catheter is inserted.

The patient is placed supine on the imaging table. The gamma camera, equipped with a parallel-hole high-sensitivity collimator, is positioned anteriorly over the patient's chest. The field of view should extend from the suprasternal notch to just below the xiphoid and should cover both pulmonary fields. Radionuclide angiocardiography for the assessment of left-to-right shunting is recorded at two or four frames per second for 25 seconds on a 128 × 128 matrix [11].

In a normal radionuclide angiocardiogram, tracer is seen as it circulates sequentially through the superior vena cava, right atrium, right ventricle, pulmonary artery, lungs, left atrium, left ventricle, and aorta. The left ventricle and the aorta are clearly visualized with only minimal pulmonary activity. The relative sizes of the heart chambers can be appreciated on the angiocardiogram (Figure 8) [11].

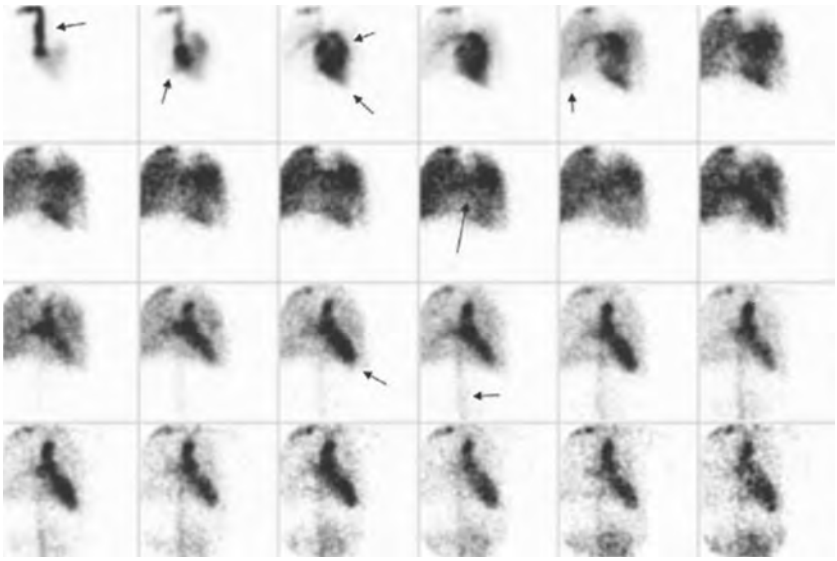

Figure 8. Normal radionuclide angiocardiogram. Tracer circulates in the superior vena cava (SVC), right atrium (RA), right ventricle (RV), pulmonary artery (PA), right lung (RL), left atrium (LA), left ventricle (LV), and aorta (Ao) (S.T. Treves. Pediatric Nuclear Medicine/PET, 3ed ed. Secaucus, NJ: Springer Verlag, 2007).

With left-to-right shunting, the radionuclide angiocardiogram reveals a persistence of tracer activity in the lungs caused by premature pulmonary recirculation of the tracer through the intracardiac shunt. The amount of persistent tracer activity in the lungs is directly related to the magnitude of shunt flow. In addition, in moderate to

severe left-to-right shunting, the left side of the heart and the aorta are not well visualized on the angiogram (Figure 9) [11].

These two radionuclide angiocardiographic features – persistent pulmonary tracer activity and poor visualization of the left side of the heart and aorta – are diagnostic for left-to-right shunting.

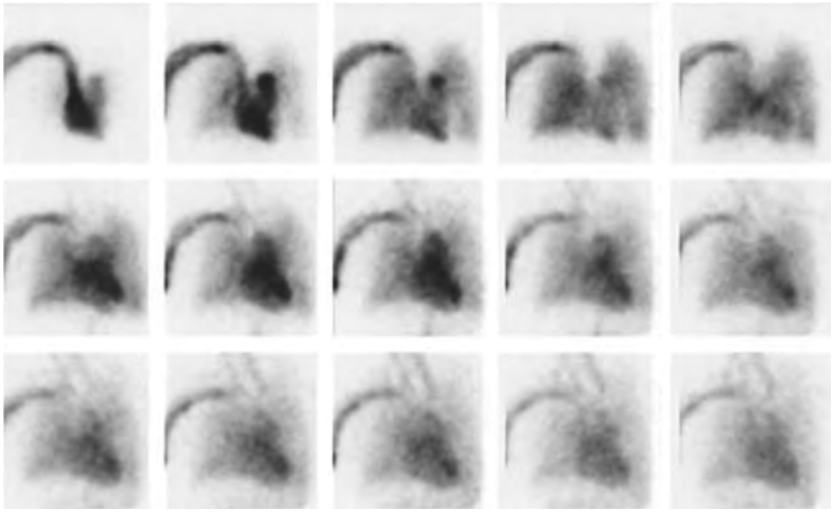

Figure 9. Left-to-right shunt. Radionuclide angiocardiogram from a patient with a moderate left-to-right shunt (S.T. Treves. Pediatric Nuclear Medicine/PET, 3ed ed. Secaucus, NJ: Springer Verlag, 2007).

4.2. Left-to-Right Shunts

With right-to-left shunting, the first-pass radionuclide angiogram reveals passage of the radiotracer within the superior (or inferior) vena cava, the right atrium, and the right ventricle. There is, depending on the level of the shunt, rapid appearance of the tracer within the left atrium or the left ventricle and the aorta (or both), which on the angiogram appears to occur at the same time or before the tracer reaches the lungs. For example, with tricuspid atresia, the tracer is seen to circulate from the right atrium into the left ventricle via the left atrium, presenting a rather unique angiographic pattern. Some examples of congenital lesions where radionuclide angiocardiography may be used to detect and quantify right-to-left shunts are as follows [11]:

– Tetralogy of Fallot
– Tricuspid atresia
– Pulmonary atresia/intact ventricular septum
– Tetralogy of Fallot with pulmonary atresia

Two approaches to the detection and quantitation of right-to-left shunts have been taken. The angiocardiographic technique is the same as that described for left-to-right shunting except that the patient (with levocardia) should be imaged in the left

anterior oblique projection to obtain maximum separation between the right and left ventricles.

Another technique uses large-molecularweight radioactive particles (99mTc-MAA). The major assumption in this method is that the particles are completely extracted from the circulation in one pass through either the pulmonary or the systemic capillary beds. This condition is largely met for particles larger than 10μm in diameter. It is also assumed that the particles are mixed uniformly in the blood, that the particles themselves do not affect the blood flow, and that the particles traverse the system in the same manner as the blood. After intravenous administration of radioactive particles to a patient with a right-to-left shunt, the ratio of particles that enter the pulmonary and systemic circulations equals the pulmonary blood flow/systemic blood flow ratio. The activity in the whole body is measured and compared with that in the lungs. Assessment of right-to-left shunting with 99mTc-MAA may be particularly useful in cyanotic patients with congenital heart disease to differentiate intrapulmonary versus intracardiac or extracardiac shunting.

Right-to-left shunting can also be detected by angiocardiography with an inert gas. An inert gas is almost completely removed from the blood in one transit through the lungs. The appearance of systemic activity after intravenous injection of an inert gas (dissolved in saline) indicates a right-to-left shunt. Prior to high-resolution echocardiography and cine-MRI, some investigators used both an inert gas and a nondiffusable indicator to define the nature of the cardiac defect, especially in complicated cases [11].

References

1. Blumgart HL, Yens OC. Studies on the velocity of blood flow. I. The method utilized. J Clin Invest 1927;4:1–13.
2. Prinzmetal M, Corday E, Spritzler RJ, Flieg W. Radiocardiography and its clinical applications. JAMA 1949;149:617–22.
3. Kato H, Sugimura T, Akagi T, et al. Long-term consequences of Kawasaki disease. A 10- to 21-year follow-up study of 594 patients. Circulation 1996;94(6):1379–85.
4. Dajani AS, Taubert KA, Gerber MA, et al. Diagnosis and therapy of Kawasaki disease in children. Circulation 1993;87(5):1776–80.
5. Nienaber CA, Spielmann RP, Hausdorf G. Dipyridamole-thallium-201 tomography docu menting improved myocardial perfusion with therapy in Kawasaki disease. Am Heart J 1988;116(6 pt 1):1575–9.
6. Fyler DC. Report of the New England Regional Infant Cardiac Program. Pediatrics 1980;65(2 pt 2):377.
7. Mayer JE Jr, Jonas RA, Castaneda AR. Arterial switch operation for transposition of the great arteries with intact ventricular septum. J Cardiovasc Surg 1986;1(2):97–104.
8. Tsuda E, Imakita M, Yagihara T, et al. Late death after arterial switch operation for transposition of the great arteries. Am Heart J 1992;124(6):1551–7.
9. Hunt SA. Complications of heart transplantation. J Heart Transplant 1983;3:70–4.

10. Pahl E, Naftel DC,Kuhn M, et al.The incidence and impact of transplant coronary artery disease in pediatric recipients: a 9 year multiinstitutional study abstract. Circulation 2002; 106:II-396.
11. S.T. Treves. Pediatric Nuclear Medicine/PET, 3ed ed. Secaucus, NJ: Springer Verlag, 2007.
12. Rein AJ, Colan SD, Parness IA, Sanders SP. Regional and global left ventricular function in infants with anomalous origin of the left coronary artery from the pulmonary trunk: preoperative and postoperative assessment. Circulation 1987;75(1):115–23.
13. Sauer U, Stern H, Meisner H, Buhlmeyer K, Sebening F. Risk factors for perioperative mortality in children with anomalous origin of the left coronary artery from the pulmonary artery. J Thorac Cardiovasc Surg 1992;104(3):696–705.
14. Hurwitz RA, Caldwell RL, Girod DA, Brown J, King H. Clinical and hemodynamic course of infants and children with anomalous left coronary artery. Am Heart J 1989;118(6):1176–81.
15. Kocis KC. Chest pain in pediatrics. Pediatr Clin North Am 1999;46(2):189–203.
16. Kondo M. Thallium-201 myocardial imaging in patients with various heart diseases (author's transl). Nippon Igaku Hoshasen Gakkai Zasshi 1979;39(9):942–54.
17. Kondo M,Kubo A,Yamazaki H, et al.Thallium-201 myocardial imaging for evaluation of right ventricular overloading. J Nucl Med 1978;19:1197–203.
18. Lebowitz E, Greene MW, Fairchild R, et al. Thallium-201 for medical use. I. J Nucl Med 1975;16(2):151–5.
19. Kawana N, Krizeh H, Porter J, et al. Use of Tl-201 as a potassium analog in scanning abstract. J Nucl Med 1970;11:333.